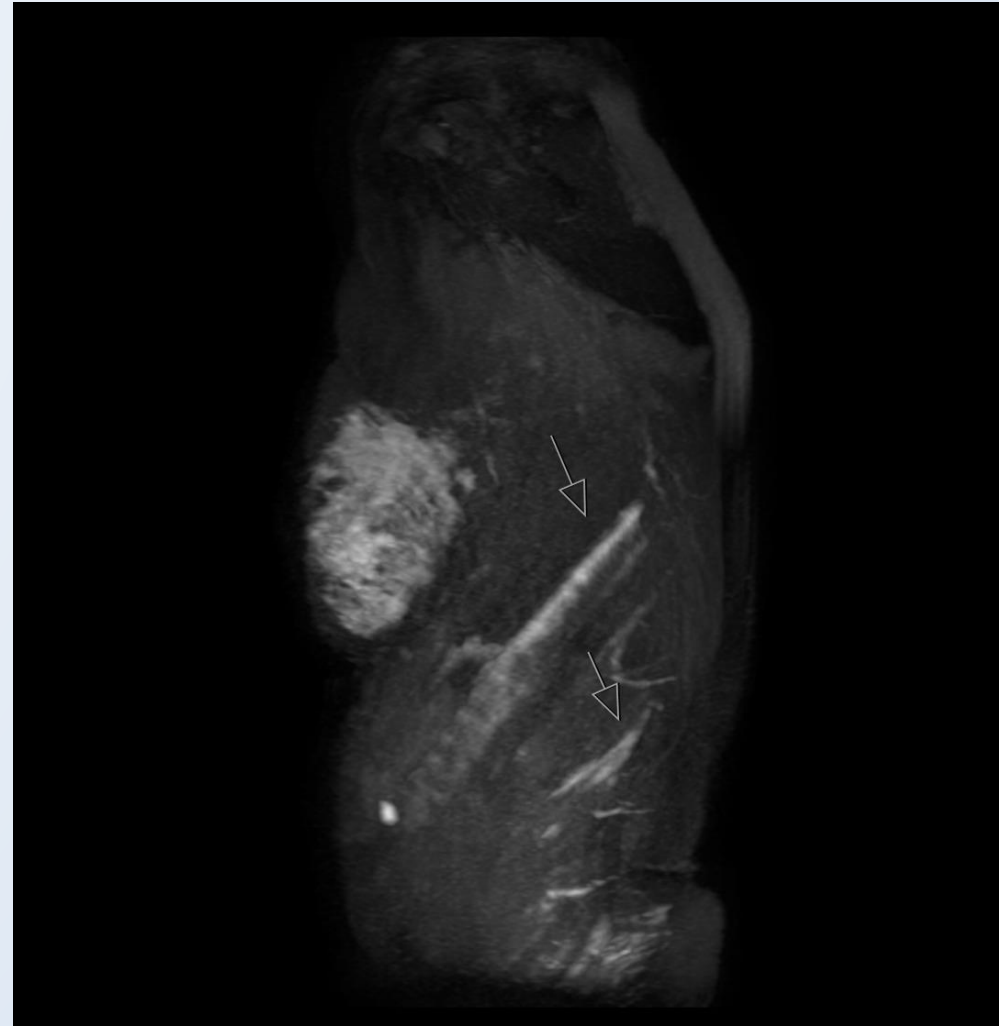
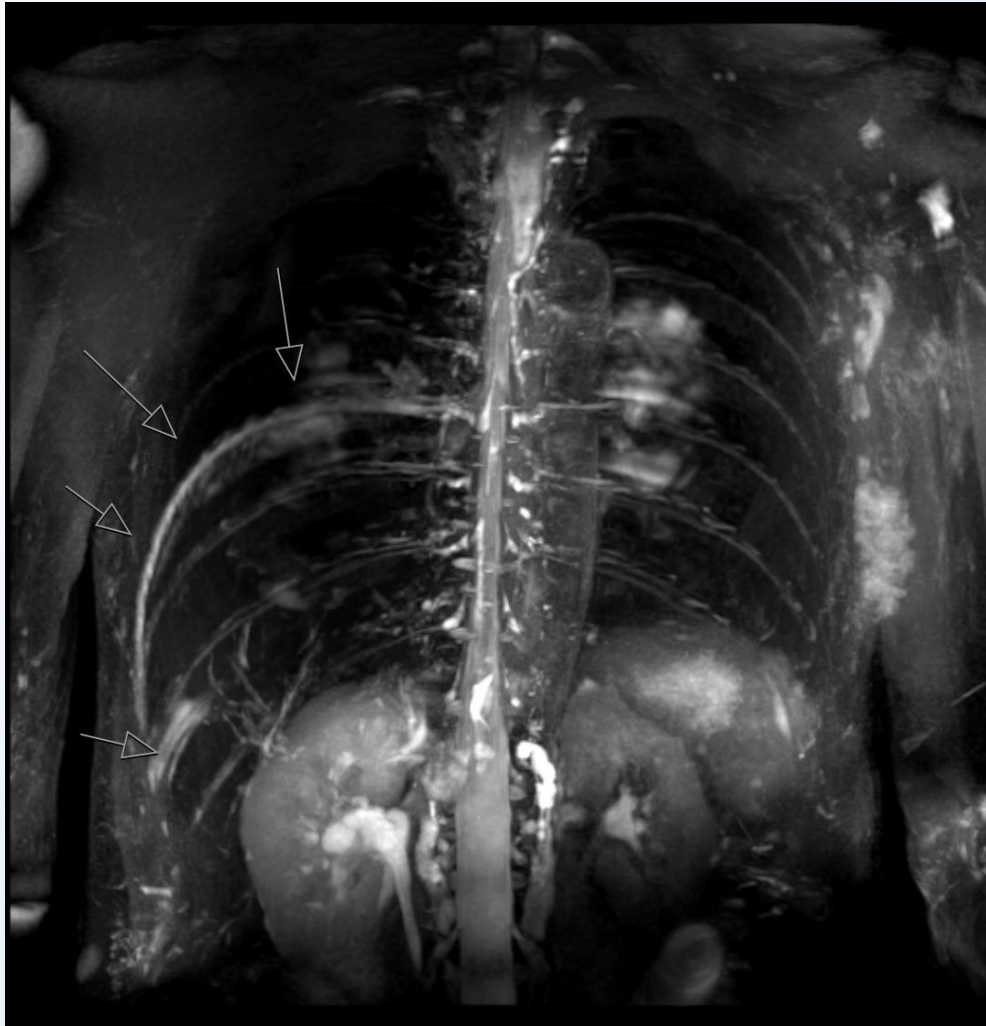


Case of the Week

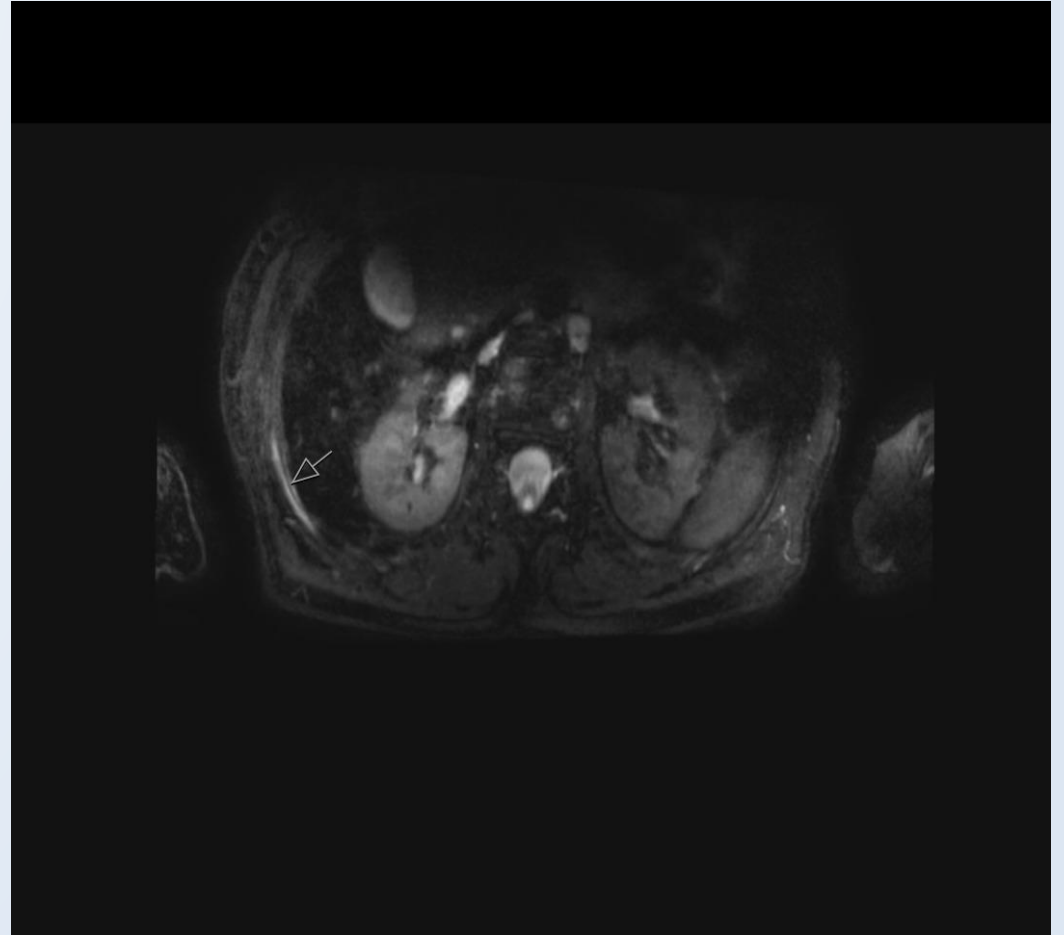
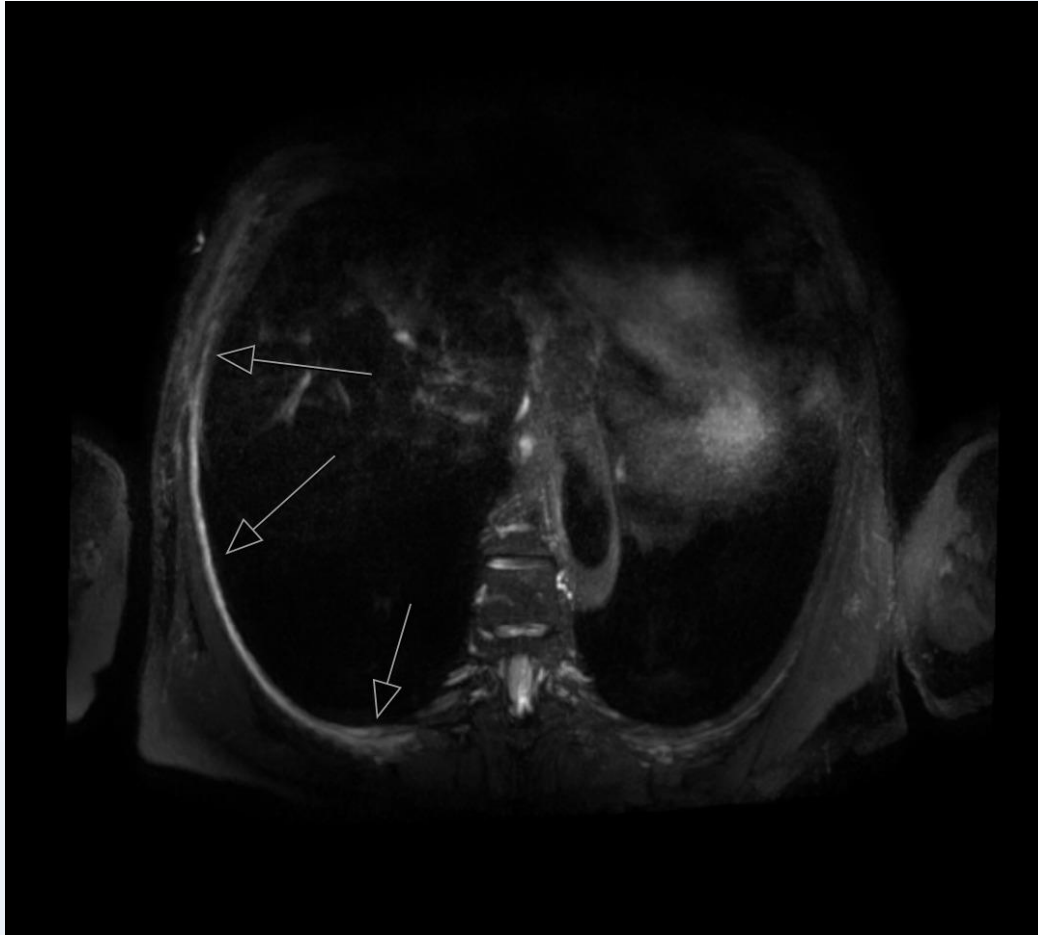
- History
 - 80y/o female, atraumatic onset of severe right sided rib pain (T9-10ish) onset about 7 weeks ago
 - Burning pain with allodynia, unable to tolerate bra.
 - Hx of shingles to the left V1 distribution.

MR Neurography of the Chest Wall



Findings: Diffuse right T8 and segmental right T10 intercostal neuropathy.

MR Neurography of the Chest Wall



Findings: Diffuse right T8 and segmental right T10 intercostal neuropathy.

ZOSTER-RELATED INTERCOSTAL NEUROPATHY

Suggested Reading

- <https://doi.org/10.1259/bjr.20200603>



Volume 94, Issue 1122
1 June 2021

JOURNAL ARTICLE

Role of magnetic resonance neurography in intercostal neuralgia; diagnostic utility and efficacy

FREE

Majid Chalian, MD, Diana Hoang, BS, Shai Rozen, MD, Avneesh Chhabra, MD

British Journal of Radiology, Volume 94, Issue 1122, 1 June 2021, 20200603,
<https://doi.org/10.1259/bjr.20200603>

Published: 07 May 2021 **Article history** ▼

Atul K. Taneja, MD, PhD

Assistant Professor, Musculoskeletal Radiology

UT Southwestern Medical Center, Dallas, TX

E-mail: atul.taneja@utsouthwestern.edu

UT Southwestern

Medical Center

Radiology



@atultanejamd



@dr.taneja



@drtaneja