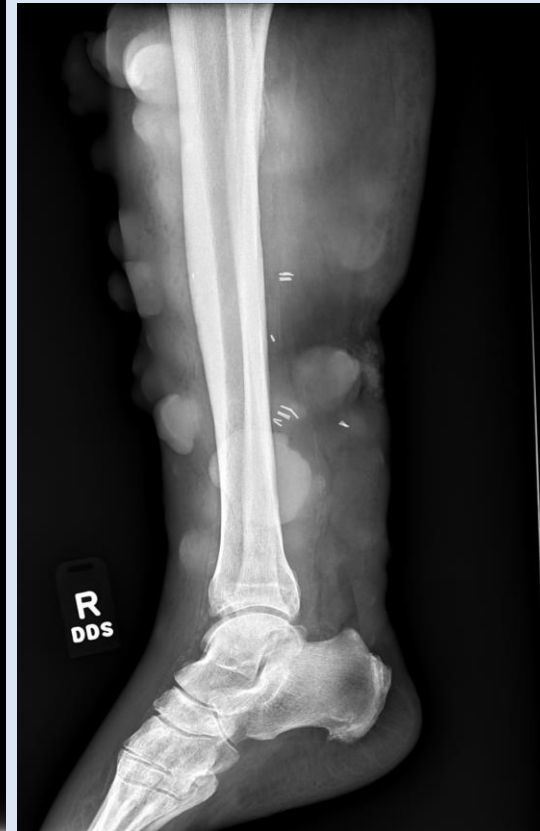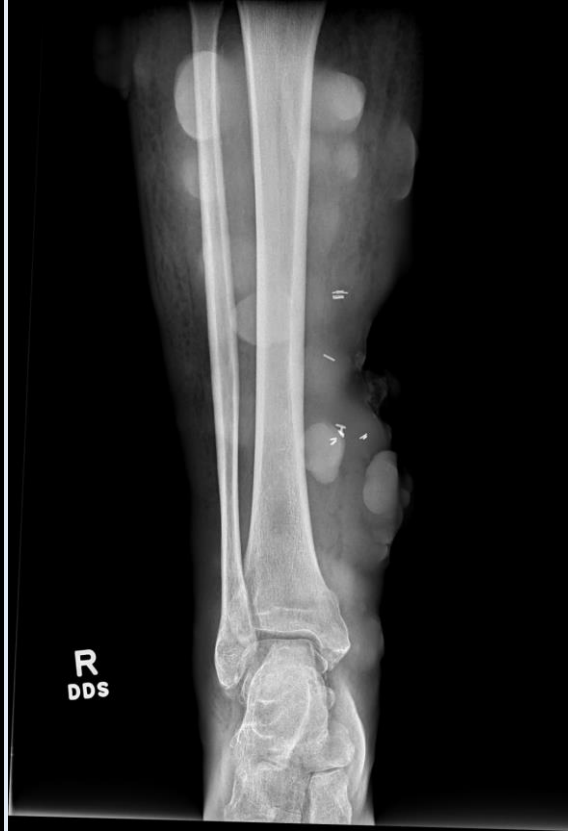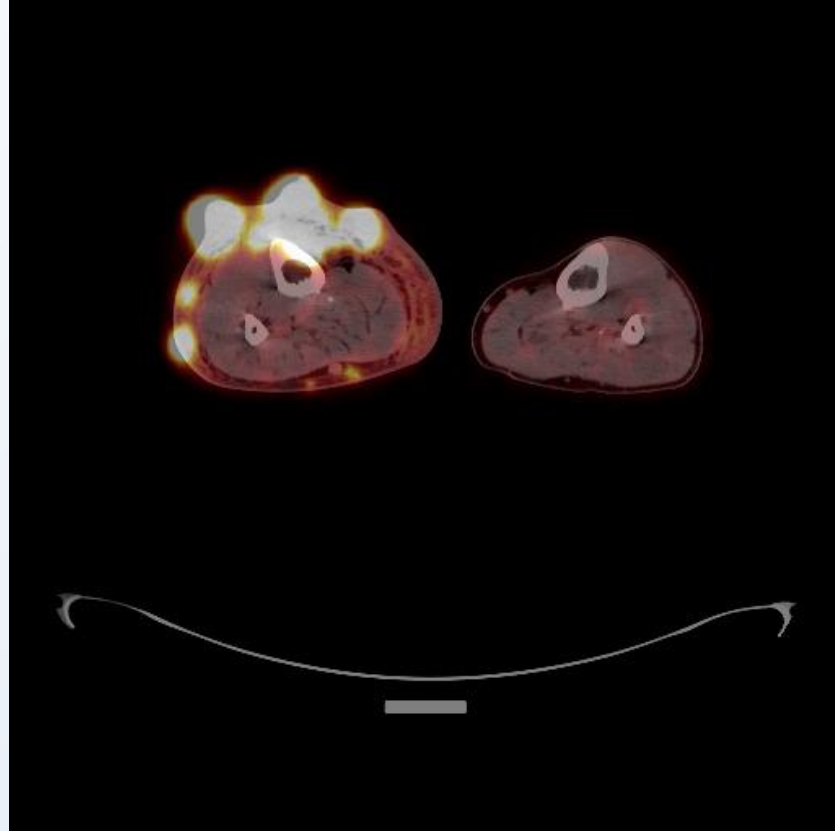


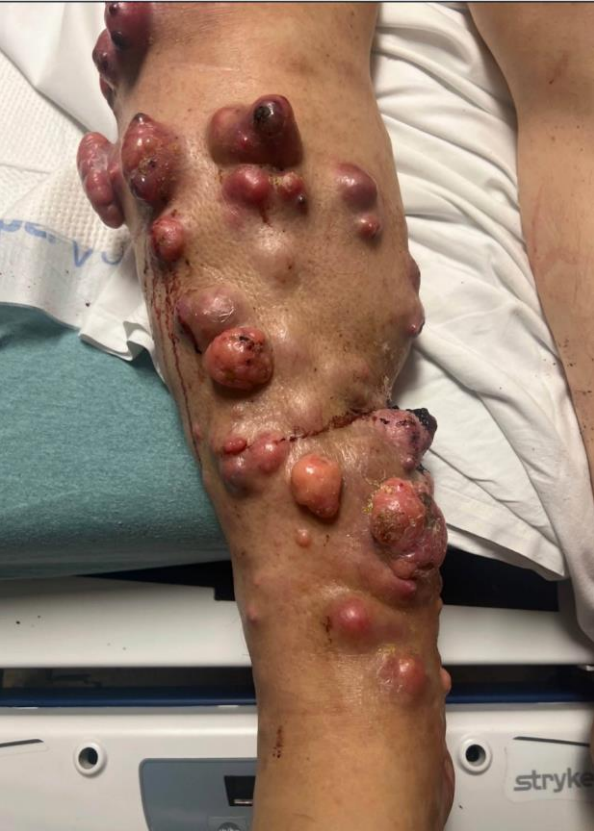
Case 1 – Metastatic Melanoma



Case 1 – Metastatic Melanoma

- Suggested Reading - <https://doi.org/10.1016/j.crad.2010.10.014>

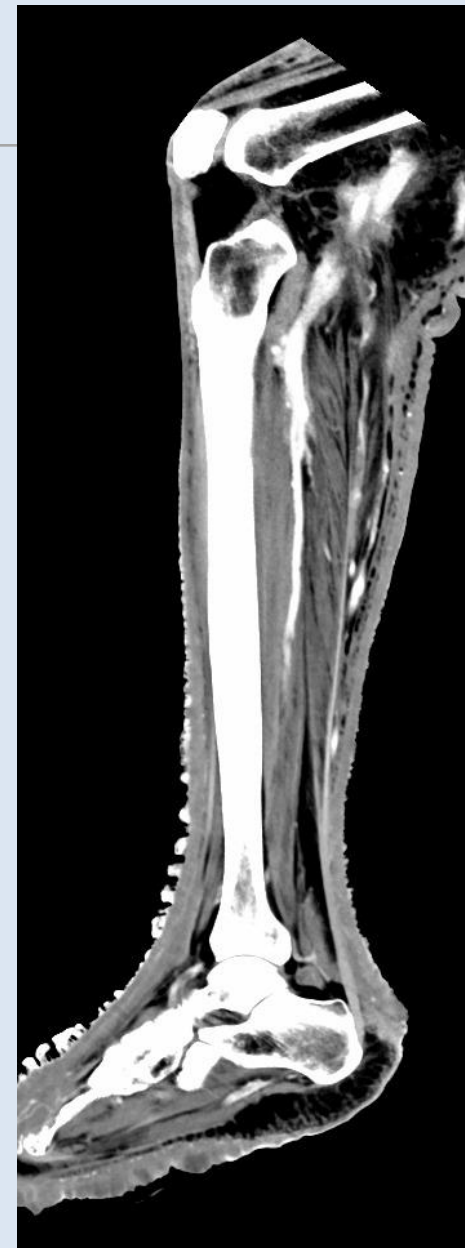
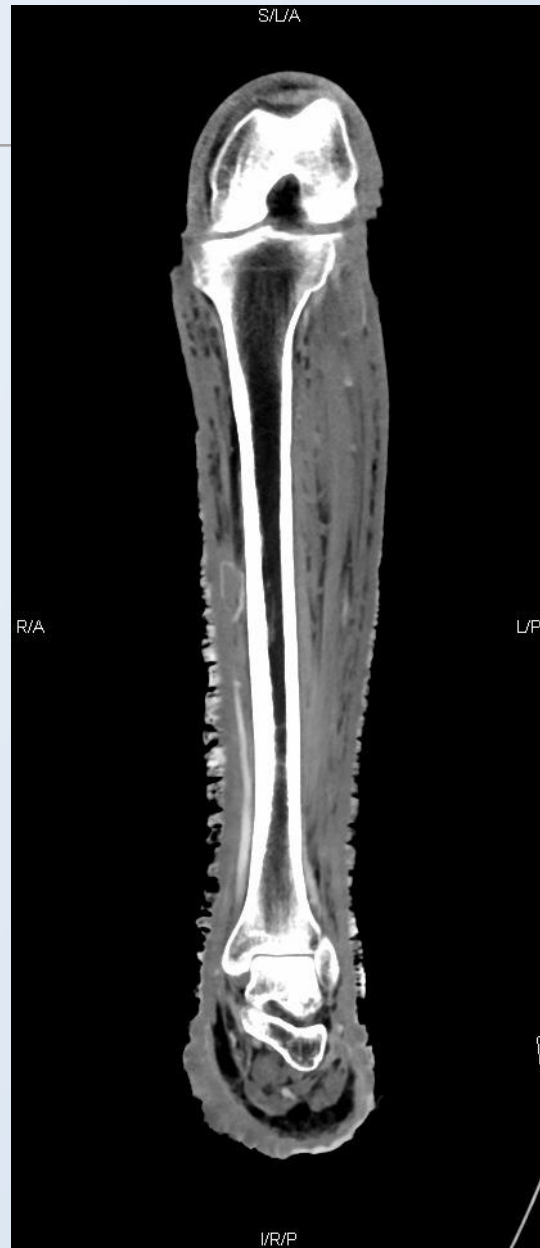
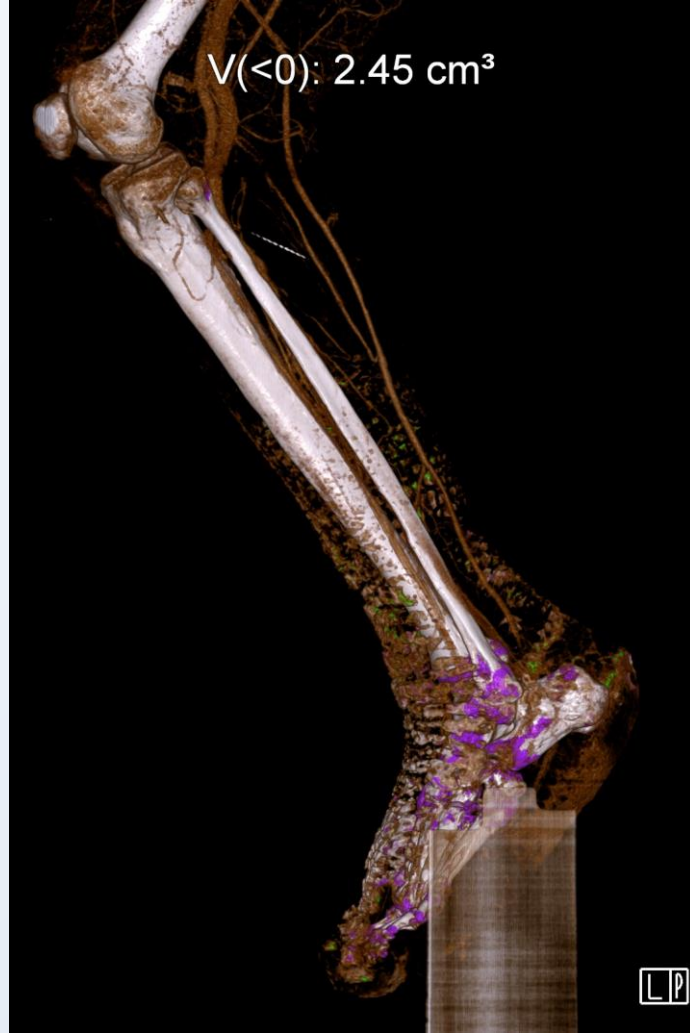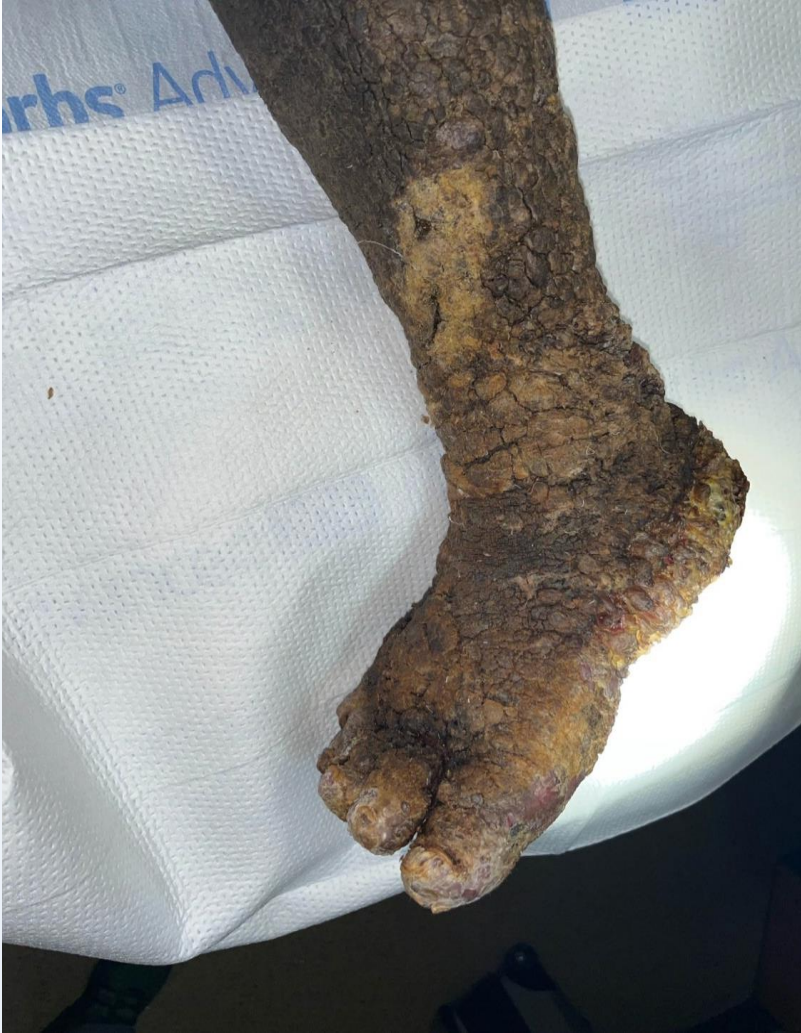Review

Multimethod imaging, staging, and spectrum of manifestations of metastatic melanoma

M. Patnana^a, Y. Bronstein^a, J. Szklaruk^a, D.G. Bedi^a, W.-J. Hwu^b, J.E. Gershenwald^c, V.G. Prieto^d, C.S. Ng^{a,*}

Case 2 – Kaposi Sarcoma



Case 2 – Kaposi Sarcoma

- Suggested Reading - <https://pubs.rsna.org/radiographics/doi/10.1148/rg.264055129>

EDUCATION EXHIBIT 1169

RadioGraphics

Imaging Manifestations of Kaposi Sarcoma¹

*Carlos S. Restrepo, MD • Santiago Martinez, MD² • Julio A. Lemos, MD
Jorge A. Carrillo, MD • Diego F. Lemos, MD • Paulina Ojeda, MD
Prakash Koshy, MD*

ONLINE-ONLY CME
See www.rsna.org/education/lrg_cme.html.

Kaposi sarcoma (KS) is a low-grade vascular tumor that typically

Atul K. Taneja, MD, PhD

Assistant Professor, Musculoskeletal Radiology

UT Southwestern Medical Center, Dallas, TX

E-mail: atul.taneja@utsouthwestern.edu

UT Southwestern

Medical Center

Radiology



@atultanejamd



@dr.taneja



@drtaneja