

Subcutaneous sarcoidosis with thoracic involvement: A very rare presentation of the disease

Inès Zendah^{a,*}, Talel Badri^b, Emna.Ben Salah^a, Habib Ghedira^a

^a Abderrahmane Mami Hospital of Thoracic diseases. Department I, 2080, Ariana, Tunis, Tunisia

^b Habib Thameur Hospital, Department of Dermatology, 1008, Tunis, Tunisia

ABSTRACT

Subcutaneous sarcoidosis is a very rare manifestation of sarcoidosis and its association with parenchymal lung involvement is rarer. We report the twentieth case in the literature published on PubMed. It is the case of a 61-year-old caucasian, non-smoker lady, who presented to a dermatology department with a 7-month history of asthenia, anorexia, weight loss, fever, exertion dyspnea, dry cough, arthralgia of the large joints and non-tender multiple subcutaneous tumefactions. Biopsy of the nodules established the diagnosis of subcutaneous sarcoidosis. Bronchioloalveolar lavage revealed alveolitis with lymphocyte predominance and the CD4/CD8 ratio was 8.5. Chest computed tomography scan revealed peribronchovascular thickening, micronodules of lymphatic distribution and mediastinal lymphadenopathies which were bilateral, asymmetric, and non-compressive. We therefore concluded the involvement of the lung and the mediastinal lymph nodes. The angiotensin-converting enzyme level was high. The patient was successfully treated with prednisone at the dose of 1mg/kg/day.

1. Introduction

Sarcoidosis is a systemic disease of unknown etiology characterized by the presence of granulomas without caseous necrosis in the involved organs [1]. The lung and the mediastinal lymph nodes are the most frequently concerned sites [2]. Skin location is found in 10–30% of the cases [3]. Subcutaneous sarcoidosis is rare. The association of a subcutaneous and a lung parenchymal sarcoidosis is rarer. We add another case to the literature.

1.1. Case report

A 61-year-old Caucasian, non-smoker lady, with a type II diabetes mellitus, and without familial past medical history, was seen in dermatology because of a 7-month history of asthenia, anorexia, weight loss, fever, exertion dyspnea, dry cough, arthralgia of the large joints and non-tender, multiple subcutaneous tumefactions. On examination, the patient presented inspiratory crackles in the basis of the two pulmonary chest fields and multiple deep subcutaneous, firm, non-tender, non-erythematous and mobile nodules, of 1–5 cm in size (Fig. 1). The lesions involved the arms, the elbows, the wrists, the hands and the posterior face of the right thigh and the legs. Biopsy of the nodules revealed multiple confluent epithelioid and giganto-cellular granulomas in the adipose subcutaneous tissue surrounded by a discrete cuff of lymphocytes without any necrosis. Giant Langhans cells contained small

asteroid or calcified bodies (Fig. 2). Staining for acid-fast bacilli (AFB) was negative. The diagnosis of subcutaneous sarcoidosis was made. Chest X-ray film revealed bilateral hilar opacities and micronodules in the lower pulmonary fields. Thoracic computed tomography (CT) scan showed proximal peribronchovascular and septal thickening associated to ill-defined nodules. The latter were peribronchovascular, centrolobular and perilobular and were predominating in the culmen and the left Fowler segment. Mediastinal study showed large hilar and interbronchial non-compressive and asymmetric lymphadenopathies. There were also bilateral axillar lymphadenopathies and a slight pericardic effusion (Figs. 3 and 4). Flexible bronchial fibroscopy was realized to permit bronchioloalveolar lavage (BAL). The latter was highly cellular with lymphocyte predominance with a CD4/CD8 ratio of 8.5 which is consistent with the diagnosis of sarcoidosis. The angiotensin-converting enzyme level was: 78 U/L (Normal range: 12–68U/L).

Therefore, the diagnosis of subcutaneous sarcoidosis associated with mediastinal lymph nodes and parenchymal lung involvement was made. The patient was started on 1mg/kg/day prednisone given her symptoms which resolved all the symptoms and normalized the radiograph.

2. Discussion

We report a case of subcutaneous, mediastinal lymph nodes and lung sarcoidosis. Cutaneous manifestations of sarcoidosis are numerous. They are subdivided into specific lesions characterized on pathologic

* Corresponding author.

E-mail address: dr.zendah@gmail.com (I. Zendah).

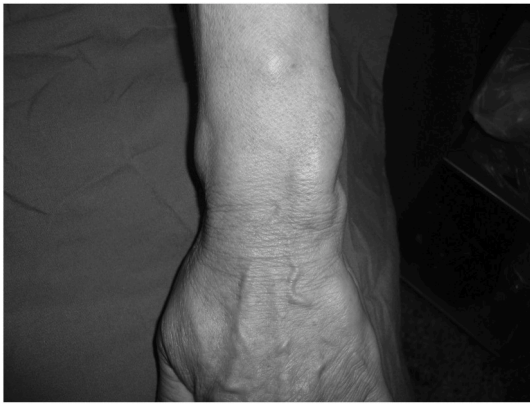

Fig. 1. (Obtained with permission): Deep subcutaneous, non-erythematous and mobile nodules of the arm, the wrist and the hand (arrows).

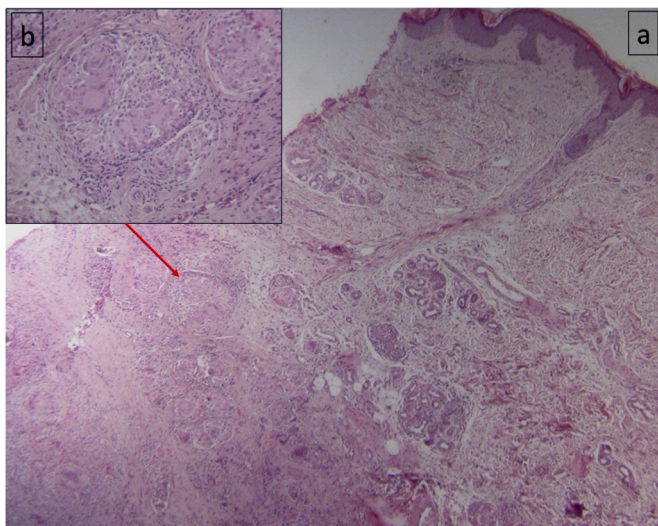


Fig. 2. Biopsy of a subcutaneous nodule of the arm: multiple confluent epithelioid and giant-cell granulomas in the adipose subcutaneous tissue surrounded by a discrete cuff of lymphocytes without any necrosis (arrow).
a/H&E staining. Magnification: x40.
b/H&E staining. Magnification: x200.

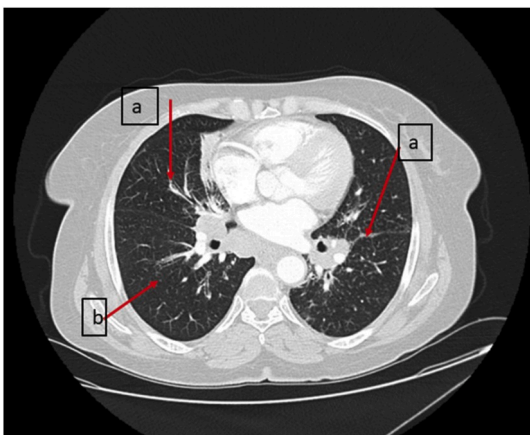


Fig. 3. Thoracic CT scan (parenchymal window): proximal peribronchovascular thickening associated to peribronchovascular, centrilobular and perilobular nodules (arrows).

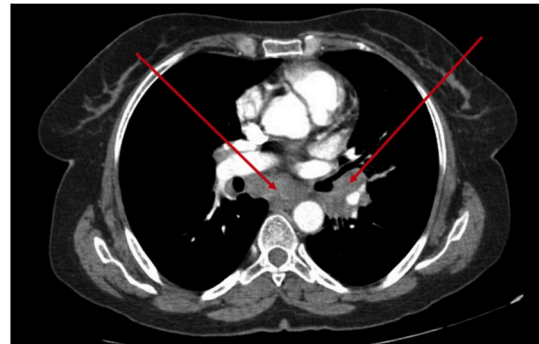


Fig. 4. Thoracic CT scan (mediastinal window): mediastinal bilateral, asymmetric, non-compressive lymphadenopathies.

examination by the presence of granulomas, and into non-specific lesions mainly represented by erythema nodosum [3]. Subcutaneous sarcoidosis was first described in 1906. It is a rare specific form of the disease which frequency does not exceed 1–6% [4]. It affects mainly females in the fourth decade in contrast to our patient, which was a 61-year-old woman. Rarely it affects older patients. Most patients, such is the case of our patient, are white [7]. The lesions are most of the time located on the extremities and the trunk [5,6]. In our patient, the trunk was, however, spared. In subcutaneous sarcoidosis, the lesions are typically small, firm, mobile, non-erythematous and non-tender or slightly tender [5]. All these findings were present in our patient. The diagnosis was further confirmed by biopsy which showed signs fulfilling Vainsencher and Winkelmann criteria that are the presence of epithelioid granulomas with a slight lymphocytic inflammation, developing mainly in the adipose tissue with a slight involvement of the hypodermis [7]. Ultrasound and magnetic resonance imaging, two non invasive exams show abnormalities consistent of subcutaneous sarcoidosis [8,9]. They reveal mass with hyperechoic areas interspersed with hypoechoic areas for the former; and well-defined mass with heterogeneous intermediate signal intensity on T1- and proton density-weighted images with heterogeneous enhancement after the intravenous administration of gadolinium for the latter. However, the cutaneous biopsy remains mandatory for the diagnosis.

Subcutaneous sarcoidosis is the only specific cutaneous lesion frequently associated to the involvement of another organ but its association to lung involvement is rare [10]. Bilateral hilar lymphadenopathies are the most commonly associated lesions reaching 94% cases in some series [7,11]. To our knowledge, no more than 54 cases of subcutaneous sarcoidosis were published on PubMed, among whom only 19 had lung parenchymal involvement [7]. To our knowledge, we report the twentieth case of the literature. Our patient presented two rare findings at the same time: a subcutaneous sarcoidosis and its association with lung involvement.

Subcutaneous nodules can be seen at any time of the course of a sarcoidosis but, as in our patient, it is most of the time the first manifestation of the disease. Once diagnosed, further investigations, to look for other involved organs, should be achieved. The ACCESS (A Case Control Etiologic Study of Sarcoidosis) study [12], demonstrated that cutaneous involvement of sarcoidosis allows a more rapid diagnosis of sarcoidosis than does the pulmonary one. In the cases reported in the literature, almost one third of the patients presented autoimmune diseases at time of diagnosis which is not the case of our patient [7].

There is currently no consensual treatment for subcutaneous sarcoidosis with lung involvement. Systemic corticotherapy is most of the time indicated because of extra cutaneous involvement or because the lung involvement is symptomatic or severe. In our patient it was the dyspnea that motivated this treatment. For the skin, only severe cutaneous lesions (such as lupus pernio) indicate systemic corticotherapy [5].

The prognosis of subcutaneous sarcoidosis is better when it appears on the acute form than when it is chronic. Most of the reported cases of the association of the subcutaneous and lung locations of the disease appeared with an acute onset and had a favorable outcome when treated by corticosteroids [7,12]. That was also the case of our patient.

Declaration of competing interest

The authors report non conflict of interest for this article.

Appendix A. Supplementary data

Supplementary data to this article can be found online at <https://doi.org/10.1016/j.rmcr.2020.101041>.

References

- [1] C. Ulrich, G. Josune, P. Robert, et al., Systemic evaluation of a potential cutaneous sarcoidosis patient, *Clin. Dermatol.* 25 (2007) 303–311.
- [2] L.E. Siltzbach, D.G. James, E. Neville, Course and prognosis of sarcoidosis around the world, *Am. J. Med.* 57 (1974) 847–852.
- [3] K. Bernd, Cutaneous manifestation of sarcoidosis with severe osseous destruction of the midface, *J. Commun. Media Stud.* 22 (1994) 163–166.
- [4] J.P. Callen, Relationship of cutaneous sarcoidosis to systemic disease, *Clin. Dermatol.* 4 (1986) 46–53.
- [5] R.P. Baughman, E.E. Lower, R.M. Du Bois, Sarcoidosis, *Lancet* 361 (2003) 1111–1118.
- [6] M.L. Elgart, Cutaneous sarcoidosis: definitions and types of lesions, *Clin. Dermatol.* 4 (1986) 35–45.
- [7] A. Iftikhar, R. Sujata, M.D. Harshad, et al., Subcutaneous sarcoidosis: is it a specific subset of cutaneous sarcoidosis frequently associated with systemic disease, *Am. Acad. Dermatol.* 10 (2005), 001.
- [8] U.T. Malik, F. Aslam, Ultrasound for the rheumatologist –subcutaneous sarcoidosis, *Acta. Reumatol. Port* 41 (2016) 376–377.
- [9] T. Ruangchaijatuporn, E.Y. Chang, C.B. Chung, Solitary subcutaneous sarcoidosis with massive chronic prepatellar bursal involvement, *Skeletal Radiol.* 45 (2016) 1741–1745.
- [10] J. Mana, J. Marcoval, J. Graells, et al., Cutaneous involvement in sarcoidosis. Relationship to systemic disease, *Arch. Dermatol.* 133 (1997) 882–888.
- [11] M. Kerner, M. Ziv, F. Abu-Raya, et al., Subcutaneous sarcoidosis with neurological involvement: an unusual combination, *Isr. Med. Assoc. J.* 10 (2008) 428–430.
- [12] M. Richard, M. Marchell, A. Judson, Chronic cutaneous lesions of sarcoidosis, *Clin. Dermatol.* 25 (2007) 295–302.