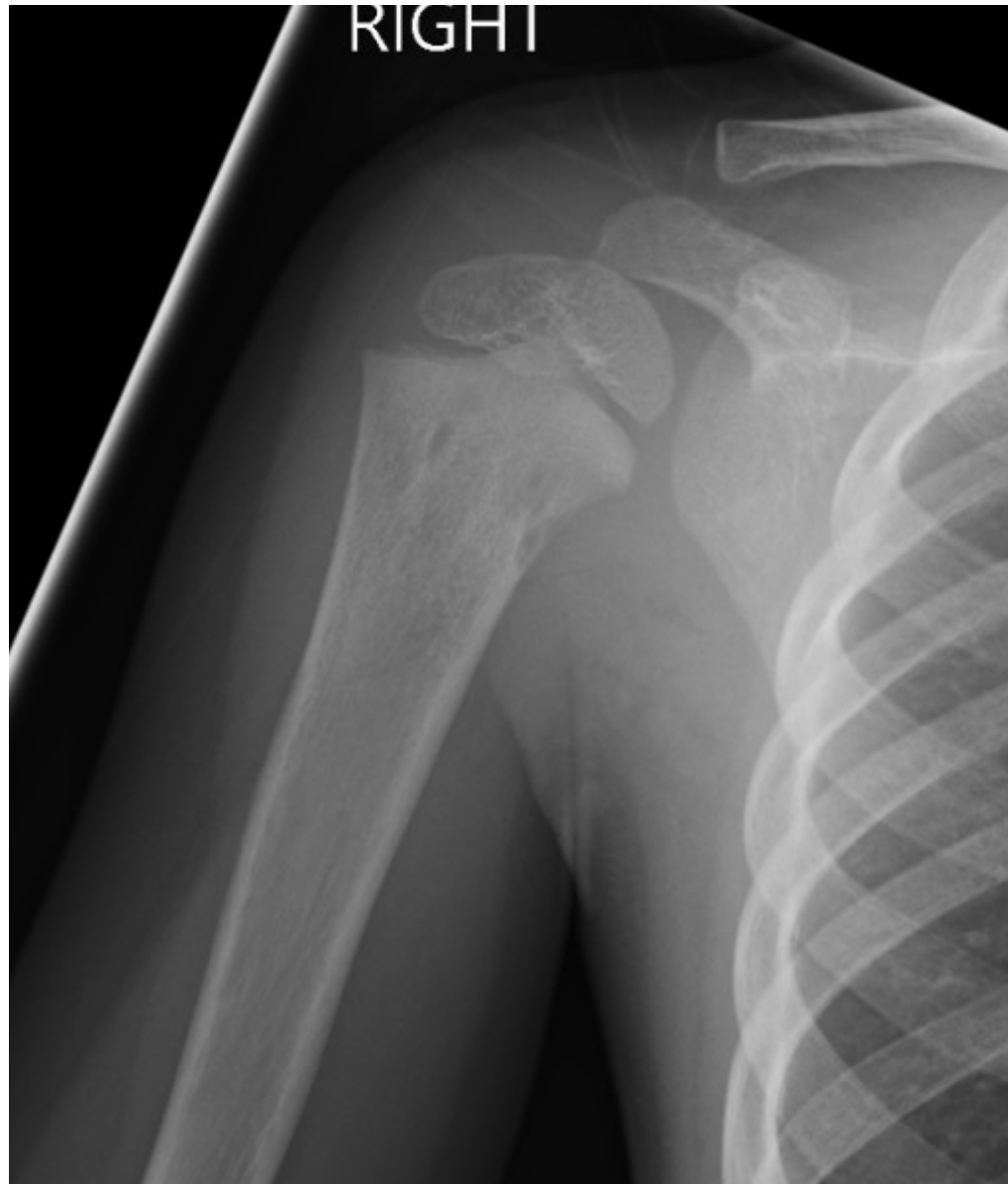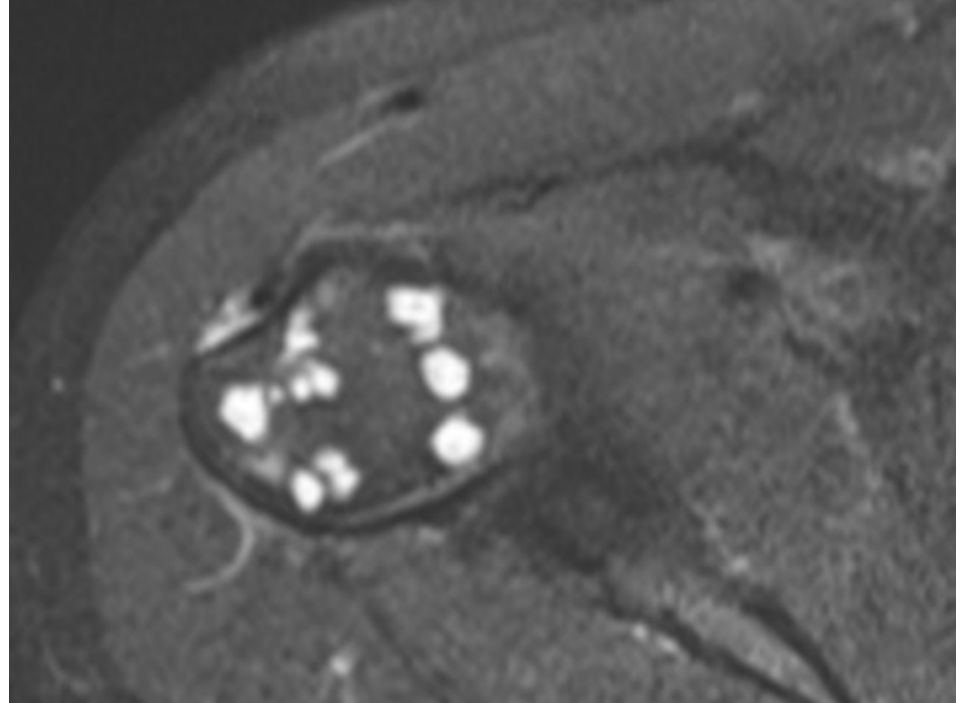
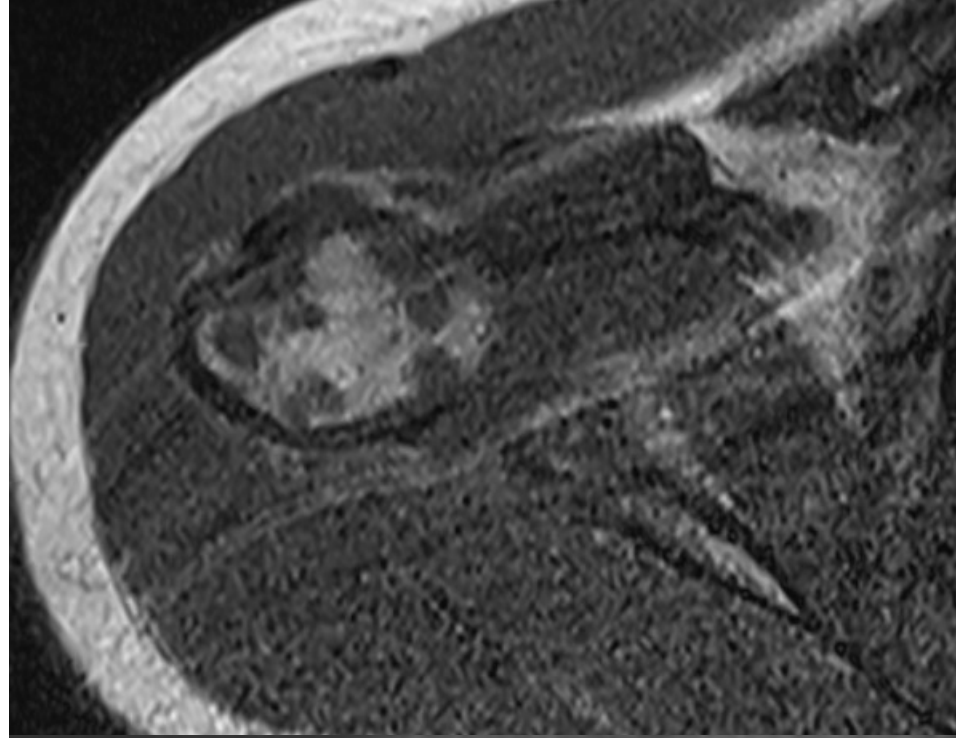
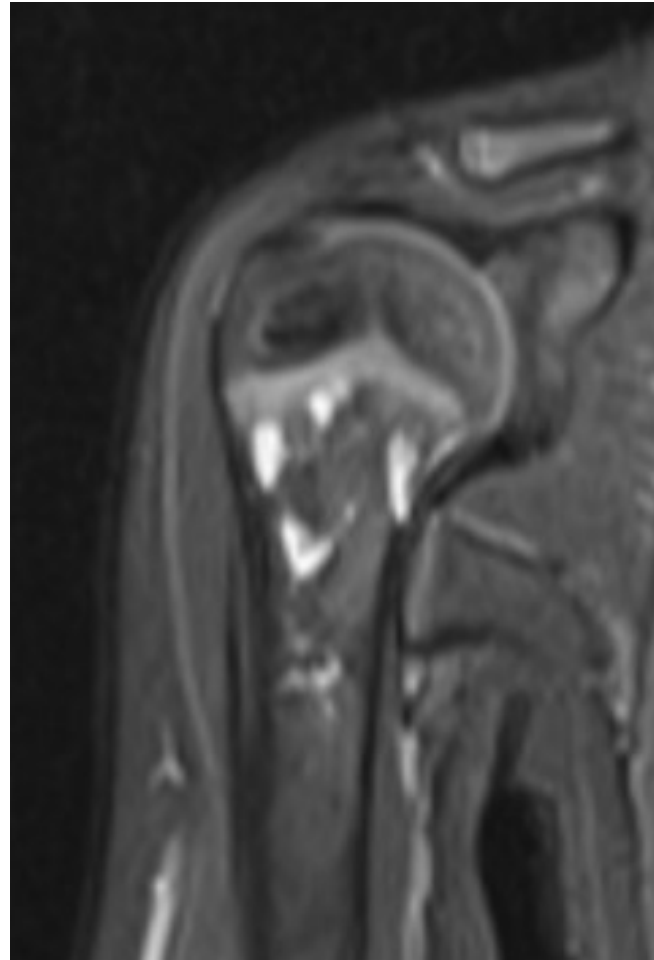
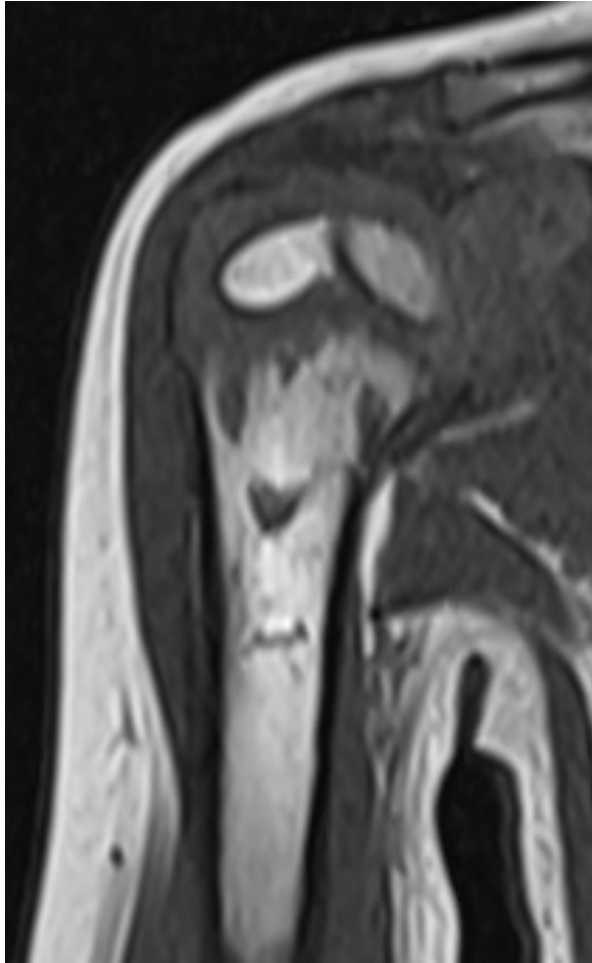


- 2yr old male
- Incidental humeral lesion





?

- I sense this is one of those excellent examples of whatever it is
- ?Fibrous dysplasia
- ?Cartilage rests