

Medial Patellofemoral Muscle: Report of a Rare Variant

Músculo Patelofemoral Medial: Reporte de una Rara Variante

Ignacio Beddings Moreno^{*}; Álvaro Burdiles Orellana^{*} & Oscar Contreras Olea^{*}

BEDDINGS, M. I.; BURDILES, O. A. & CONTRERAS, O. O. Medial patellofemoral muscle: report of a rare variant. *Int. J. Morphol.*, 34(2):729-731, 2016.

SUMMARY: Muscle anatomic variants range from absence of a muscle to supernumerary muscles, with a spectrum of possibilities that include anomalous course, anomalous origin or insertion, accessory slips, and others. The most common muscle variants around the knee include aberrant origin and accessory slips of the gastrocnemius muscles, presence of tensor fascia suralis muscle, and accessory popliteus. The medial patellofemoral ligament is a distinct extra-articular condensation of fibers located superficially to the medial joint capsule. We describe the presence of an accessory medial patellofemoral muscle in the expected location of the medial patellofemoral ligament, which to our knowledge has not been described in the literature before.

KEY WORDS: Knee; Accessory muscles; Medial patellofemoral ligament; Medial patellofemoral muscle.

INTRODUCTION

Muscle variations include a wide array of options, and as such are quite common. Quantitative variations include supernumerary muscles or absence of muscles, while qualitative variations include anomalous origin, course, or insertion of an otherwise normal muscle.

These muscle variants have classically been described in cadaver dissections or as incidental findings during surgery. With the progressive increase in availability and clinical indications for imaging exams, added to the improvements in spatial and contrast resolution of different imaging techniques such as ultrasound, computed tomography and magnetic resonance imaging, muscle variants are found more often, and can sometimes be an important part of the clinical picture. Clinical presentation includes asymptomatic muscle variants, palpable mass, and neurovascular compression symptoms (Sookur *et al.*, 2008; Gupta & Bhagwat, 2006).

Around the knee region, the most common muscle variants are aberrant origin and accessory slips of the gastrocnemius muscles, presence of tensor fascia suralis muscle, and accessory popliteus (Sookur *et al.*). To our knowledge, no muscle variants have been described regarding the medial patellofemoral ligament.

The medial patellofemoral ligament is a distinct condensation of fibers located superficially to the joint

capsule (LaPrade *et al.*, 2007). It has an important function resisting lateral migration of the patella (Smirk & Morris, 2003; Amis *et al.*, 2003).

In the present case report, we portray the presence of an accessory muscle in the expected location of the medial patellofemoral ligament.

CASE REPORT

A 23 year old man underwent a left-knee MRI one month after a direct trauma to the knee, still experiencing pain, with the clinical suspicion of meniscal tear. Fat-saturated proton density sequences were obtained in the axial, coronal and sagittal planes. Non-saturated proton density sequences were obtained in the coronal and sagittal planes, and T2-weighted images were obtained in the axial and sagittal planes (Fig. 1).

A multifibrillar structure, isointense to skeletal muscle in all sequences was observed in the medial compartment of the knee, which originated in the medial aspect of the patella and coursed towards the medial femoral condyle, in the expected location of the medial patellofemoral ligament. These findings were compatible with a supernumerary accessory medial patellofemoral muscle.

^{*}Departamento de Radiología, Pontificia Universidad Católica de Chile, Santiago, Chile.

Adjacent to the patellar origin, fibers were loose and more disorganized, with more interspersed adipose tissue than the distal fibers towards the femoral insertion, which consisted of a more tightly packed bundle of muscle fibers. This structure coursed horizontally, immediately inferior to the distal portion of the vastus medialis obliquus, and inserted in the medial femoral condyle slightly anterior to the insertion of the adductor magnus and proximal to the origin of the medial collateral ligament.

DISCUSSION

The medial patellofemoral ligament has been described in many different publications, ranging from anatomic cadaveric studies to surgical journals regarding reconstruction techniques and MR imaging studies (De Maeseneer *et al.*, 2000; Amis *et al.*; Farrow *et al.*, 2014; Smirk & Morris; La Prade *et al.*, and others). To our knowledge, the presence of a medial patellofemoral muscle has not been described before.

Most of the literature describing the anatomy of the medial patellofemoral ligament (Farrow *et al.*; LaPrade *et al.*; Amis *et al.*) mentions a close relationship between the femoral origin of the medial patellofemoral ligament and the distal insertion of the vastus medialis obliquus muscle, as well as the distal insertion of the adductor magnus. Thus, we hypothesize that the accessory muscular fibers found in the presented case could correspond to remnants of these very closely related muscles, probably due to lack of involution of muscle fascicles during the embryologic development of the vastus medialis obliquus or adductor magnus.

In this case, the patient had no symptoms related to the presence of this accessory muscle, but given the superficial location and the function of the medial patellofemoral ligament, we think a palpable mass and alterations in patellar stability could be part of the clinical picture.

In our institution, approximately 3500 knee MRI exams are reported yearly, and such a conspicuous muscle variant as a medial patellofemoral muscle has not been noted before, adding to the fact that it has not been reported in the literature, which leads us to consider this a rare variant that can be recognized in imaging exams.

BEDDINGS, M. I.; BURDILES, O. A. & CONTRERAS, O. O. Músculo patelofemoral medial: reporte de una rara variante. *Int. J. Morphol.*, 34(2):729-731, 2016.

RESUMEN: Las variantes anatómicas musculares van desde la ausencia de un músculo hasta la presencia de músculos supernumerarios, en un espectro de posibilidades que incluyen trayecto anómalo, origen anómalo o inserción, fascículos accesorios, y otros. Las variantes más comunes de músculos presentes alrededor de la rodilla incluyen el origen aberrante y fascículos accesorios del músculo gastrocnemio, la presencia del músculo tensor de la fascia sural y el músculo poplíteo accesorio. El ligamento medial patelofemoral es una clara condensación extra-articular de fibras localizado superficialmente a la cápsula articular medial. Se describe la presencia de un músculo patelofemoral medial accesorio en la ubicación esperada del ligamento patelofemoral medial, que a nuestro conocimiento no se ha descrito antes en la literatura.

PALABRAS CLAVE: Rodilla; Músculos accesorios; Ligamento patelofemoral medial; Músculo patelofemoral medial.

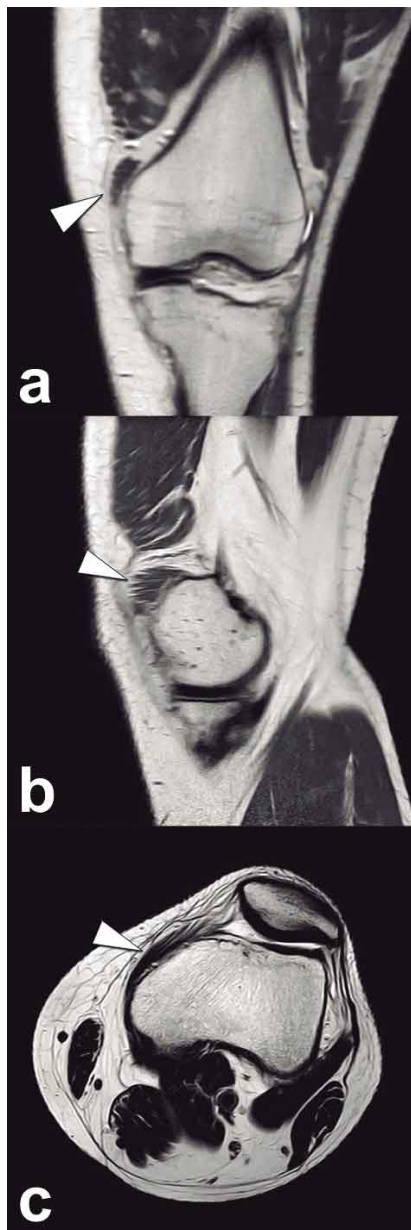


Fig. 1. Coronal (a) and sagittal (b) non-saturated proton density-weighted images, and axial T2-weighted image (c) show a multifibrillar structure, isointense to muscle in all sequences, in the expected location of the medial patellofemoral ligament, compatible with a supernumerary medial patellofemoral muscle.

REFERENCES

- Amis, A. A.; Firer, P.; Mountney, J.; Senavongse, W. & Thomas, N. P. Anatomy and biomechanics of the medial patellofemoral ligament. *Knee*, 10(3):215-20, 2003.
- De Maeseneer, M.; Van Roy, F.; Lenchik, L.; Barbaix, E.; De Ridder, F. & Osteaux, M. Three layers of the medial capsular and supporting structures of the knee: MR imaging-anatomic correlation. *Radiographics*, 20 Spec. No.:S83-9, 2000.
- Farrow, L. D.; Alentado, V. J.; Abdulnabi, Z.; Gilmore, A. & Liu, R. W. The relationship of the medial patellofemoral ligament attachment to the distal femoral physis. *Am. J. Sports Med.*, 42(9):2214-8, 2014.
- Gupta, R. K. & Bhagwat, S. S. An anomalous muscle in the region of the popliteal fossa: A case report. *J. Anat. Soc. India*, 55(2):65-8, 2006.
- LaPrade, R. F.; Engebretsen, A. H.; Ly, T. V.; Johansen, S.; Wentorf, F. A. & Engebretsen, L. The anatomy of the medial part of the knee. *J. Bone Joint Surg. Am.*, 89(9):2000-10, 2007.
- Smirk, C. & Morris, H. The anatomy and reconstruction of the medial patellofemoral ligament. *Knee*, 10(3):221-7, 2003.
- Sookur, P. A.; Naraghi, A. M.; Bleakney, R. R.; Jalan, R.; Chan, O. & White, L. M. Accessory muscles: anatomy, symptoms, and radiologic evaluation. *Radiographics*, 28(2):481-99, 2008.

Correspondence to:
Oscar Contreras Olea
Hospital Clínico Pontificia Universidad Católica de Chile.
Marcoleta 367
Santiago
CHILE

Email: concontrer@med.puc.cl

Received: 27-11-2015
Accepted: 06-04-2016