

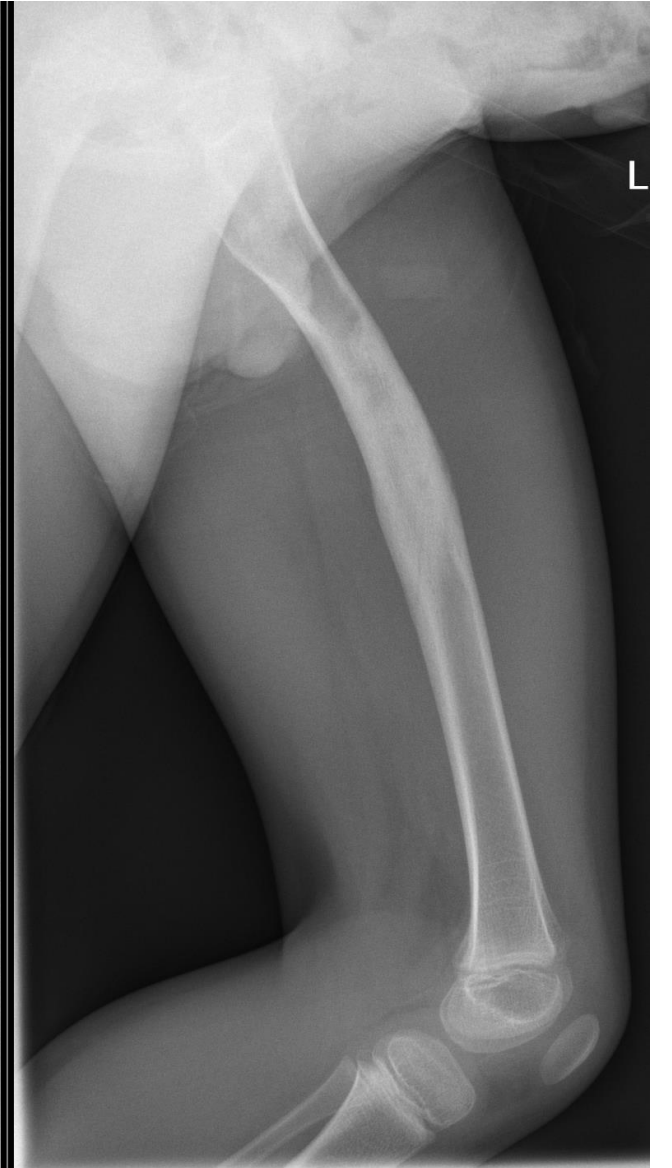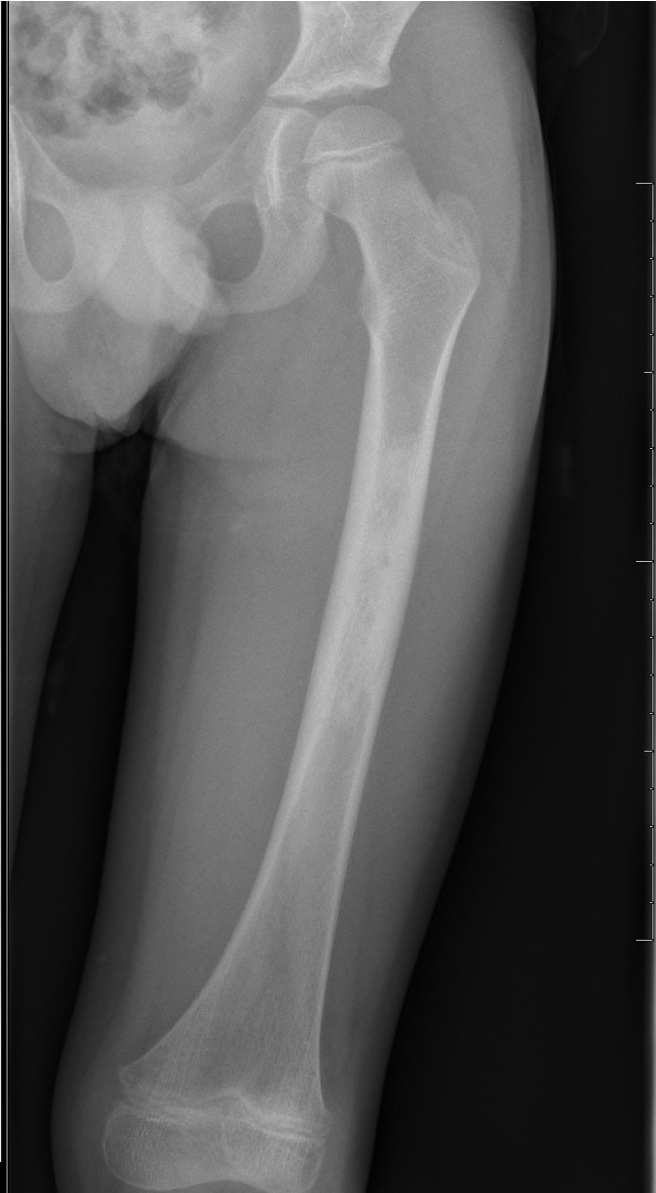
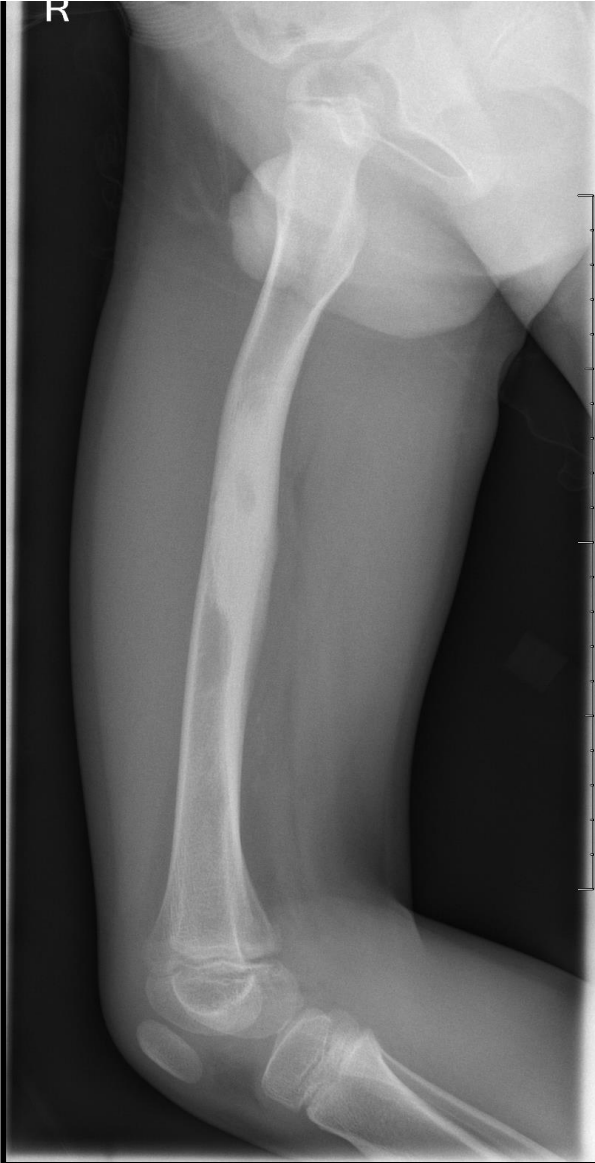
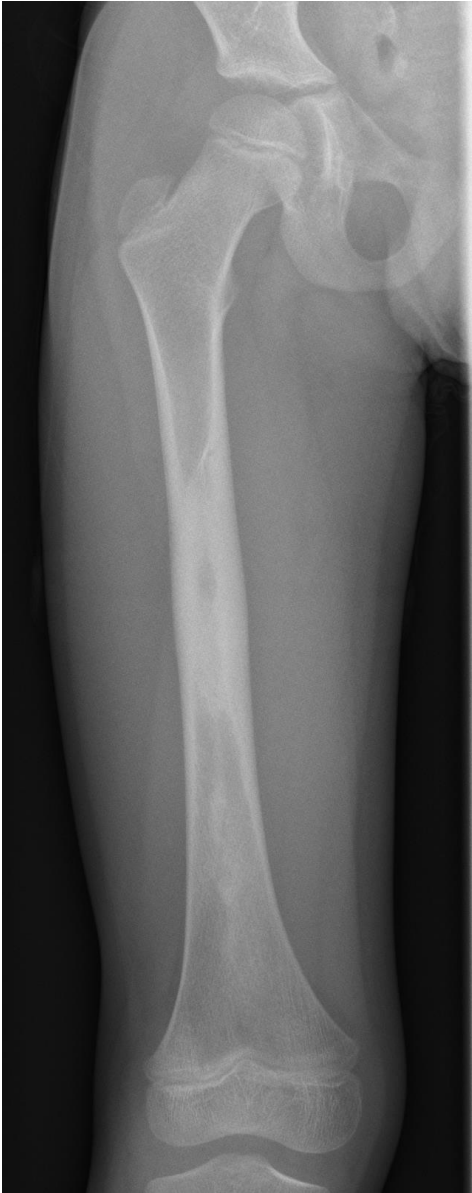
Child with bilateral femoral sclerosis

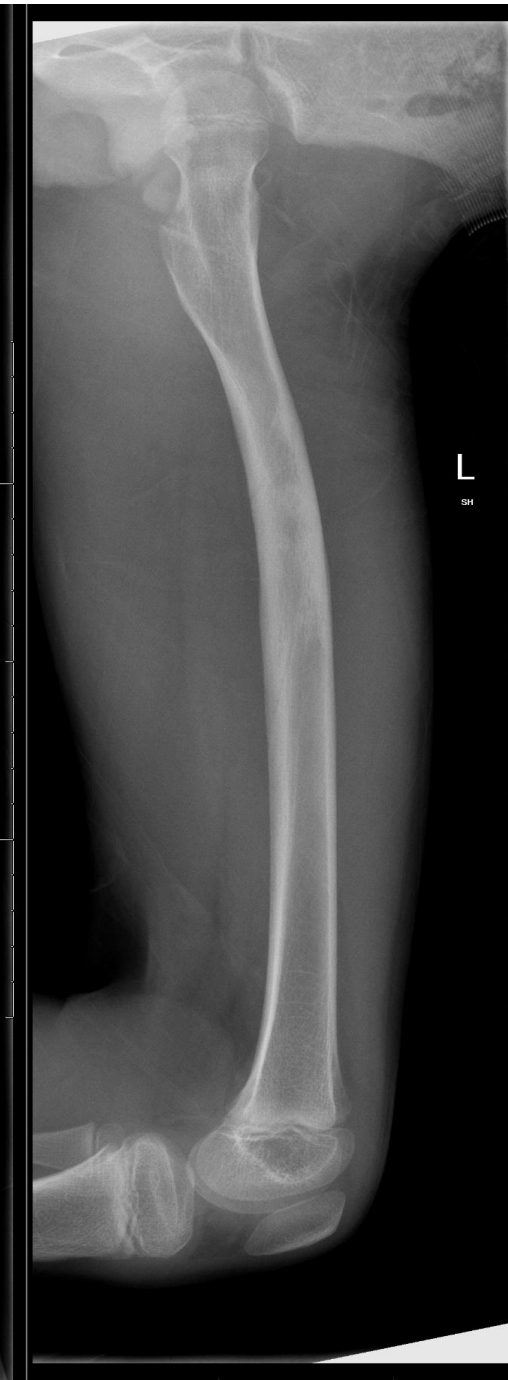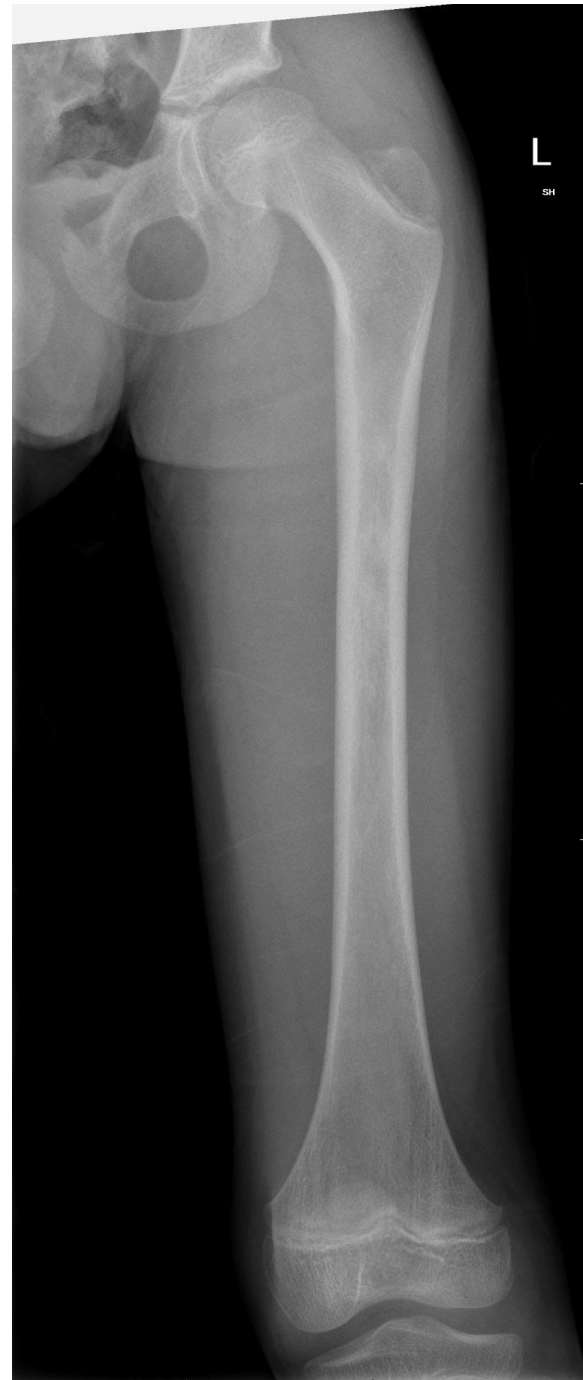
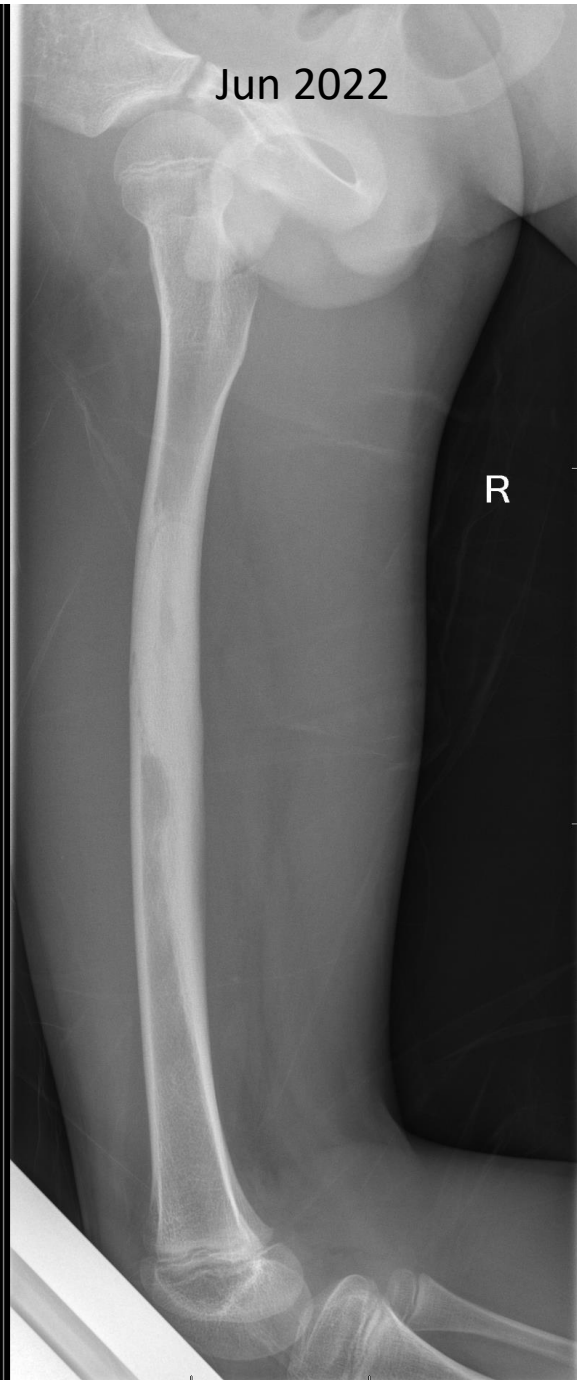
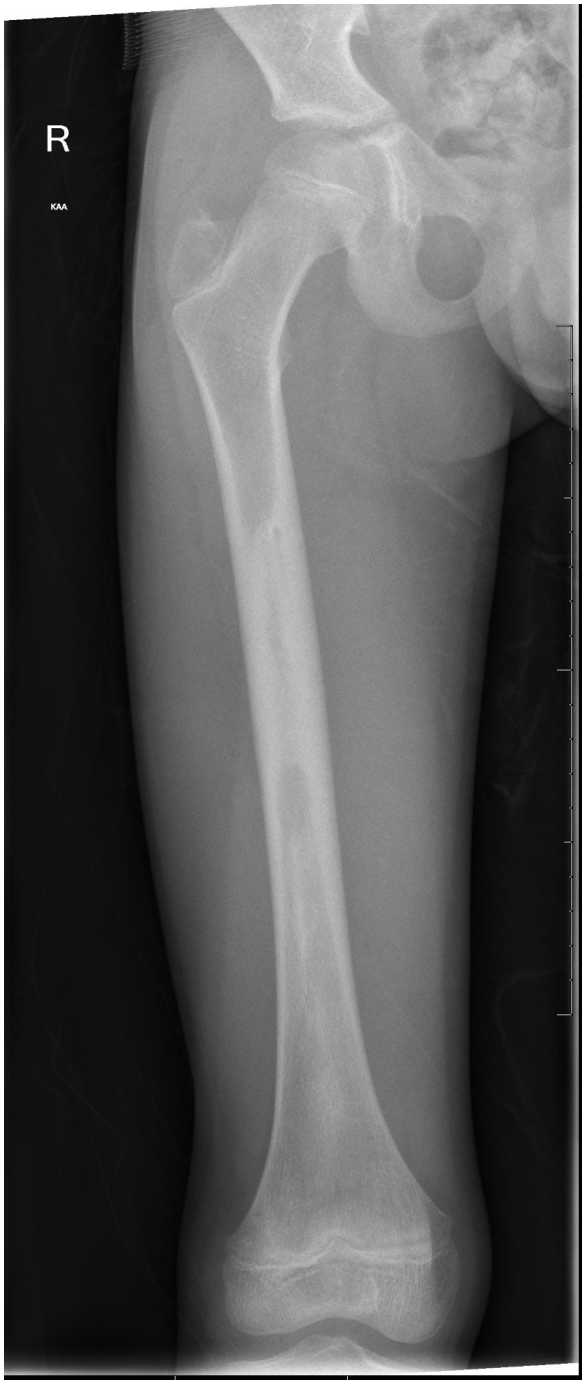
Talaat Youssef

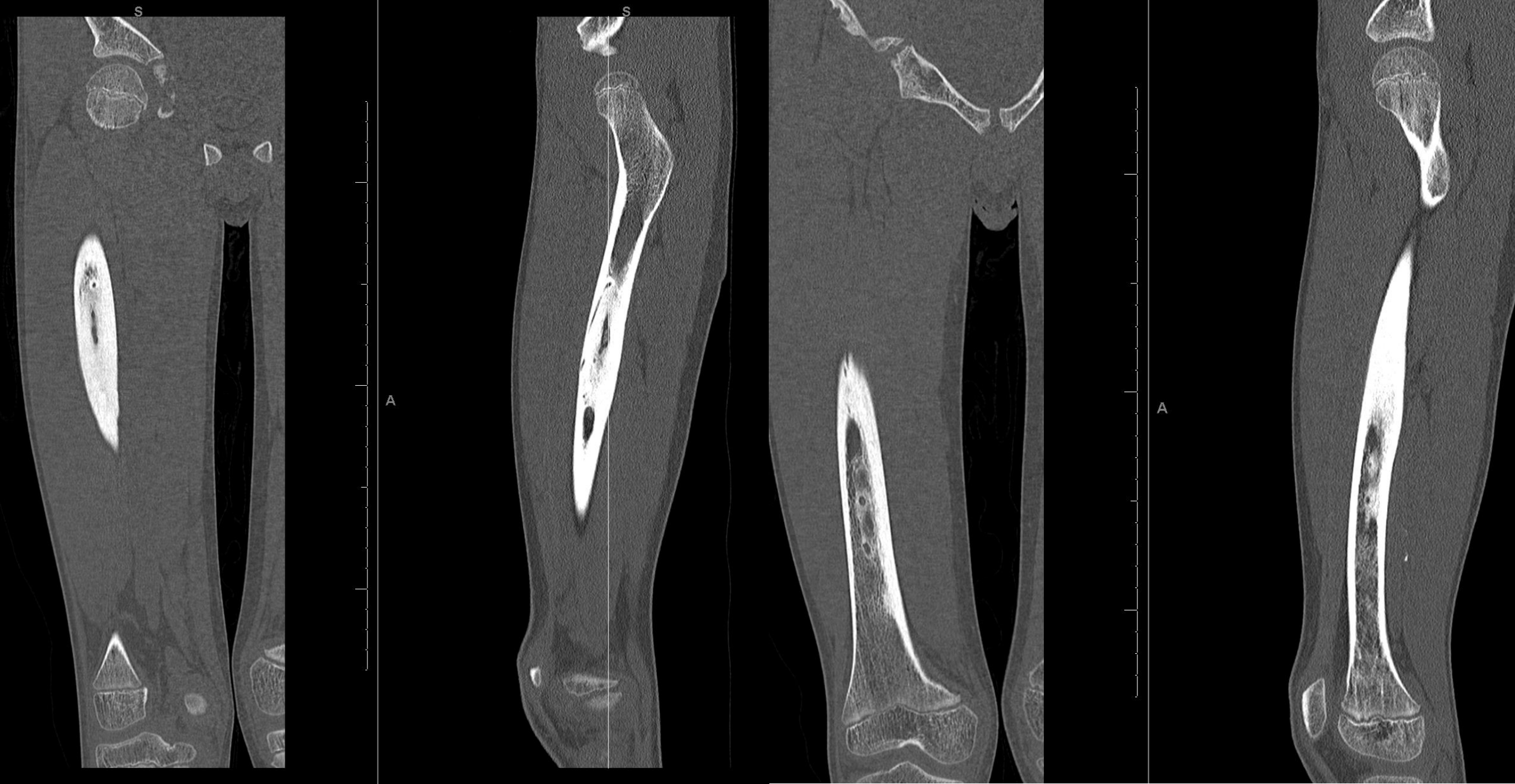Sidra Medicine, Doha, Qatar

- 9-year-old boy
- Ex rem with bilateral femoral fractures
- Chronic intermittent extreme pain in both thighs for more than 2 years
- Bilateral chronic thigh pain
- No history of any nailing done in past. No dermatological manifestations.

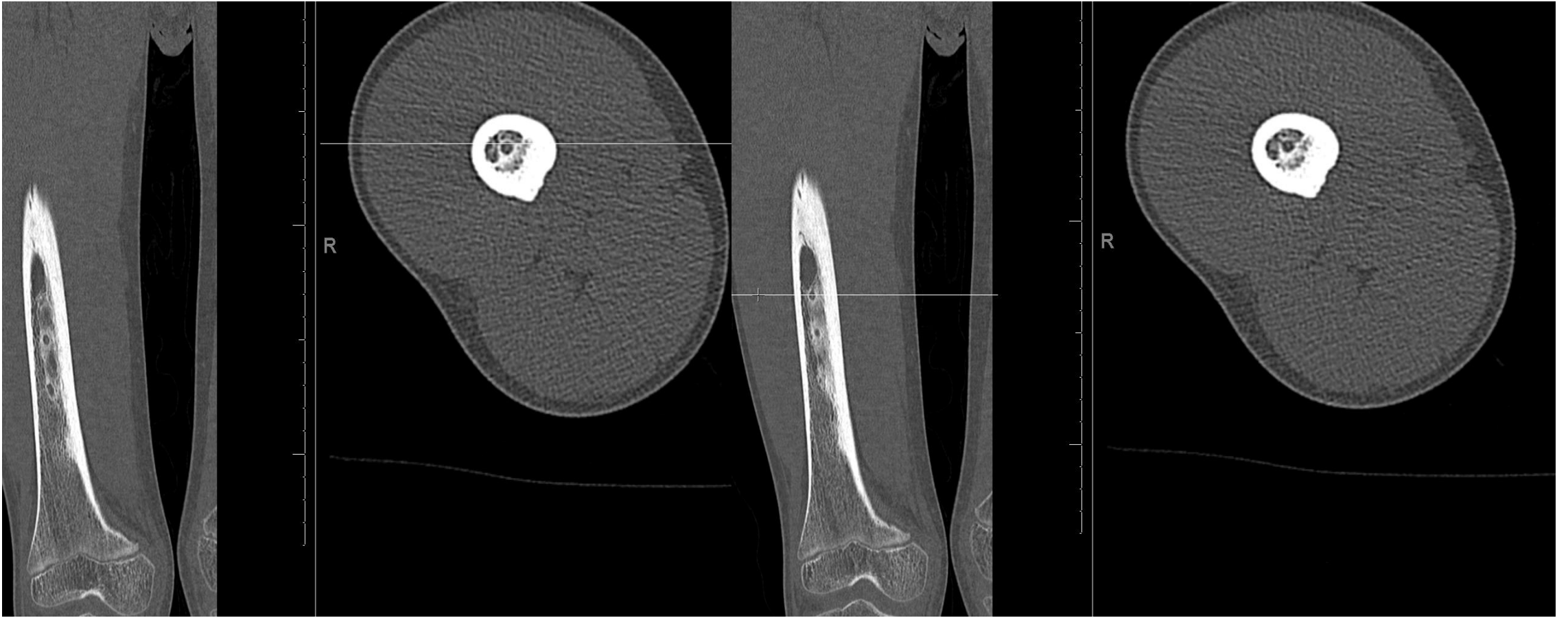
Mar 2019



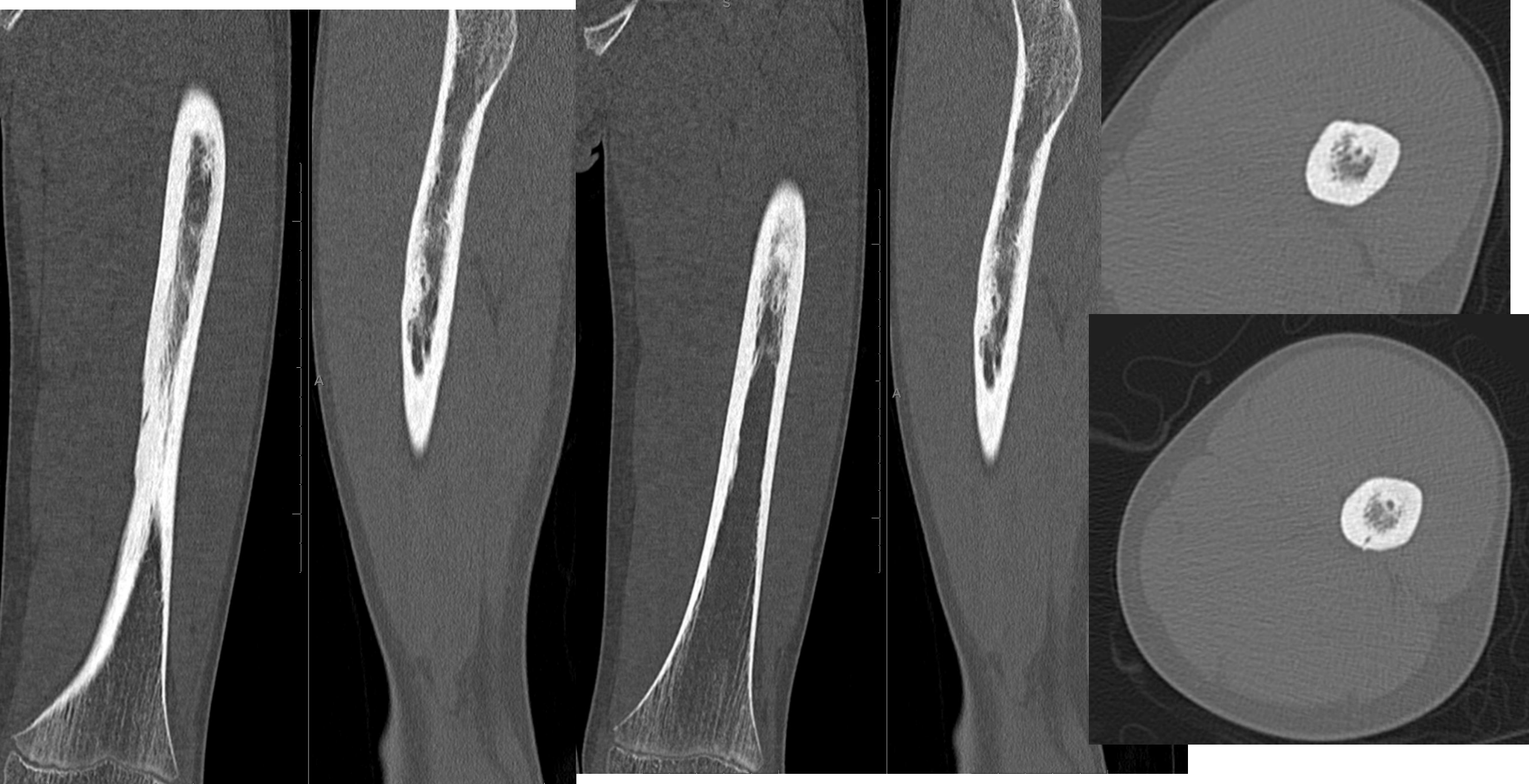



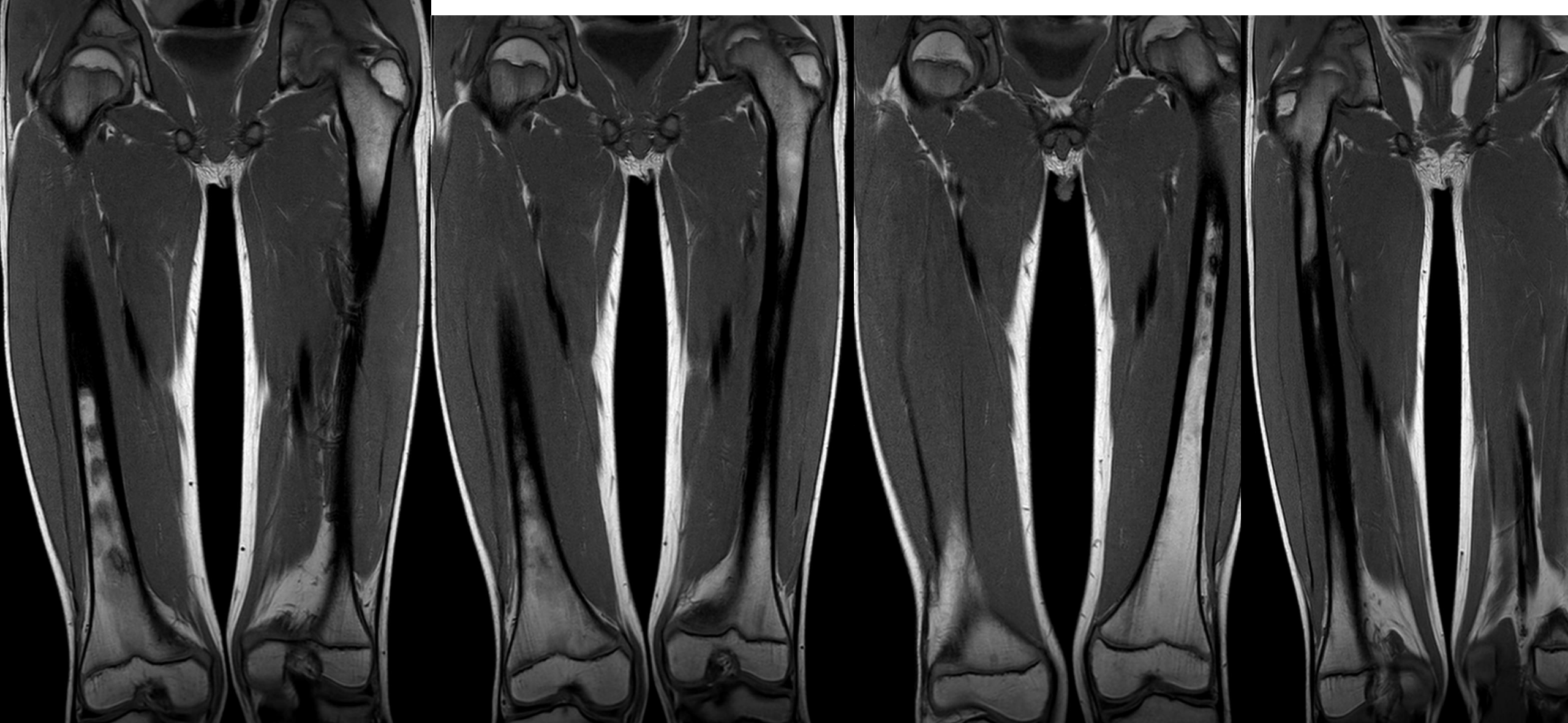
RIGHT FEMUR

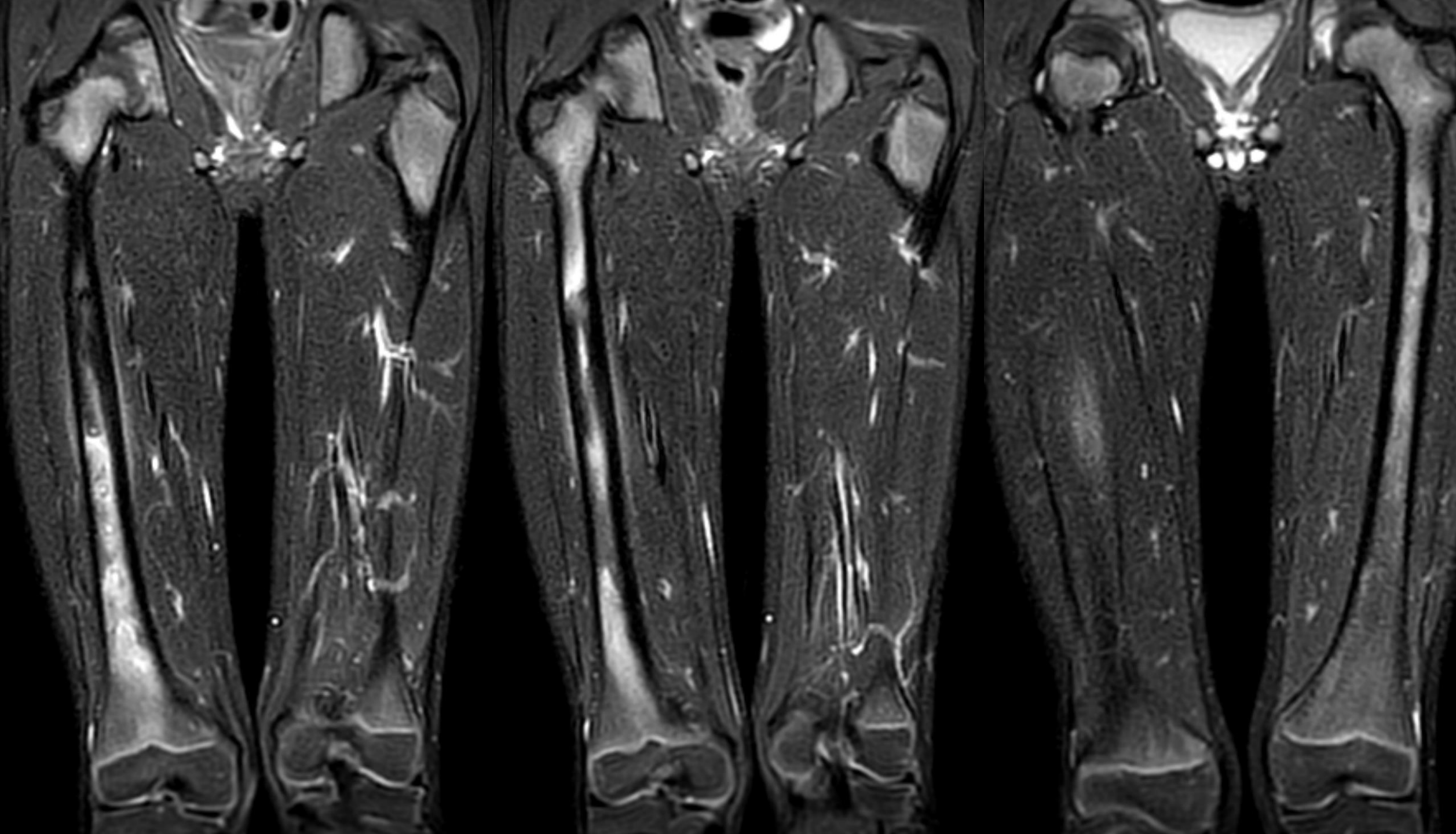


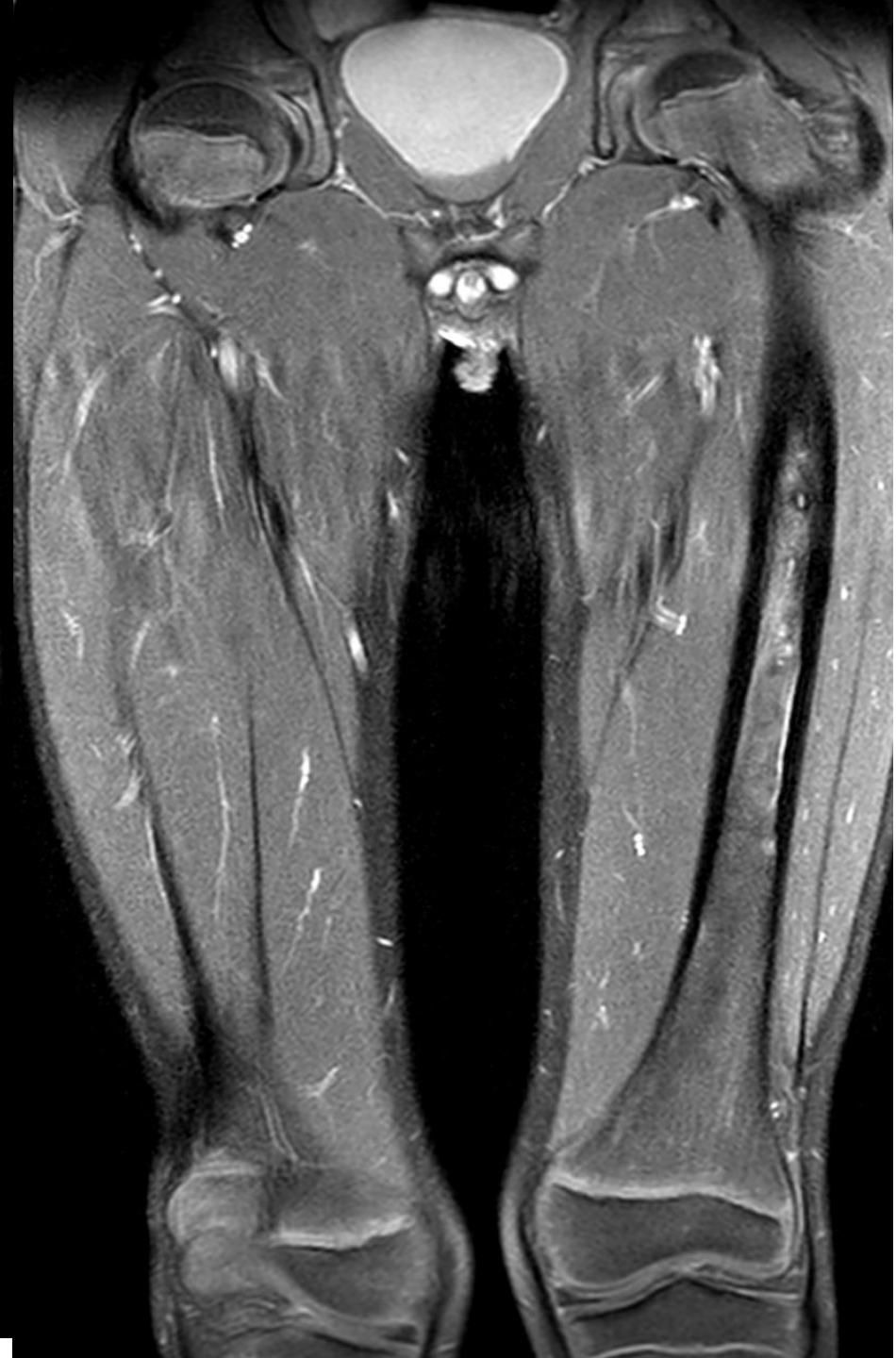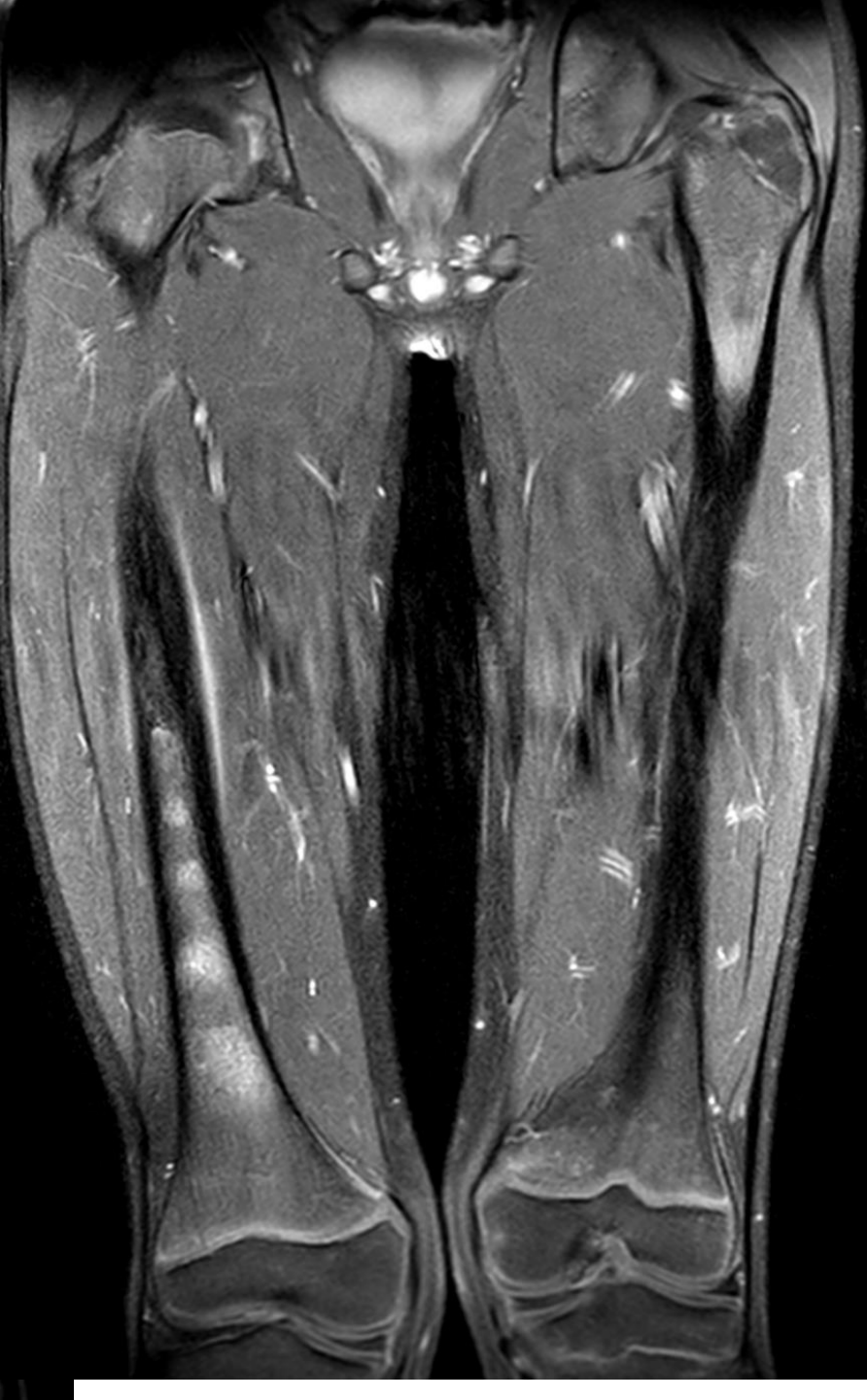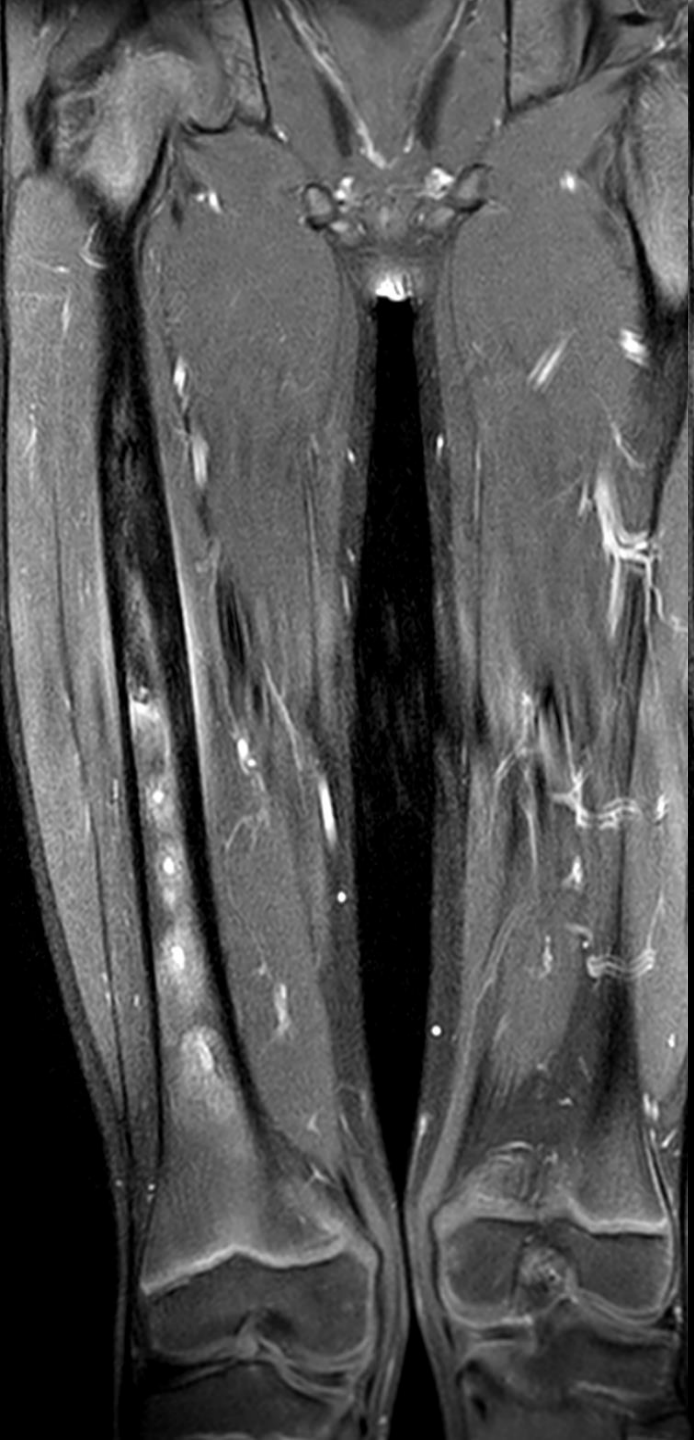
RT FEMUR

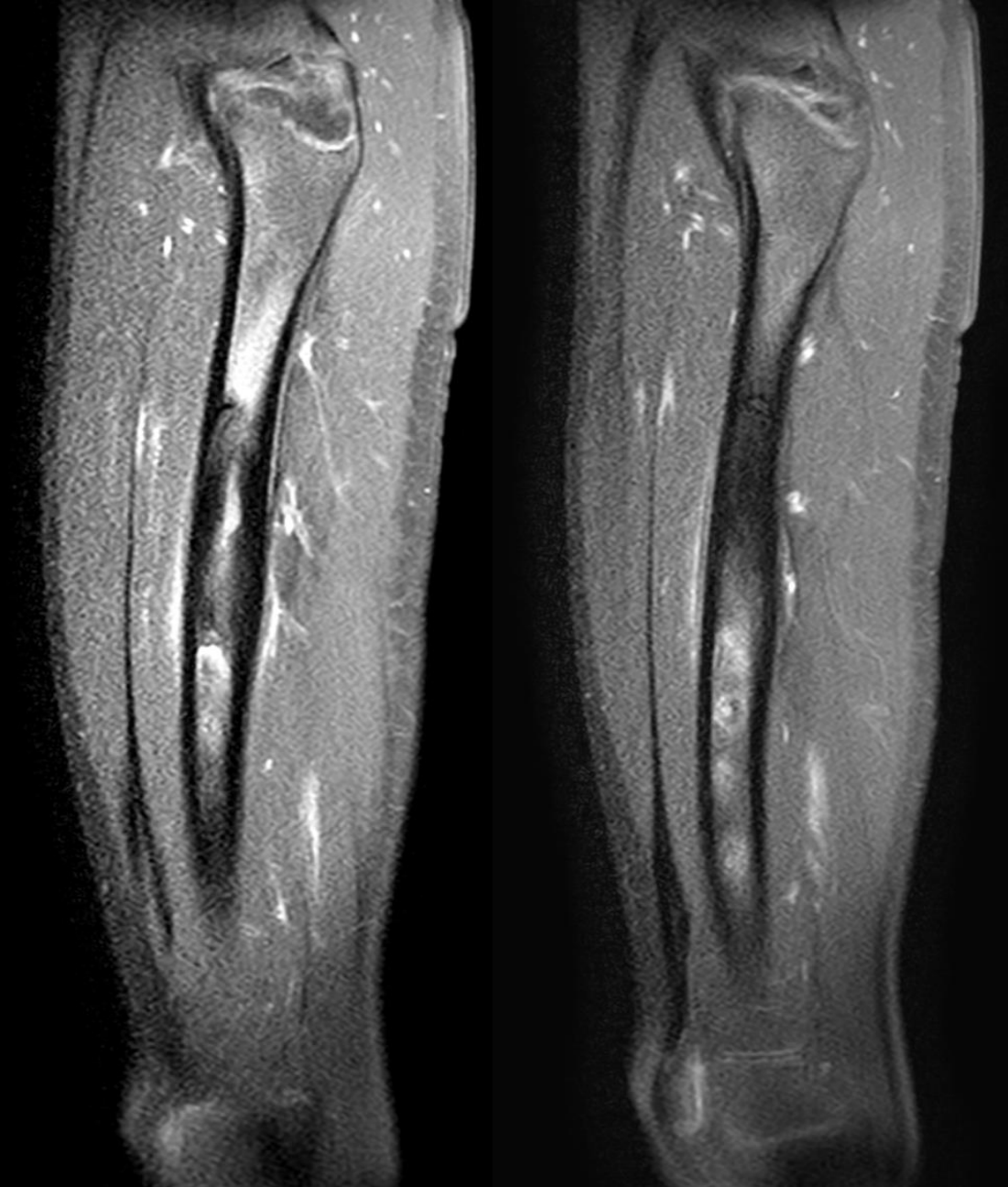


LEFT FEMUR

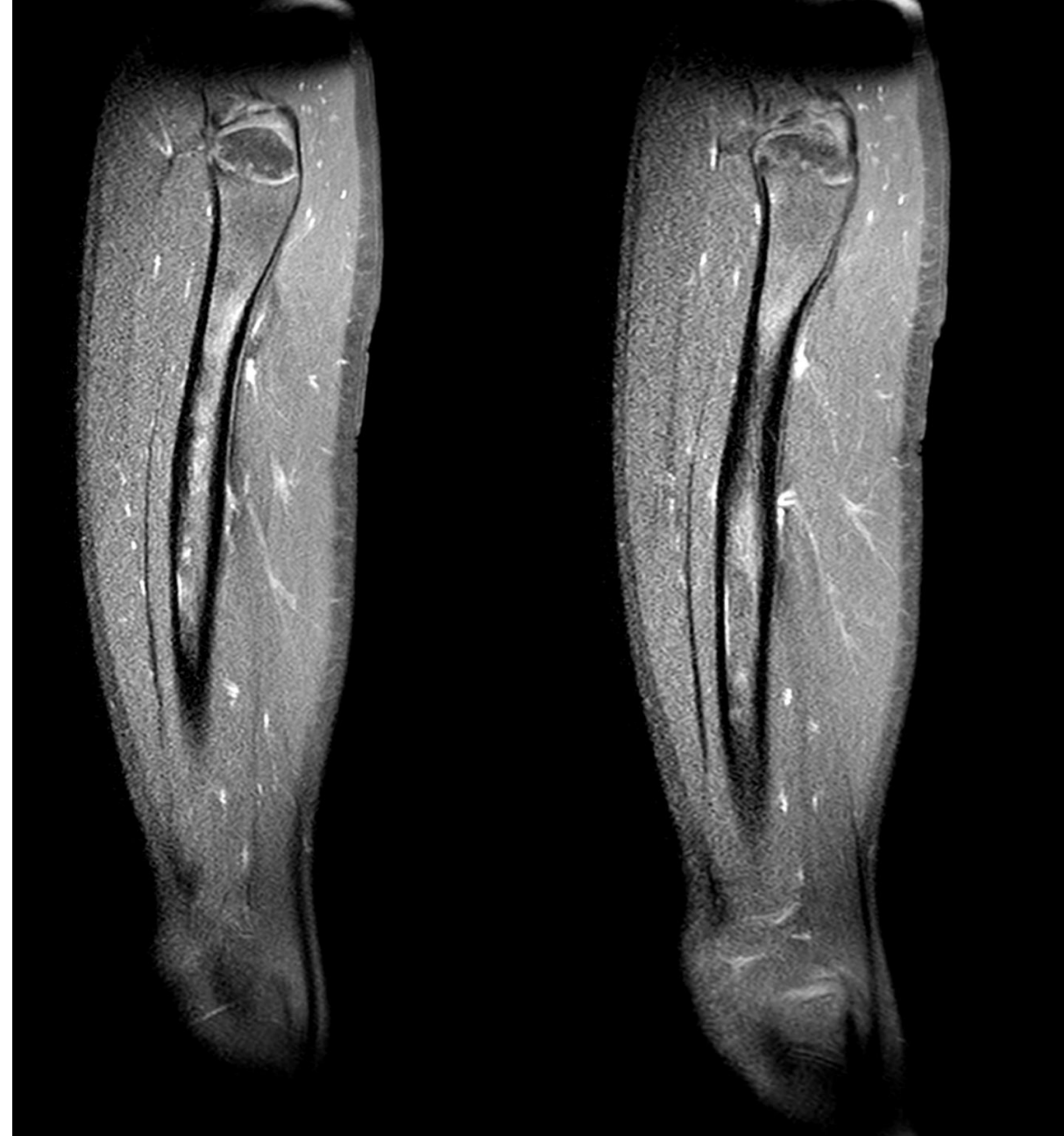








RT Sag post C+ T1FS



Lt Sag post C+ T1FS