

Case Report

Imaging in retropubic cartilaginous cyst

Apurva Javalgi¹, Aruna R. Patil¹

¹Department of Radiology, Apollo Hospitals, Bengaluru, Karnataka, India.



*Corresponding author:

Aruna R. Patil,
Department of Radiology,
Apollo Hospitals, Bengaluru,
Karnataka, India.

dr.arunapatil@gmail.com

Received: 25 August 2021
Accepted: 02 March 2022
Epub Ahead of Print: 21 April 2022
Published: 21 December 2022

DOI
10.25259/IJMSR_46_2021

Quick Response Code:



ABSTRACT

The retropubic cartilaginous cyst is a benign slow-growing degenerative lesion arising from the fibrocartilage of the pubic symphysis. Degeneration is secondary to multiparity or pelvic trauma. The symptoms are commonly urinary tract-related and vary depending on the location. A confident diagnosis can be made on MRI demonstrating typical continuity with the pubic symphyseal joint, pubic diastasis, and cartilage signal. Management is typically conservative, with large lesions and failed conservative treatment requiring excision.

Keywords: retropubic cartilaginous cyst, degeneration, symphysis pubis, magnetic resonance imaging

INTRODUCTION

A pubic cartilaginous cyst is a rare, slow-growing degenerative lesion arising from the fibrocartilaginous part of the pubic symphysis joint, mainly associated with the conditions of wear and tear of the joint including multiparity, multiple vaginal deliveries, and pelvic trauma. Based on site of origin, it can either be suprapubic, retropubic, or subpubic in location. Since it is an uncommon lesion, it is often misdiagnosed. Magnetic resonance imaging (MRI) is the investigation of choice for diagnosis. This condition is often managed conservatively unless causing recurring pressure symptoms on the urinary bladder.

CASE REPORT

A 67-year-old female, gravida 12 and parity 10 with all vaginal deliveries, presented with the symptoms of lower abdominal pain, intermittent urinary incontinence, and low backache. History of recurrent urinary tract infections (UTI) and dyspareunia was present. Initial imaging workup was done for urinary symptoms. On ultrasonography (USG), low-level internal echoes were noted in the urinary bladder suggestive of cystitis. A well-defined hypoechoic lesion was noted anterior to the base of the urinary bladder appearing to arise from symphysis pubis. Mild pubic diastasis was additionally noted [Figure 1]. Plain computed tomography (CT) of the pelvis was suggested suspecting bony origin growth. CT showed an isodense rounded lesion within the space of Retzius (retropubic/prevesical space) indenting the neck of the urinary bladder with no internal calcifications. Mild pubic diastasis (13 mm) was seen. No obvious pubic bony erosions/destruction/periosteal reaction was seen [Figure 2]. The origin of the lesion could not be ascertained on CT.

MRI was done for further characterization of the lesion. On MRI, the lesion was well defined with smooth wall appearing isointense on T1-weighted images and hyperintense on T2-weighted

This is an open-access article distributed under the terms of the Creative Commons Attribution-Non Commercial-Share Alike 4.0 License, which allows others to remix, transform, and build upon the work non-commercially, as long as the author is credited and the new creations are licensed under the identical terms.

©2022 Published by Scientific Scholar on behalf of Indian Journal of Musculoskeletal Radiology

images. The lesion was seen to be in continuity with the pubic symphyseal cartilage through a small stalk-like connection [Figures 3 and 4]. Pubic diastasis was reconfirmed. No marrow edema was noted in the pubic bones. There was no associated soft-tissue growth. The lesion was indenting the bladder neck with no infiltration. No diffusion restriction of contents or blooming on the susceptibility-weighted sequence was noted [Figure 5]. Based on the MRI findings and history of multiparity and vaginal deliveries, a diagnosis of retropubic benign cartilaginous cyst secondary to pubic symphyseal fibrocartilage degeneration was made. The intermittent urinary incontinence was probably attributed to the mass effect by the lesion of the base of the urinary bladder. At present, the patient is reassured and is on follow-up.

DISCUSSION

The symphysis pubis is a fibrocartilaginous union between the two pubic bones forming a non-synovial amphiarthrodial joint.^[1] The fibrocartilaginous disc of the pubic symphysis joint may undergo mucinous cystic changes as a result of repeated mechanical stress as in postmenopausal status due to decreased pelvic connective tissue resilience, multiparity, multiple vaginal deliveries, or pelvic trauma.^[1,2] Although the disc can resist tension and shearing, it can widen during pregnancy helping in parturition,^[2] repeated strain leads to degeneration of joint space and cystic outpouching of mucinous and fibrocartilaginous contents. Thus, pubic cysts are degenerative cysts containing a collagenous capsule with fibrocartilaginous tissue and mucinous contents.^[3]

Based on the site of origin of the cyst from the joint cartilage, they can be suprapubic, retropubic, and subpubic in location. All three types are initially located in the space of Retzius between the anteroinferior bladder wall and pubic symphysis and are asymptomatic in the early stages. As they grow in size, they produce symptoms according to the location. The exact incidence is not available as there are only case reports on literature search.

Subpubic cysts mainly present as a painless vulvar mass, mass just beneath the clitoris, dyspareunia, obstructive voiding symptoms, and acute urinary retention.^[3,4] Retropubic cyst mainly causes a mass effect on the anteroinferior bladder wall and proximal urethra

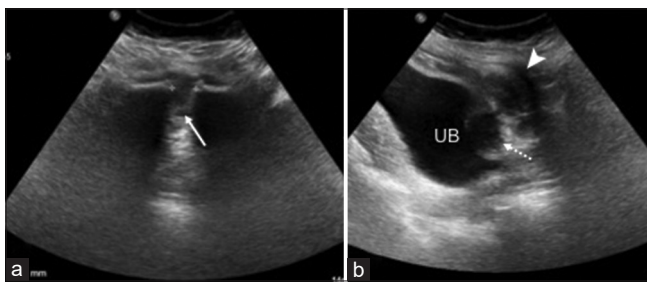


Figure 1: (a) Ultrasonography pelvis in axial plane shows pubic diastasis (white arrow) measuring 13 mm. (b) Sagittal plane shows a rounded hypoechoic lesion (dotted arrow) between the UB and pubic bone (white arrowhead). UB: Urinary bladder.

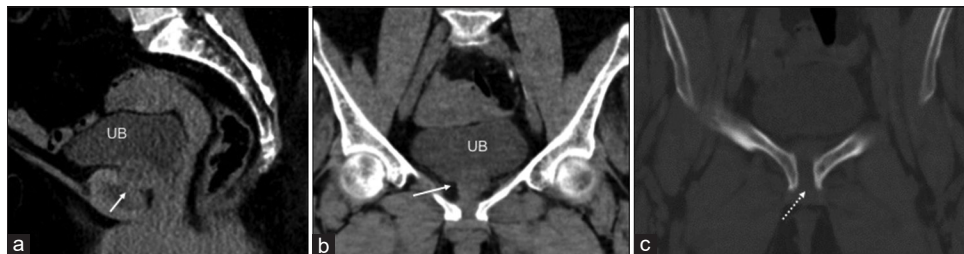


Figure 2: (a and b) Pelvis CT in sagittal and coronal sections show a well-defined isodense lesion (white arrow) in the space of Retzius (prevesical space) indenting the bladder neck. (c). Coronal section in bone window shows pubic diastasis and absent bony erosions (dotted arrow). UB: Urinary bladder.

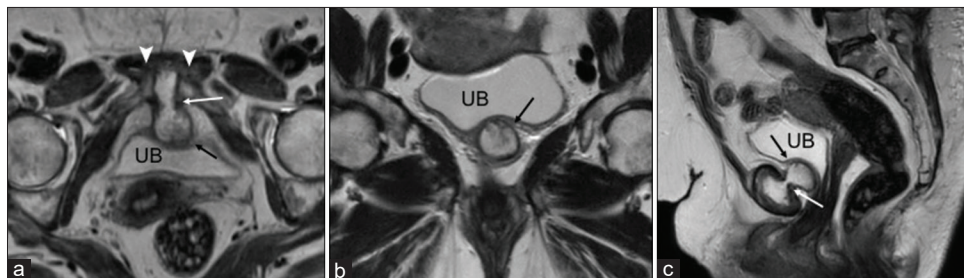


Figure 3: T2-weighted MR images in axial (a), coronal (b), and sagittal (c) planes show a well-defined hyperintense lesion (black arrow) in the space of Retzius in continuity with the symphyseal cartilage with a connecting stalk (white arrow). Note indentation of the bladder neck by the mass on sagittal plane. White arrowheads show pubic diastasis.

causing stress urinary incontinence as the earliest symptom due to pressure from the cyst on the anterior part of the urethra, resulting in a decreased urethral “knack” function during increased abdominal pressure.^[4] It can further develop into a suprapubic or subpubic cyst, as it grows in size. It can also lead to recurrent UTI and dyspareunia.^[4,5] Suprapubic cysts mainly cause mass effect on the anterior bladder wall – presenting with decreased urinary retention, increased frequency, and recurrent UTI.

They are usually radiographically occult due to their soft-tissue nature. Most of these cases have pubic diastasis which can be the only finding on radiographs.^[2,4] On USG, especially the smaller lesions are often missed as they tend to be obscured by the bony pubic shadow and have to be specifically looked for on strong clinical suspicion or retrospection. Larger lesions are seen as thick-walled heteroechoic cystic focus anterior to the bladder, better visualized on a full bladder, and appear arising from the pubic symphysis. In general, they are devoid of vascularity on Doppler. On CT, they appear as iso- to hyper-dense lesions with a connective stalk with the symphysis as in our case. MRI is the investigation of choice for diagnosis and also aids in differentiating from more sinister mimics. They are typically seen arising from joint space appearing hypo- to iso-intense on T1W imaging, hyperintense on T2, not showing fat suppression, or any blooming on susceptibility-weighted images. Smooth rim enhancement may be seen post-contrast.^[6]

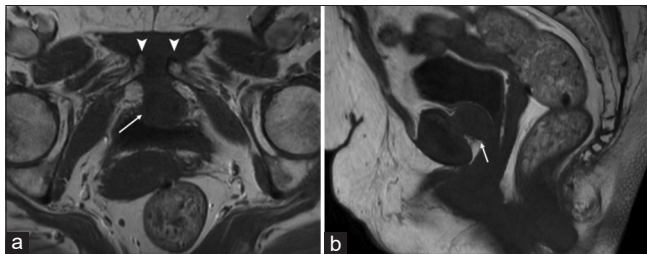


Figure 4: T1-weighted MR images in axial (a) and sagittal (b) plane show the lesion as isointense to the muscle (white arrow) and in continuity with the symphyseal cartilage. White arrowheads show pubic diastasis.

The common differentials include urinary bladder diverticulum, bony lesions of the pubis, remnant urachal tract, abscess due to osteoarticular infection or tuberculosis, and pseudosynovial cyst arising from a rheumatoid joint.^[5] The bladder diverticulum shows lumen continuity with the bladder and shows variable filling. Infections of pubic symphysis generally present with focal pain, fever and show marrow edema and adjacent soft-tissue inflammation on MRI.

A subpubic cyst may mimic other vulvar masses such as lipomas, nabothian cysts, Bartholin cysts, Gartner cysts, squamous cell carcinoma of the clitoris, Bartholin’s gland carcinoma, basal cell carcinoma, or vulvar melanoma^[3] which can be differentiated by demonstrating its origin from the pubic symphysis.^[3,4]

A case of parasymphyseal pubic cartilaginous cyst published by Tan *et al.* had imaging features resembling chondrosarcoma.^[7] Chondrosarcomas generally are large heterogeneous tumors with chondroid matrix, adjacent organ infiltration, and need tissue biopsy for its diagnosis.^[5] Martel and Spouge published a case of a subpubic cyst containing a locule of gas but this is the only published case containing punctate calcifications and gas locules.^[8]

The retropubic cartilaginous cyst is a benign condition with no reported incidence of malignant transformation, hence can be managed conservatively with analgesics and anti-inflammatory drugs. Aspiration and steroid injection have been tried but recurrence is reported.^[3] Symptomatic pressure symptoms and recurrent UTI warrant surgical excision. No incidences of recurrence have been reported up to 3 years after surgery.^[4] The combination of predisposing conditions for symphyseal strain along with classical MRI features as described would confidently lead to the diagnosis of a retropubic cartilaginous cyst, hence patient reassurance and avoiding unnecessary invasive management.

CONCLUSION

Pubic cartilaginous cysts are slow-growing degenerative benign lesions, occurring commonly in postmenopausal

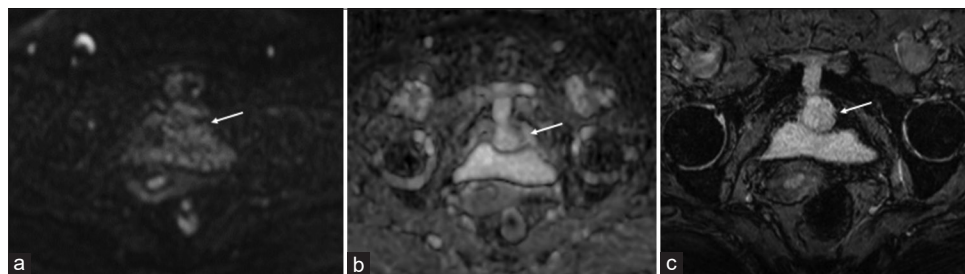

Figure 5: Diffusion-weighted imaging (a) and ADC (b) in axial section shows no diffusion restriction of the lesion (arrow). (c) Gradient echo in axial section (FFE) reveals no blooming artifacts within the lesion/lesion wall.

multiparous women or after pelvic trauma, in supra/retro/subpubic locations. This condition is often misdiagnosed due to their variable presentation and pressure symptoms. MRI is of diagnostic value and also differentiates from their mimics. It is often managed conservatively unless severe pressure symptoms warranting surgical resection.

Declaration of patient consent

The authors certify that they have obtained all appropriate patient consent.

Financial support and sponsorship

Nil.

Conflicts of interest

There are no conflicts of interest.

REFERENCES

1. Hoogendoorn R, Kayser H, Weening J, van Geloven A. Subpubic cartilaginous cystic lesion presenting as a vulvar

- mass: A case report. *J Med Case Rep* 2009;3:7294.
2. Farag F, van der Geest I, Hulsbergen-van de Kaa C, Heesakkers J. Subpubic cartilaginous pseudocyst: Orthopedic feature with urological consequences. *Case Rep Urol* 2014;2014:176089.
3. Alguacil-Garcia A, Littman CD. Subpubic cartilaginous cyst: Report of two cases. *Am J Surg Pathol* 1996;20:975-9.
4. Elmelund M, Thind P, Klarskov N. Retropubic cartilaginous cyst presenting as stress urinary incontinence. *Int Urogynecol J* 2015;26:455-7.
5. Durgakeri P, Strauss P, Stribley K. Suprapubic cartilaginous cyst-a case report. *Aust Med J* 2013;6:126-8.
6. Kim CE, Beasley HS. MRI diagnosis of subpubic cartilaginous cyst. *AJR Am J Roentgenol* 2004;182:144-6.
7. Tan TJ, Wong SK, Foo LS. A parasymphyseal pubic cartilaginous cyst masquerading as chondrosarcoma. *Clin Radiol* 2012;67:508-10.
8. Martel JB, Spouge AR. Gas-filled parasymphyseal pubic cyst associated with degenerative joint disease. *Skeletal Radiol* 2007;36:S112-5.

How to cite this article: Javalgi A, Patil AR. Imaging in retropubic cartilaginous cyst. *Indian J Musculoskeletal Radiol* 2022;4:103-6.