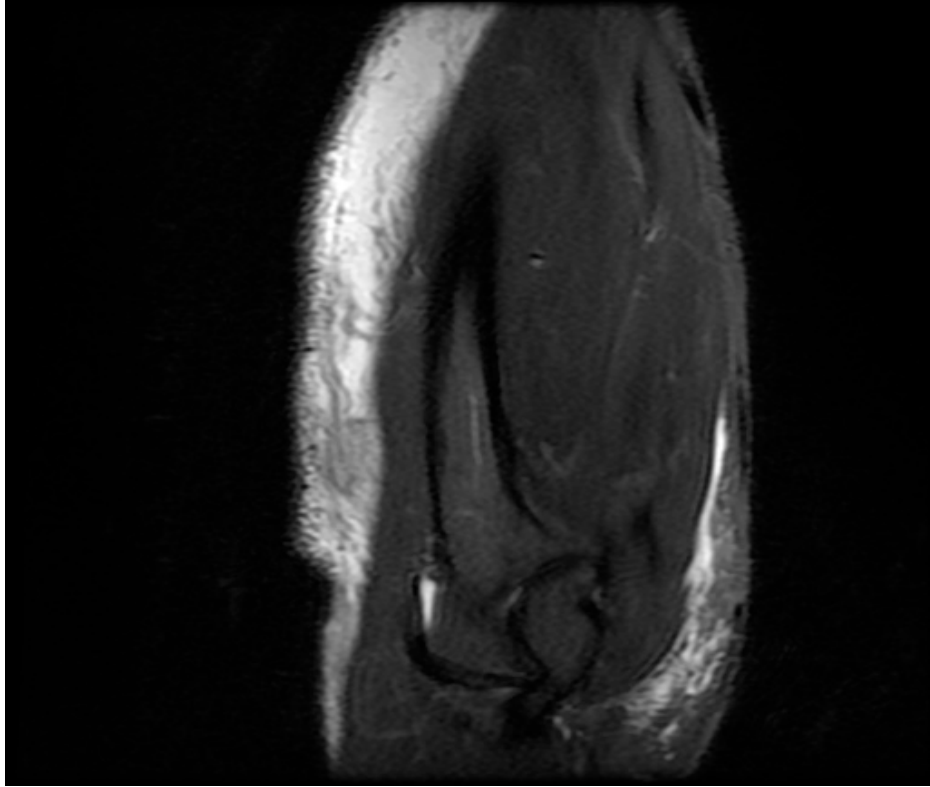
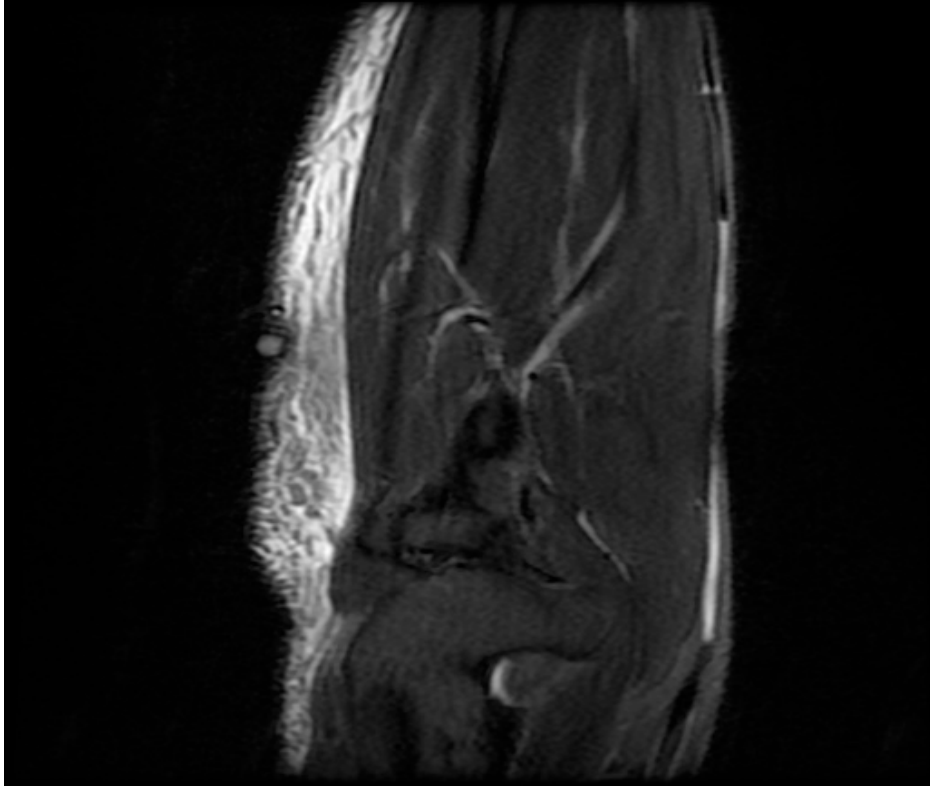
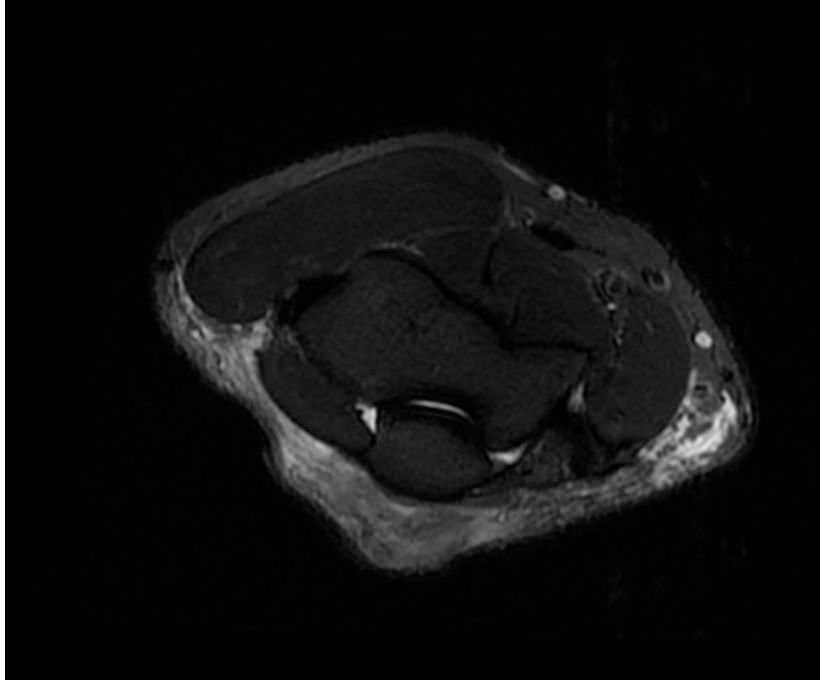
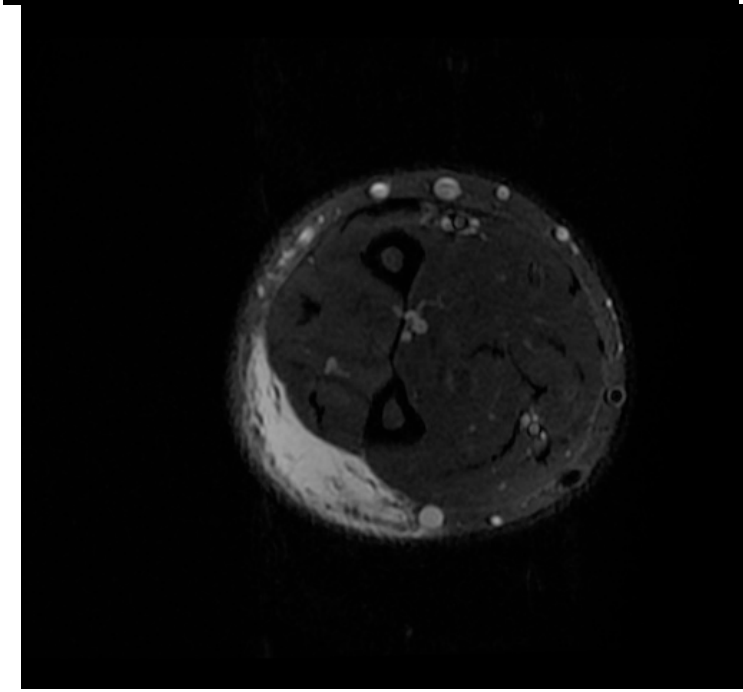
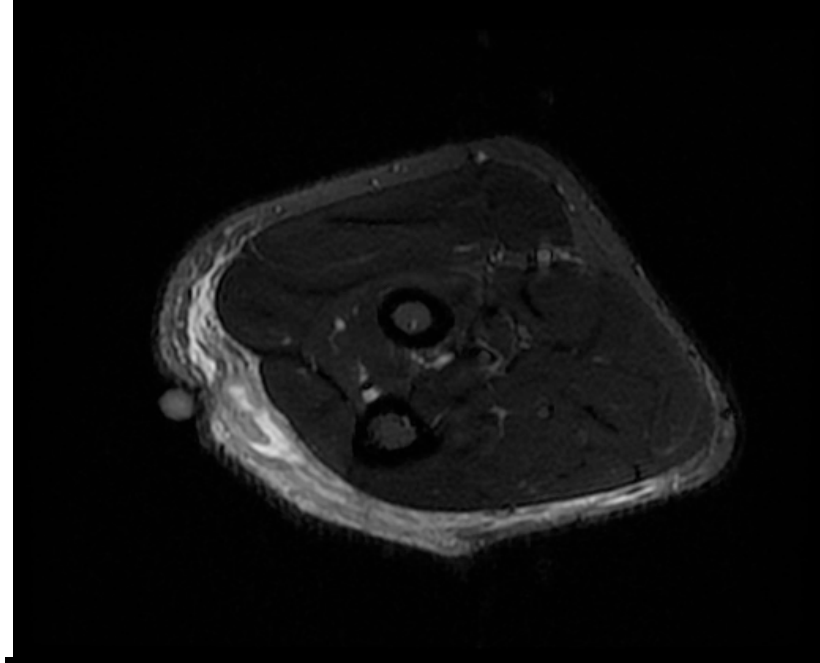
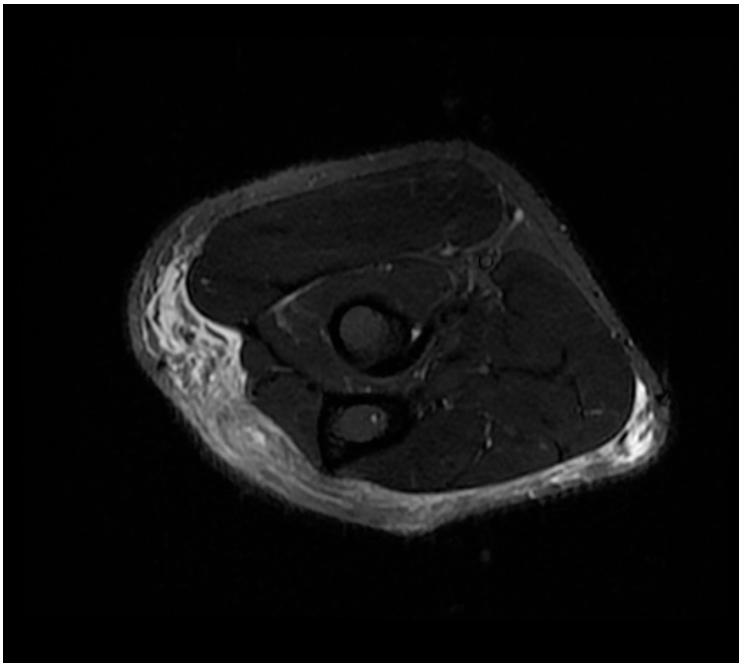


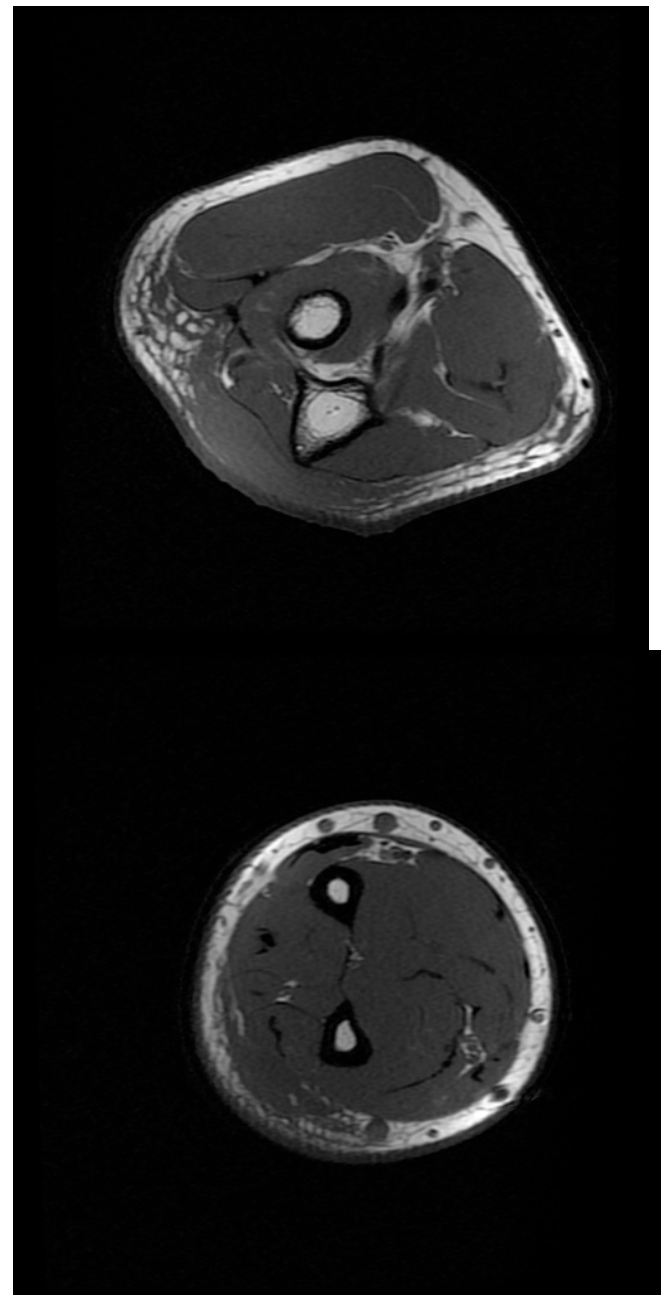
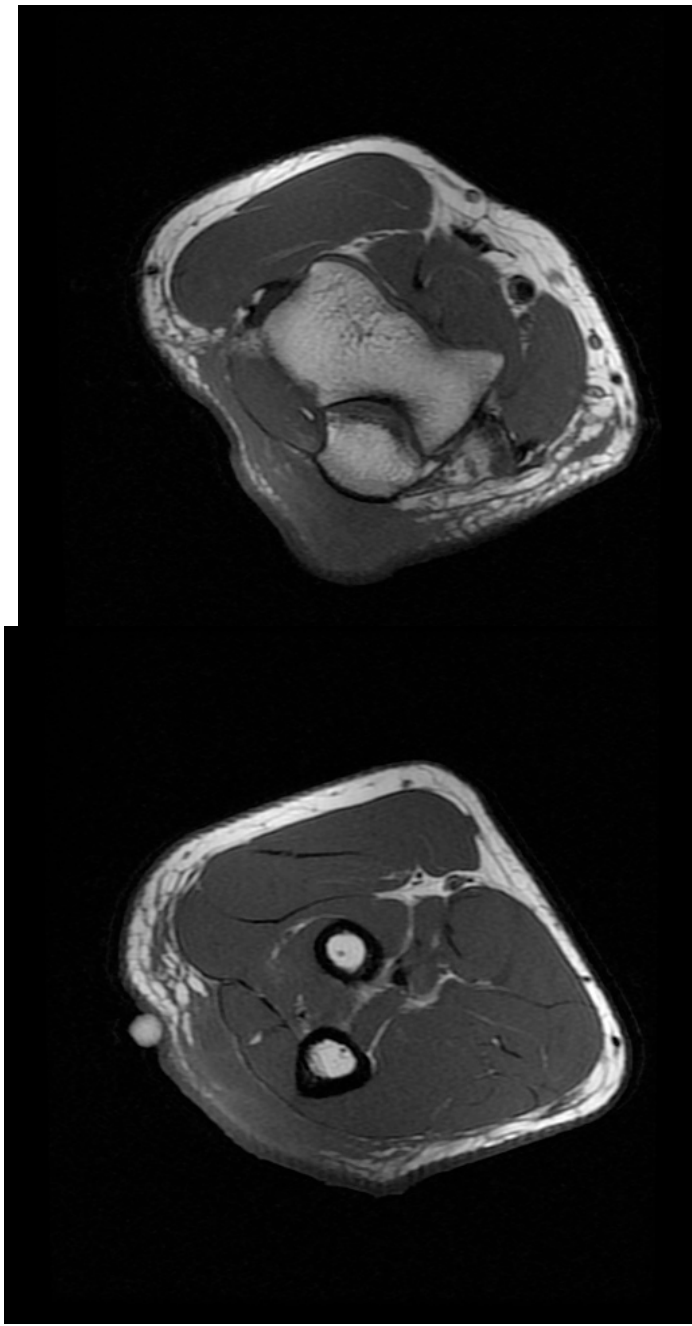
Young male forearm painful swelling since 1 week

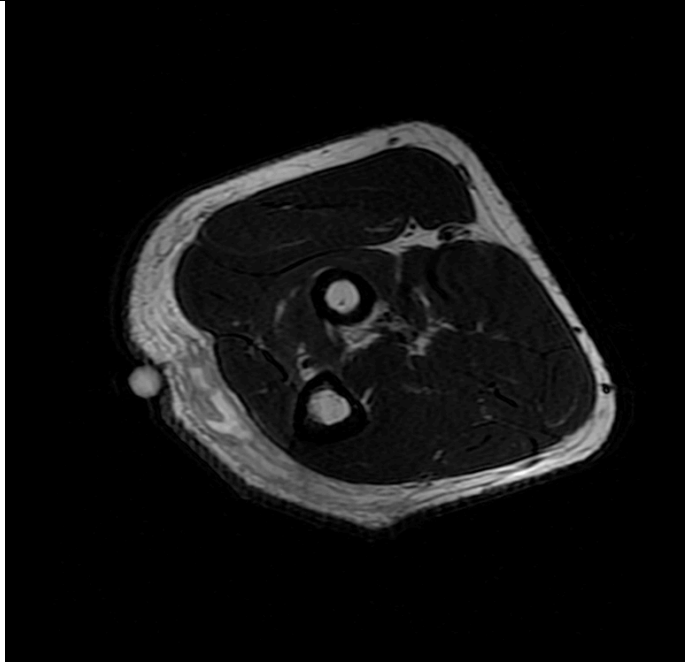
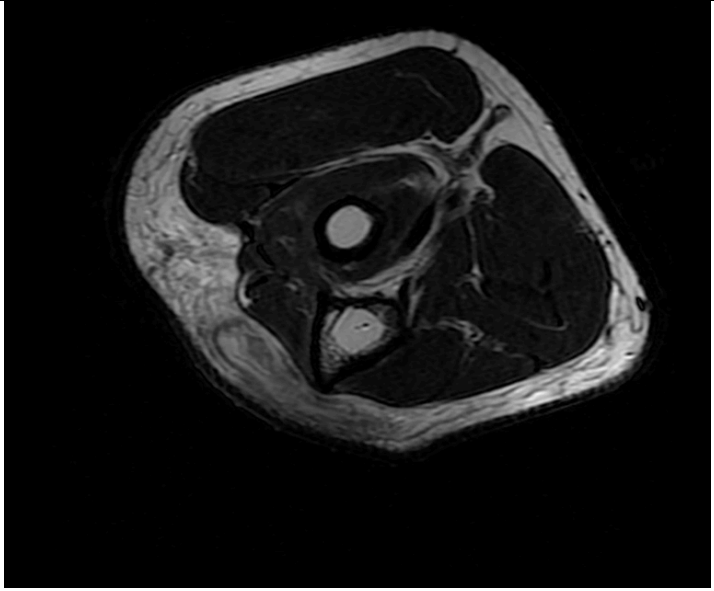
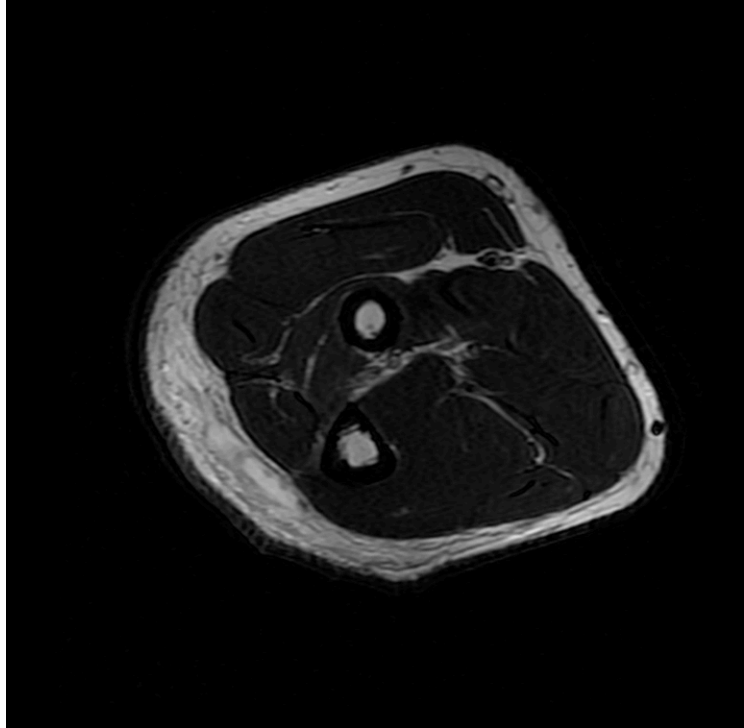
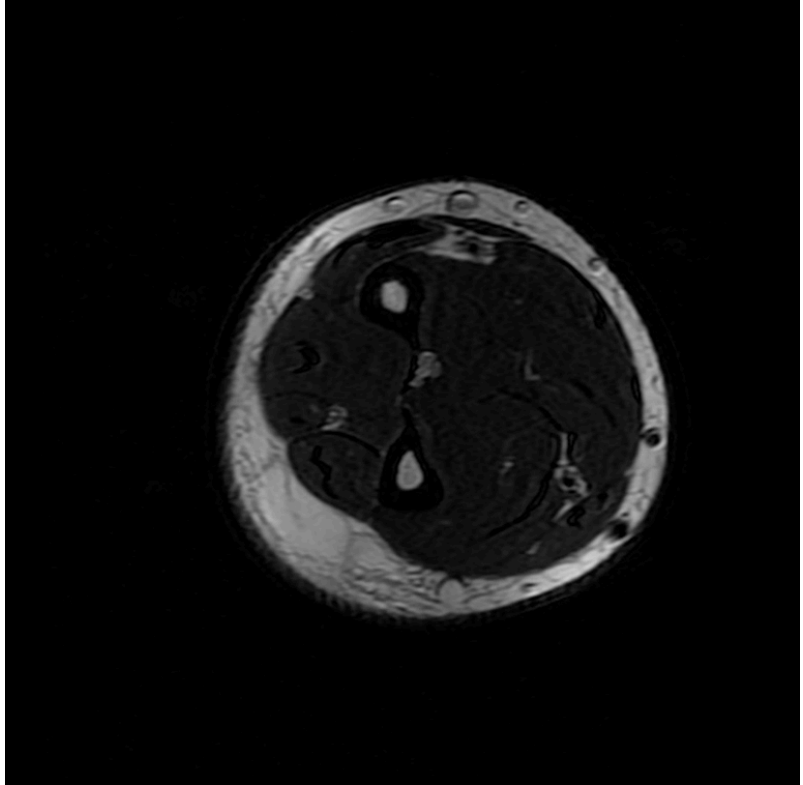
No trauma, fever, diabetes

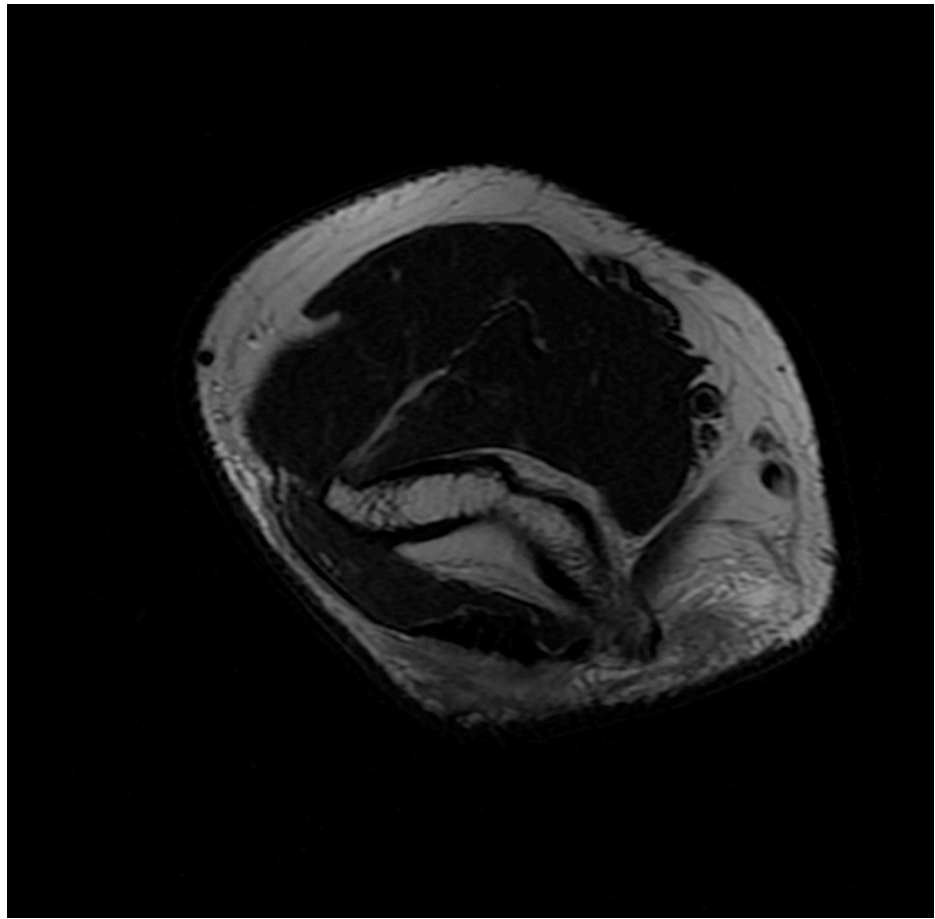
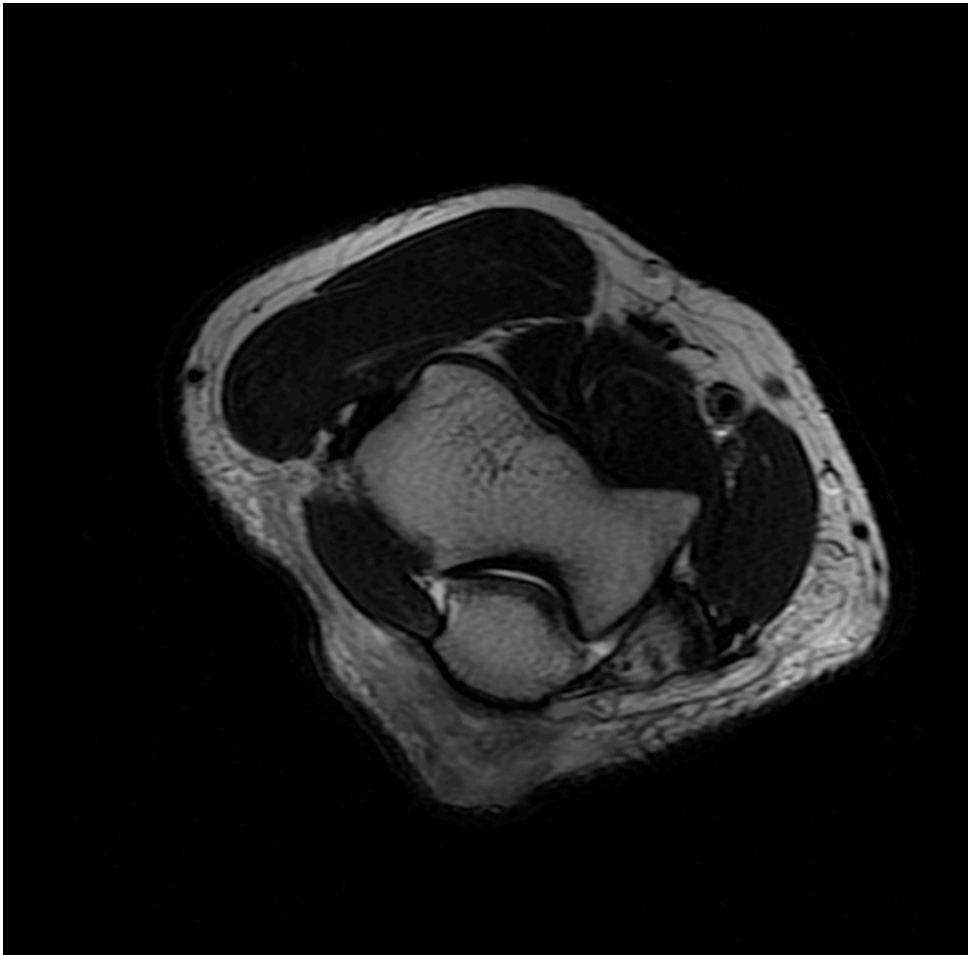
Thoughts/opinion

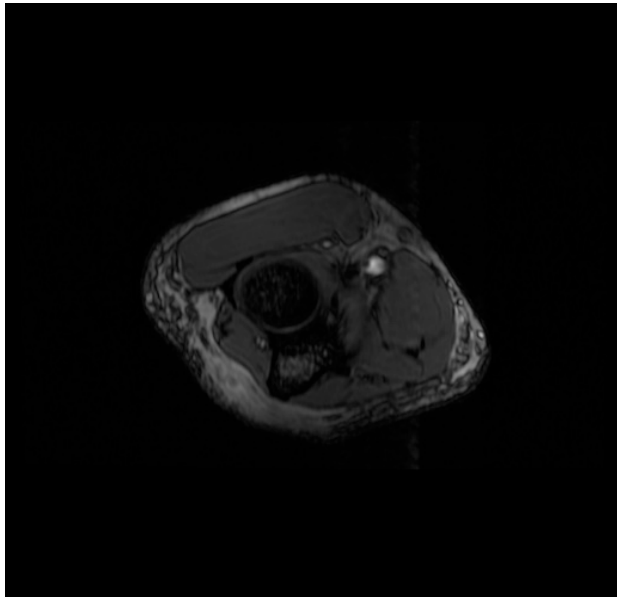
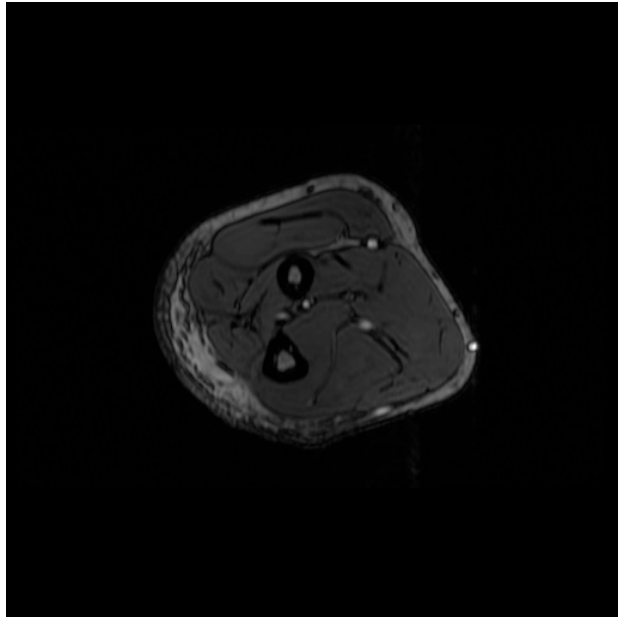
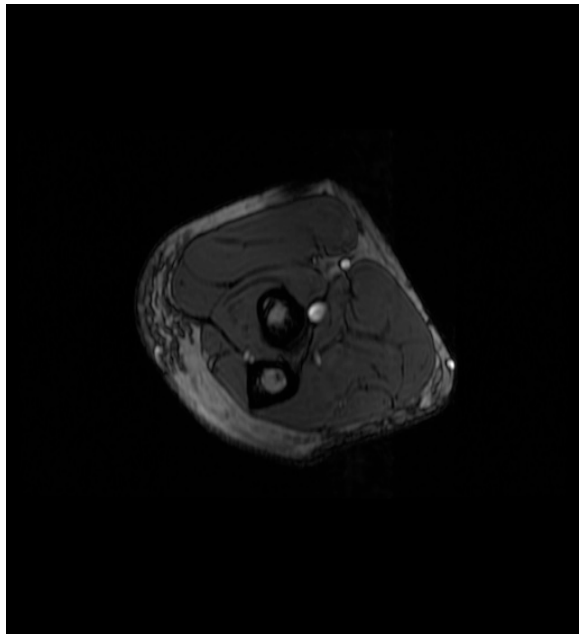
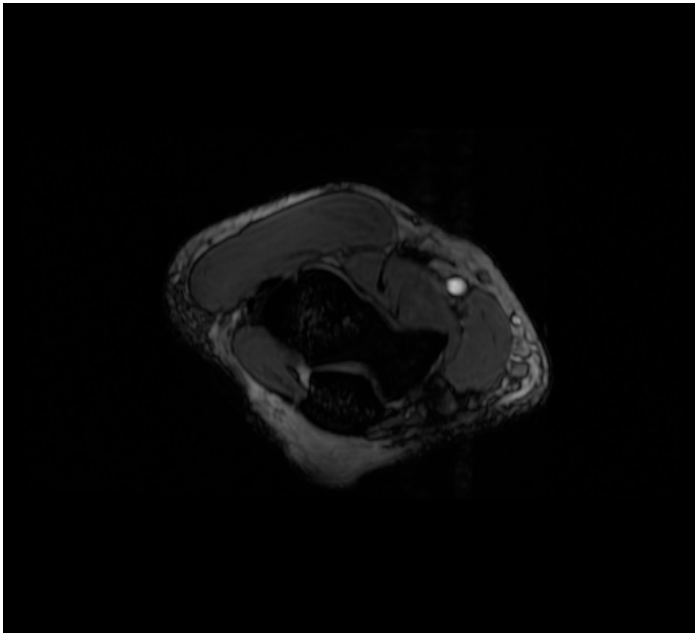


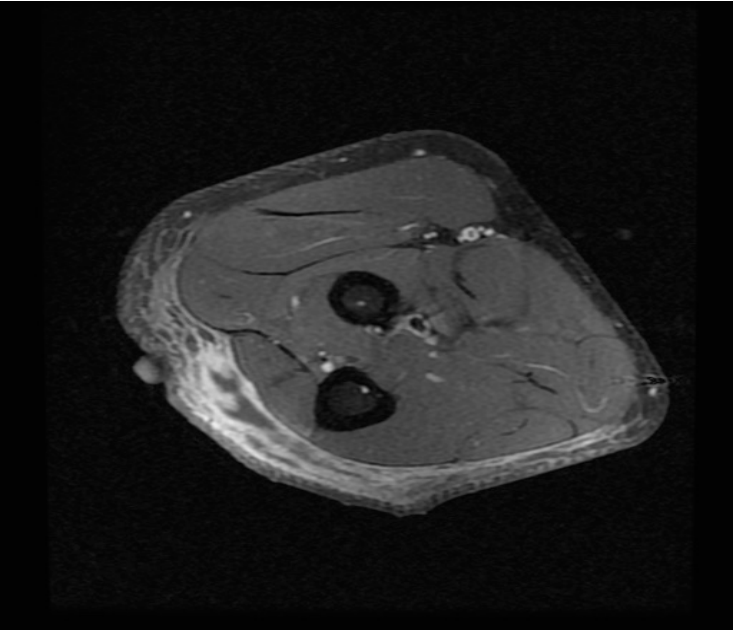
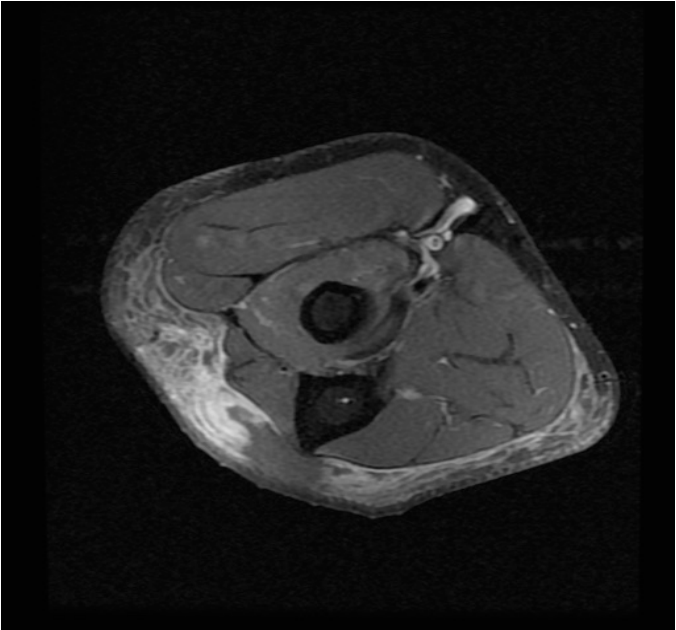
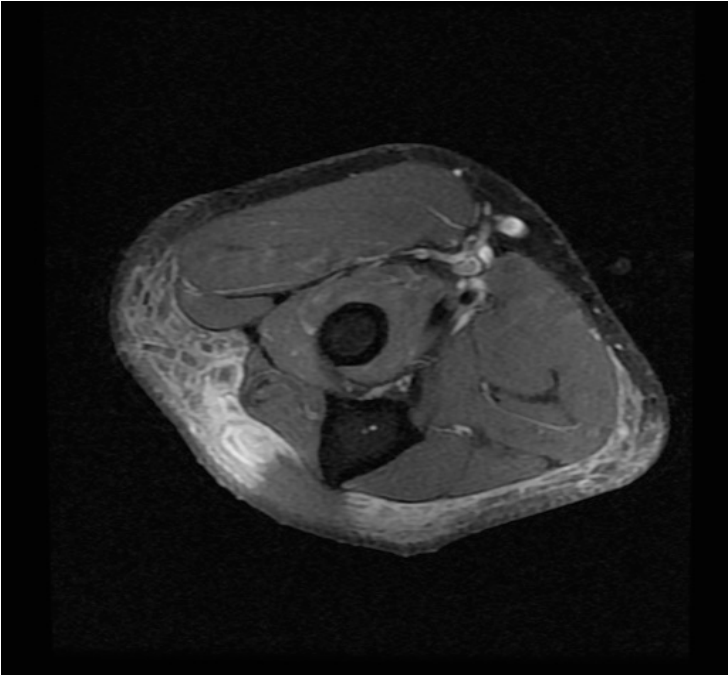
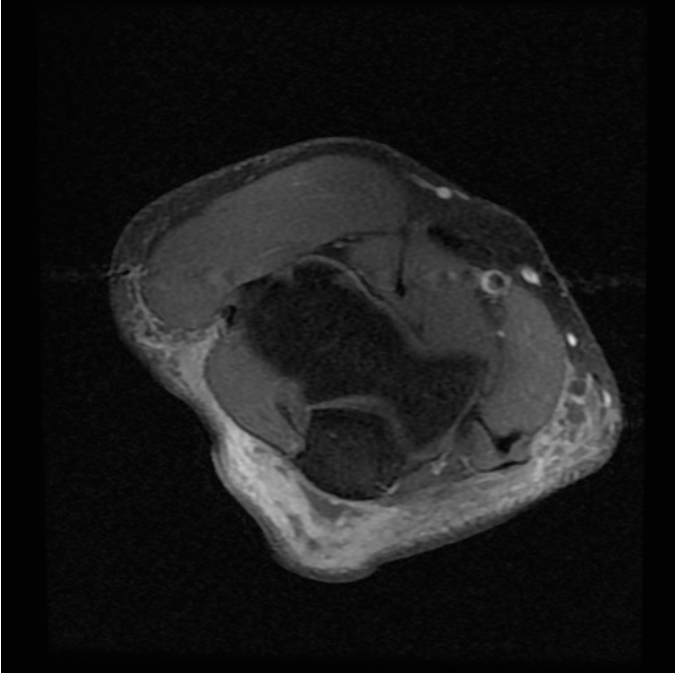


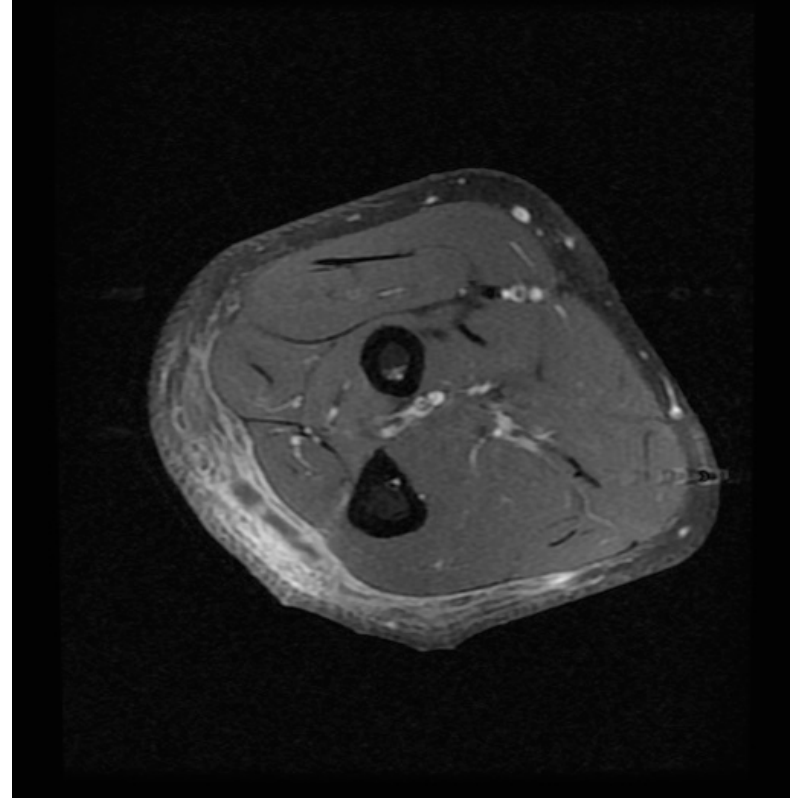
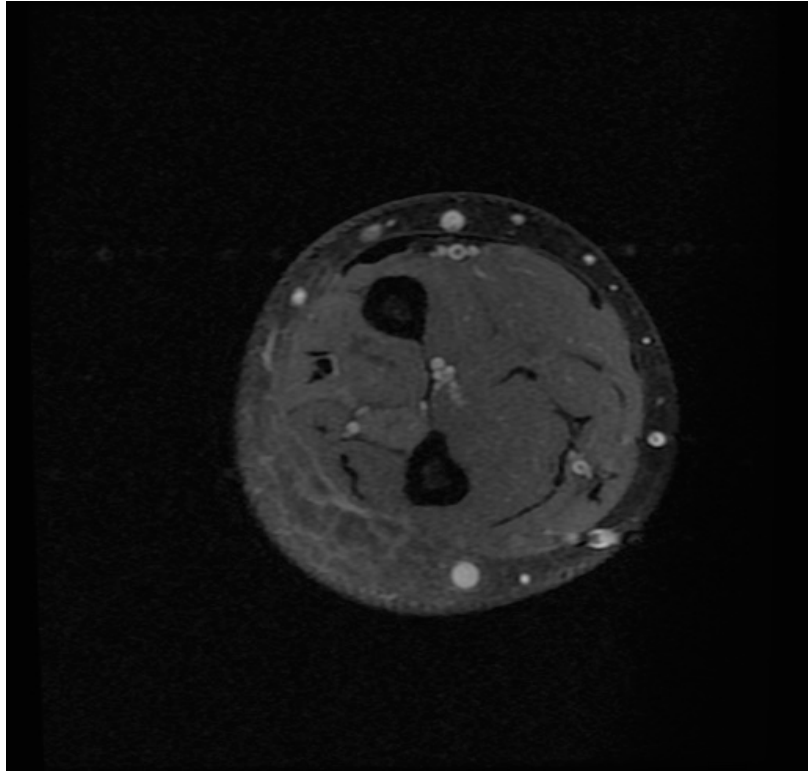


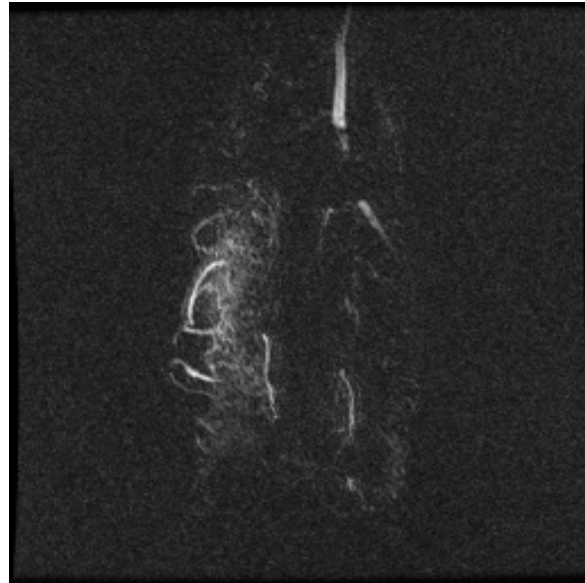
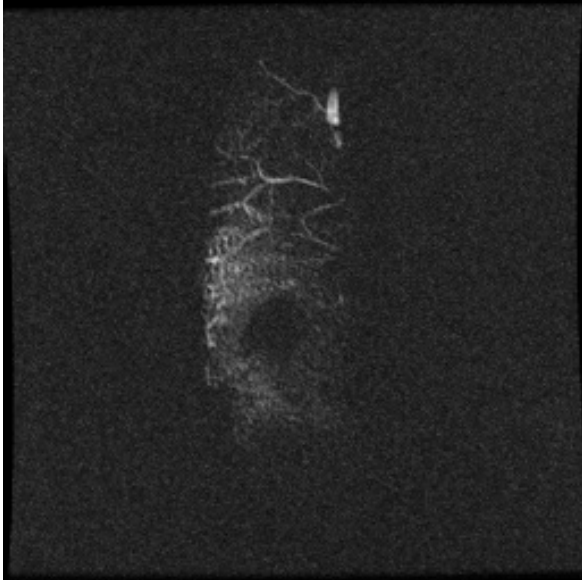
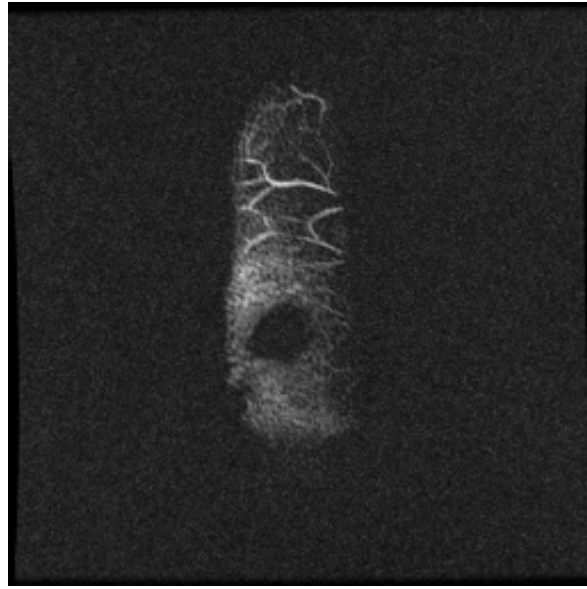
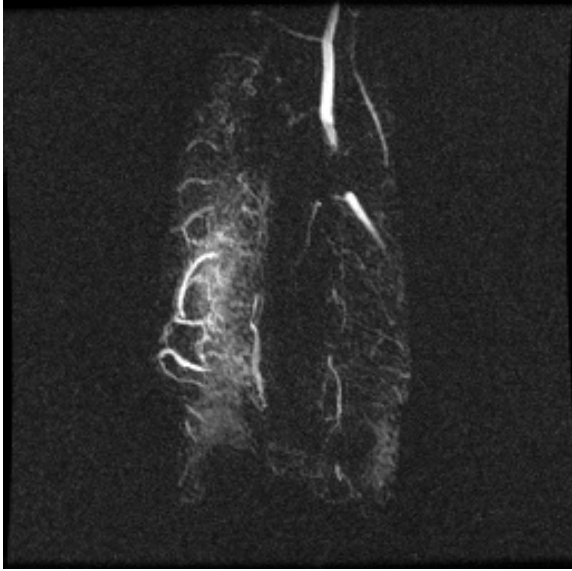


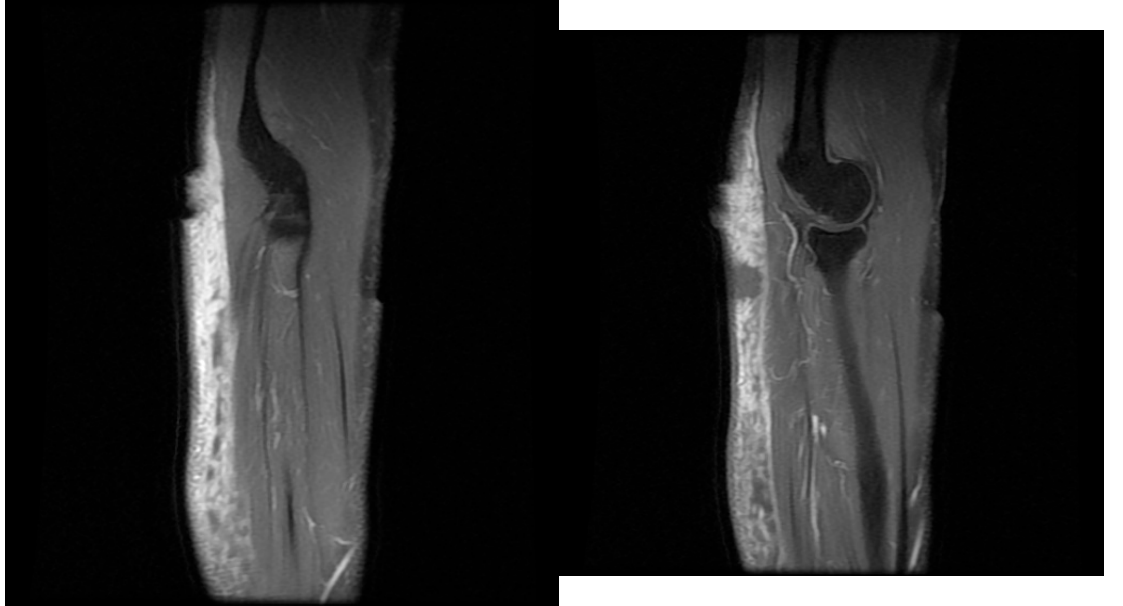
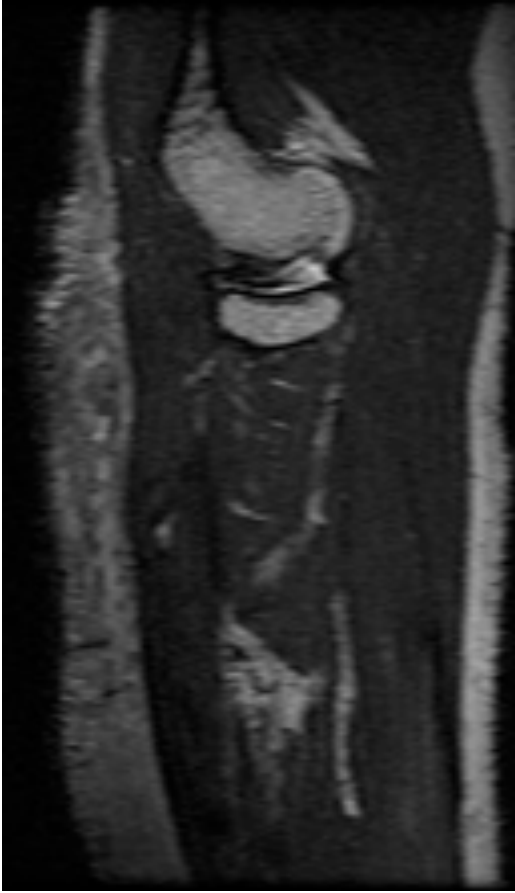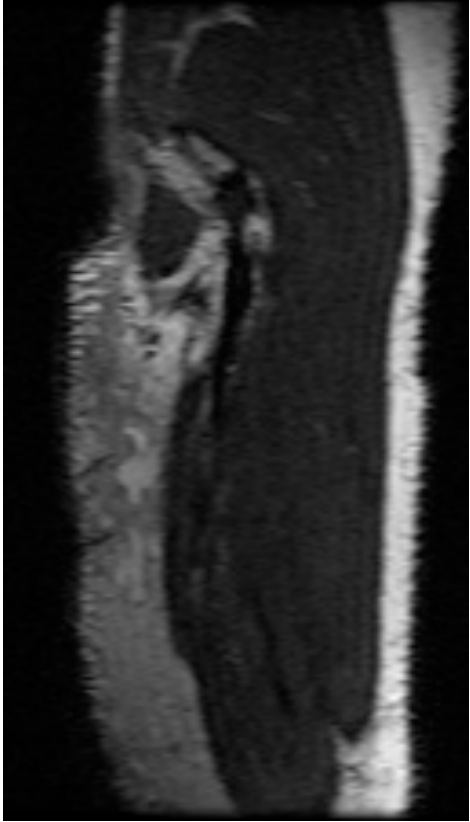


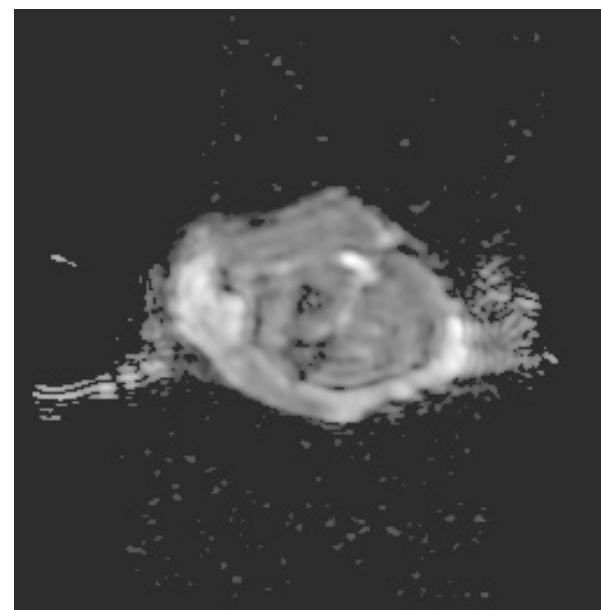
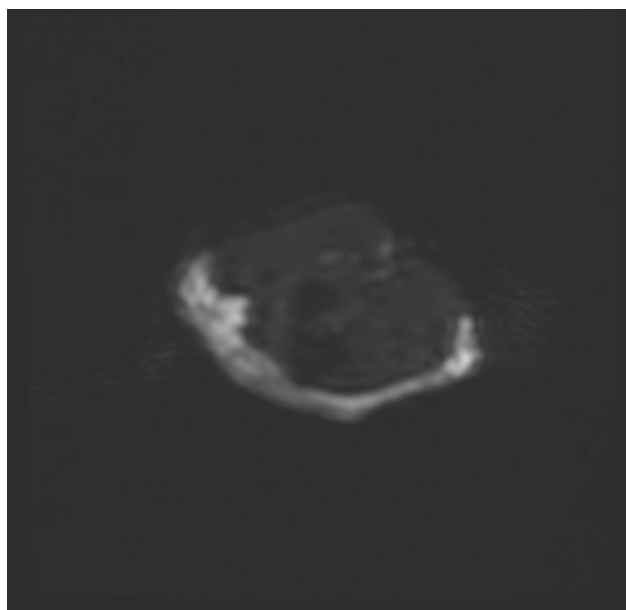
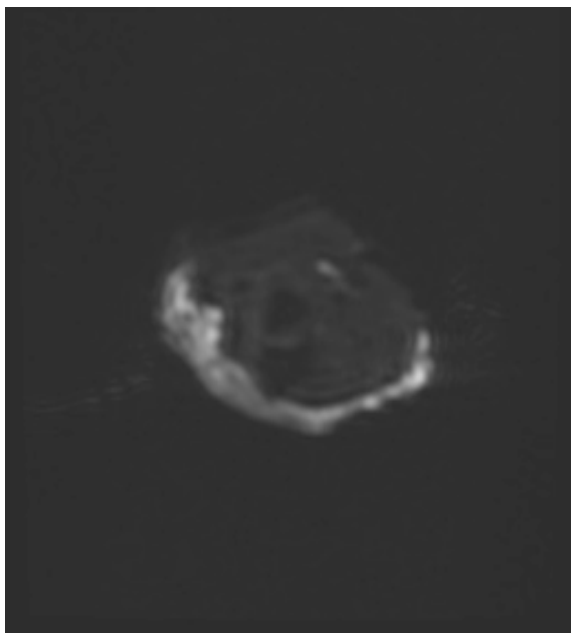












SIEMENS
18L6 HD
MSK
Gen
MI: 1.1
13fps
2D-- 100%
THI
H12.00 MHz
0dB / DR65
ASC 3
DTCE M
MapE / ST3
C-- 100%
CDV
6.25MHz
3dB Gen
PRF 1220
MapA / F2

