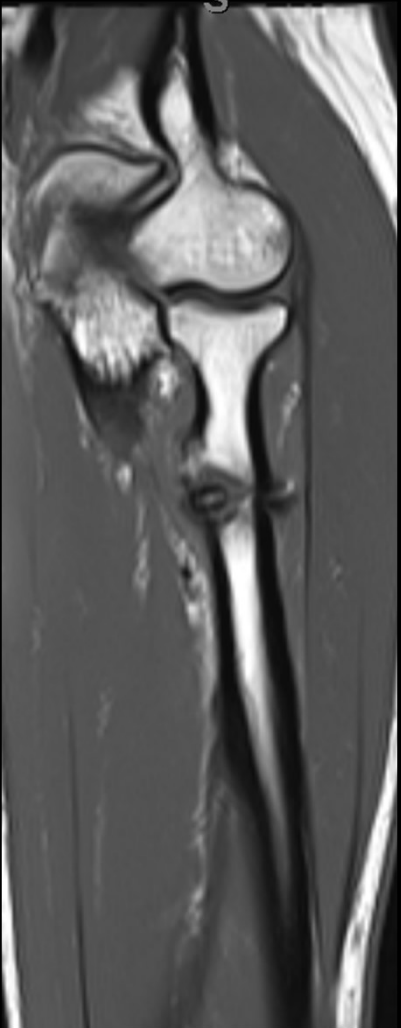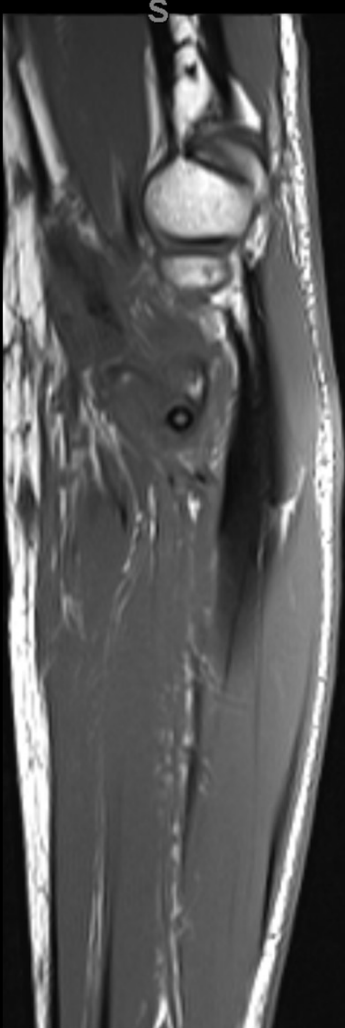


- 57 year old male (profession: butcher)
- failed re-insertion of the distal biceps tendon
- PIN (posterior interosseous nerve) damage at the site of the anchor after surgery
- no X-ray available

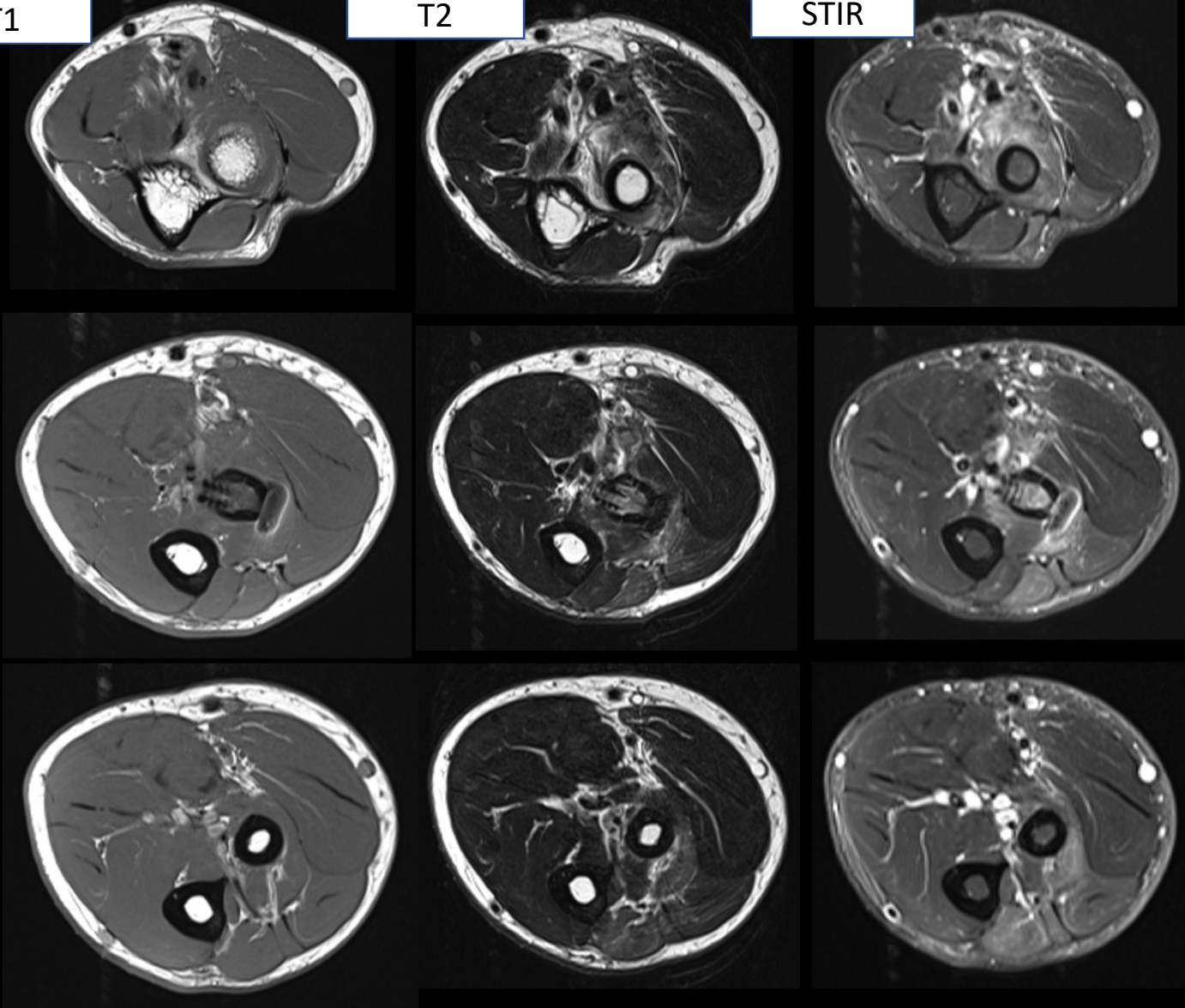
T1



T1



T2



STIR