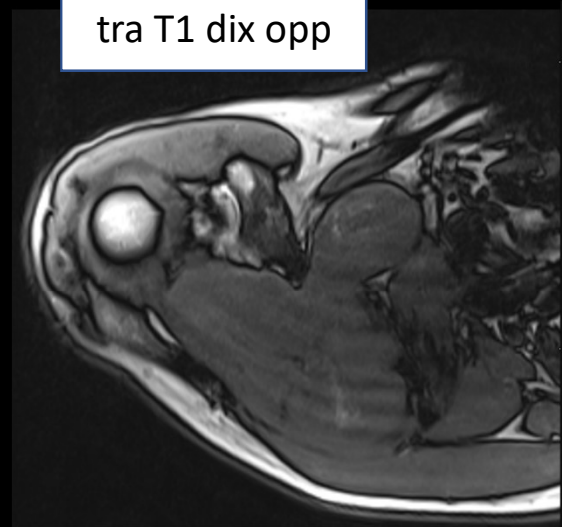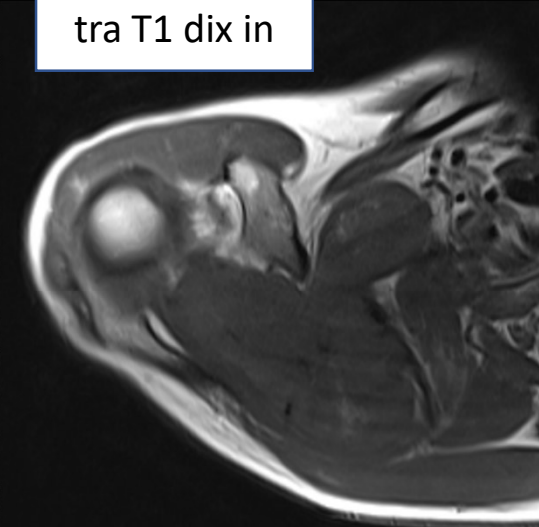


- 52 year old male
- swelling around right shoulder, growing since 2 years
- no pain
- Solid, enhancing mass with no necrosis, prominent vascularisation in US, without matrix mineralisation, transosseous growth from supraspinatus fossa to subscapularis fossa
- Differential diagnosis?

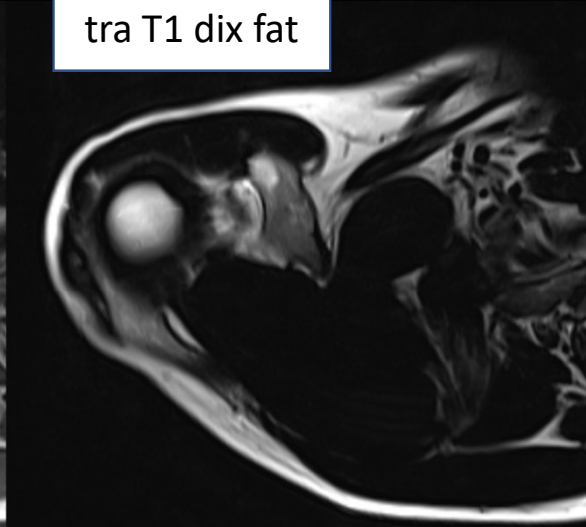
tra T1 dix opp



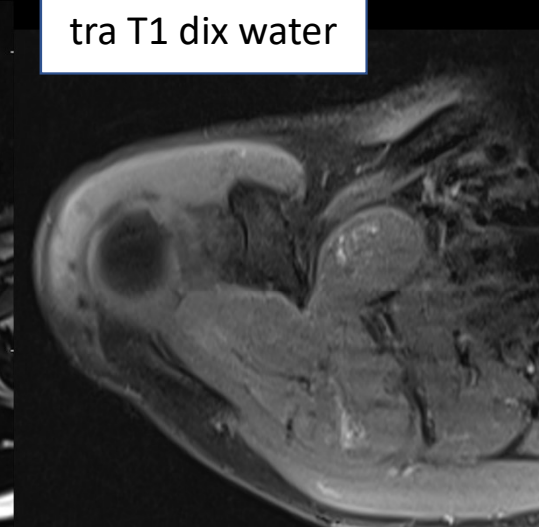tra T1 dix in



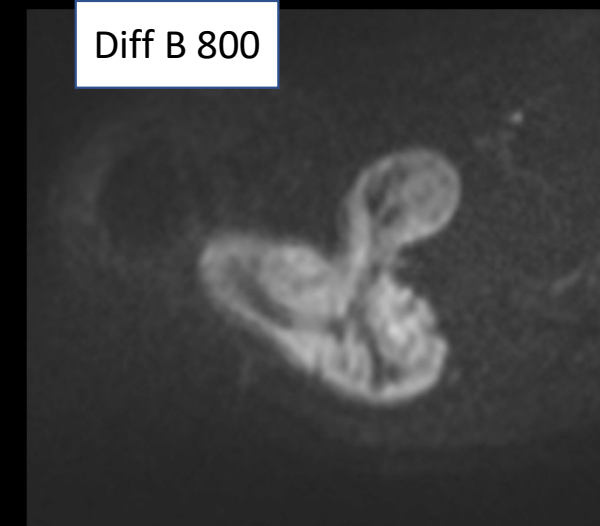
tra T1 dix fat



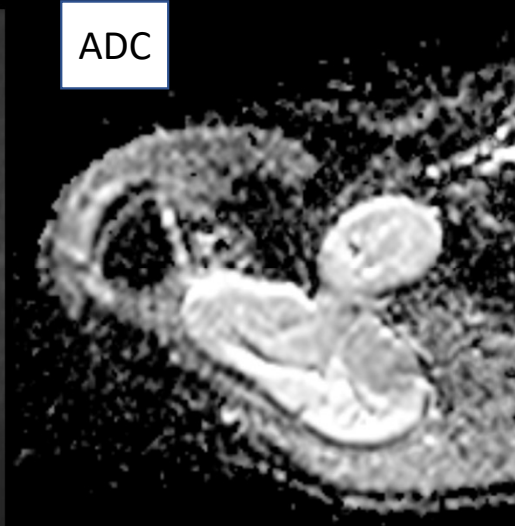
tra T1 dix water



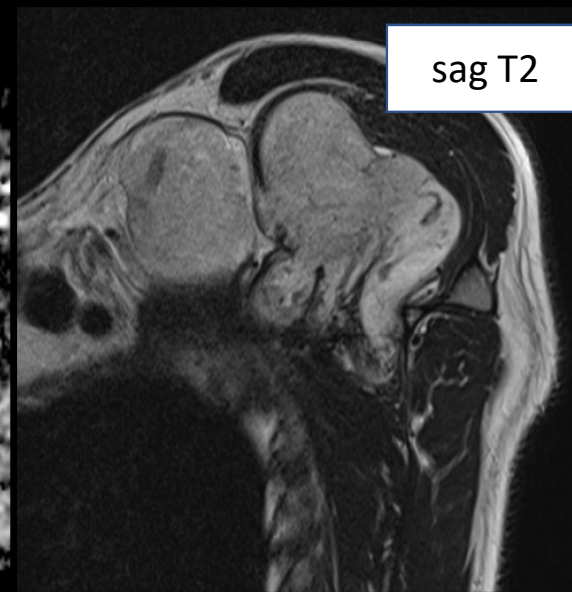
Diff B 800



ADC



sag T2



tra T1 dix water + C

