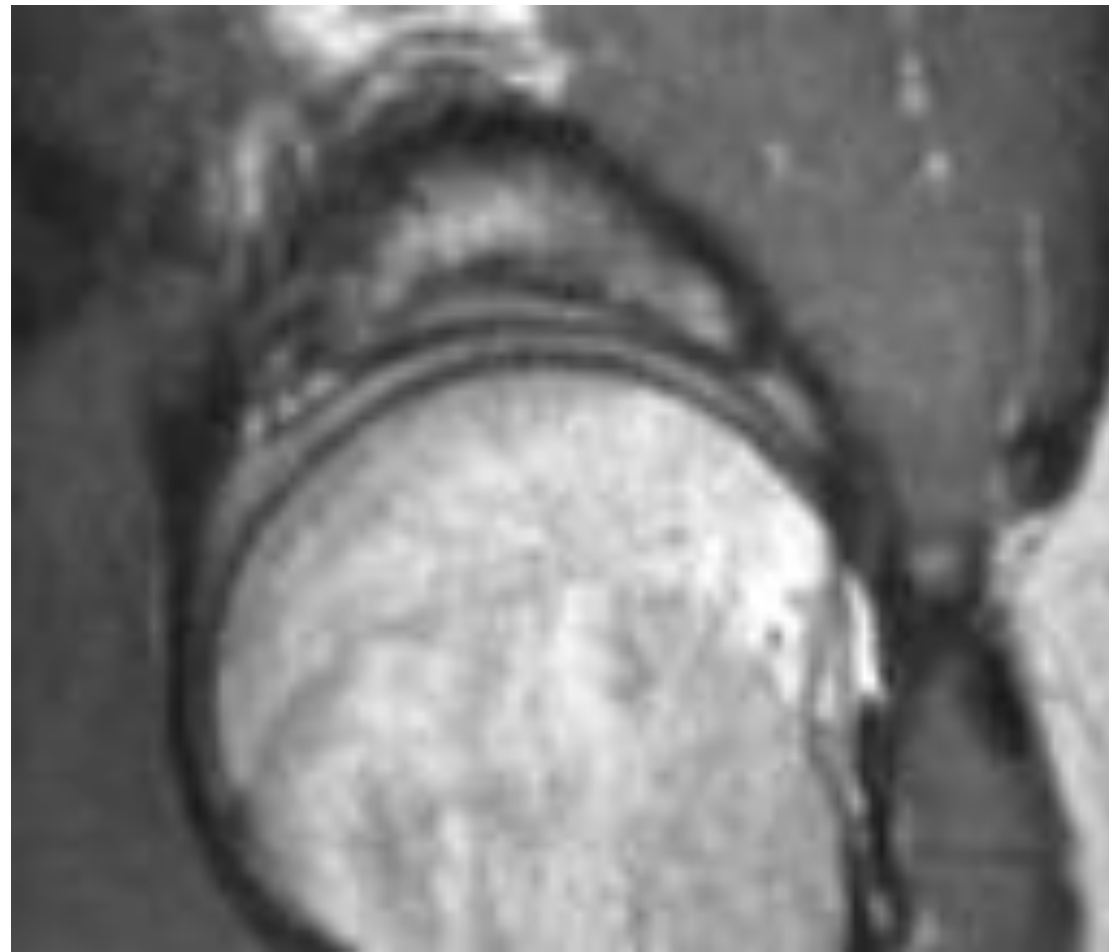
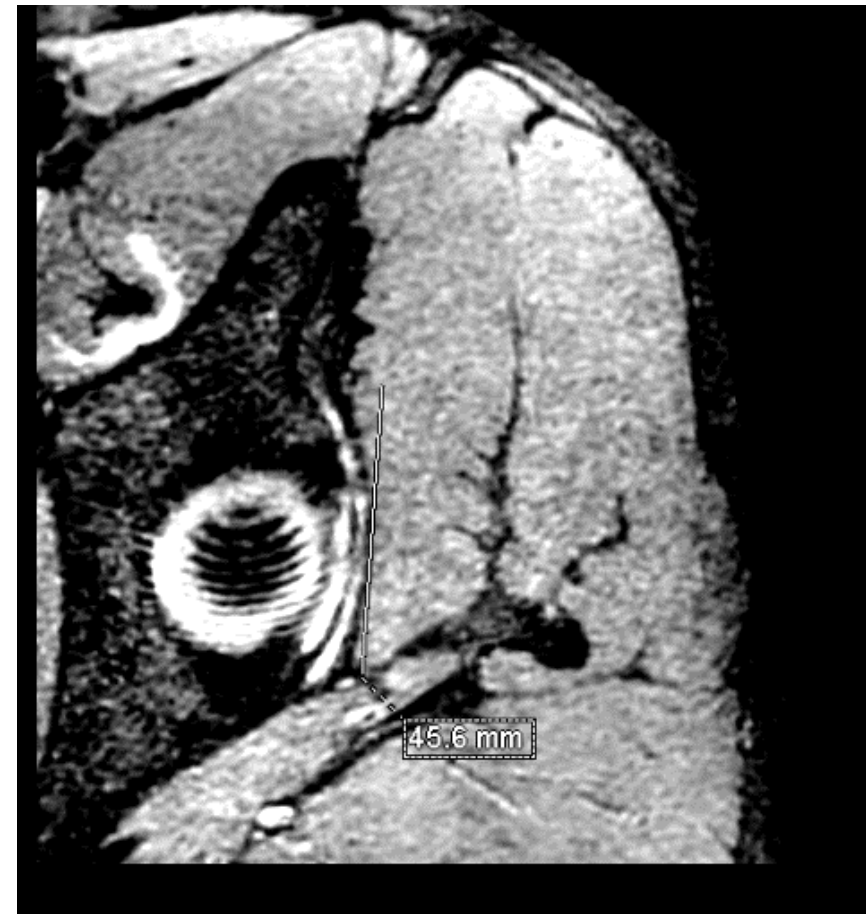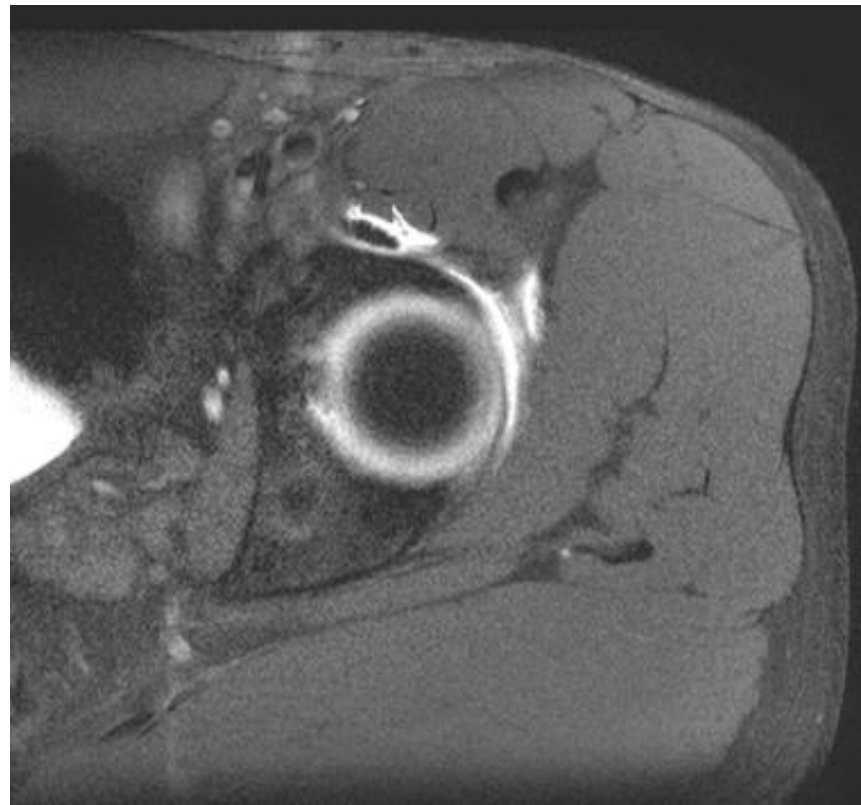

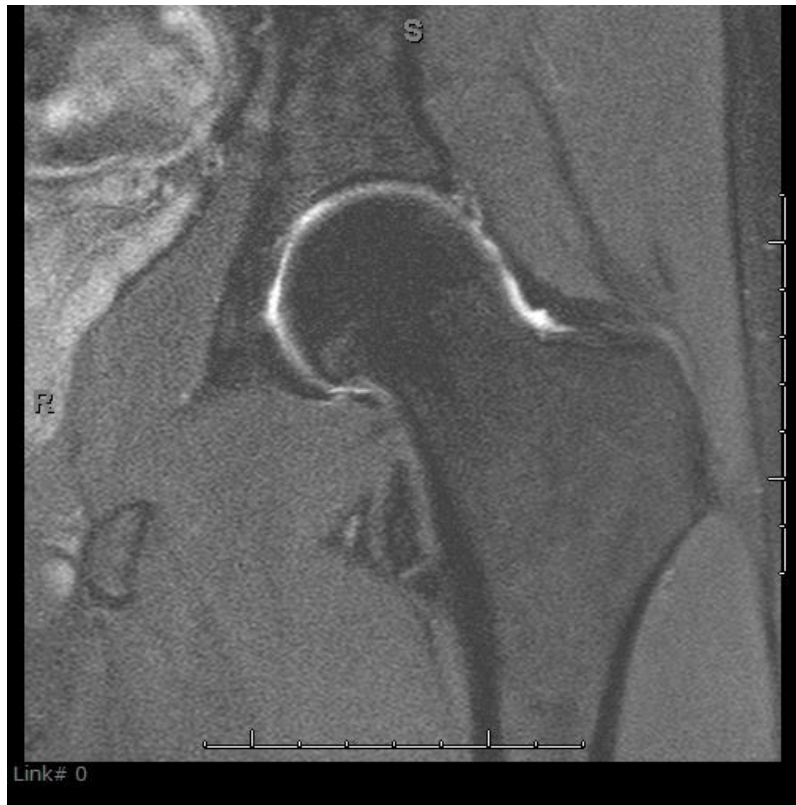
Some 3D hip MRI examples
for y'all

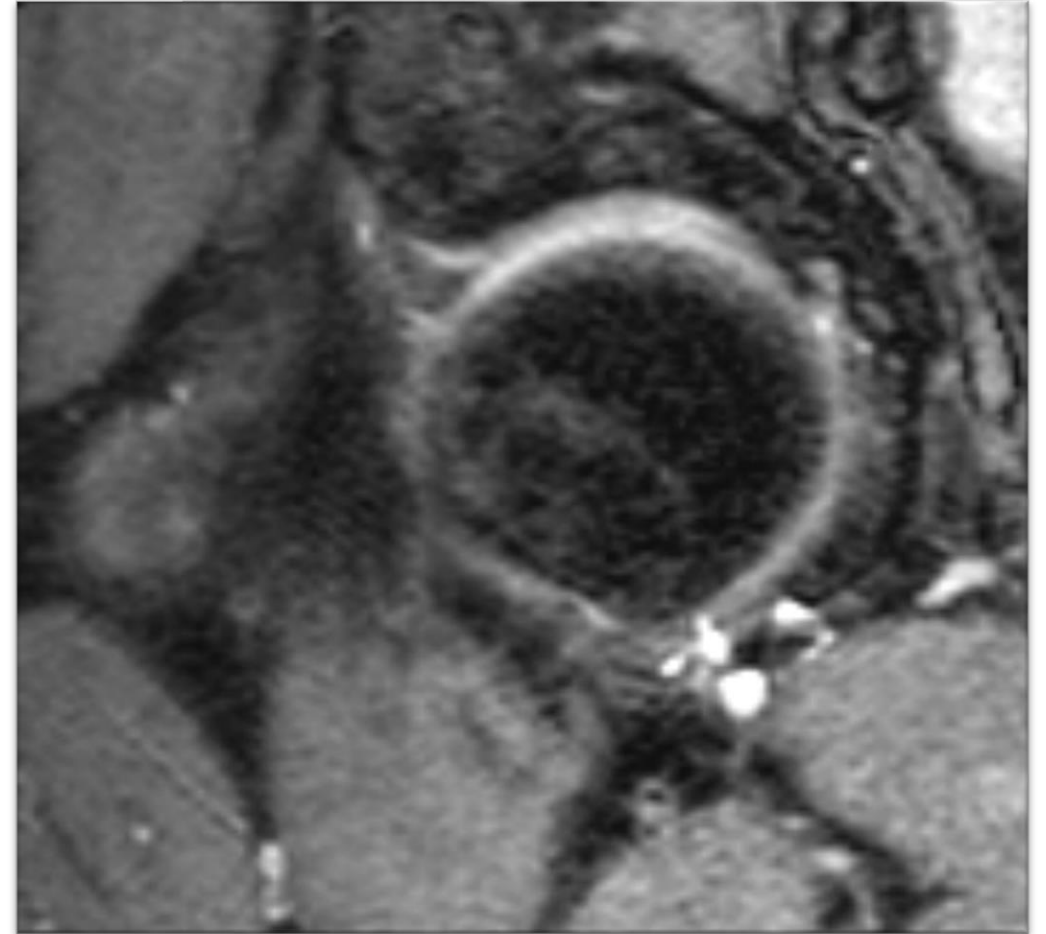
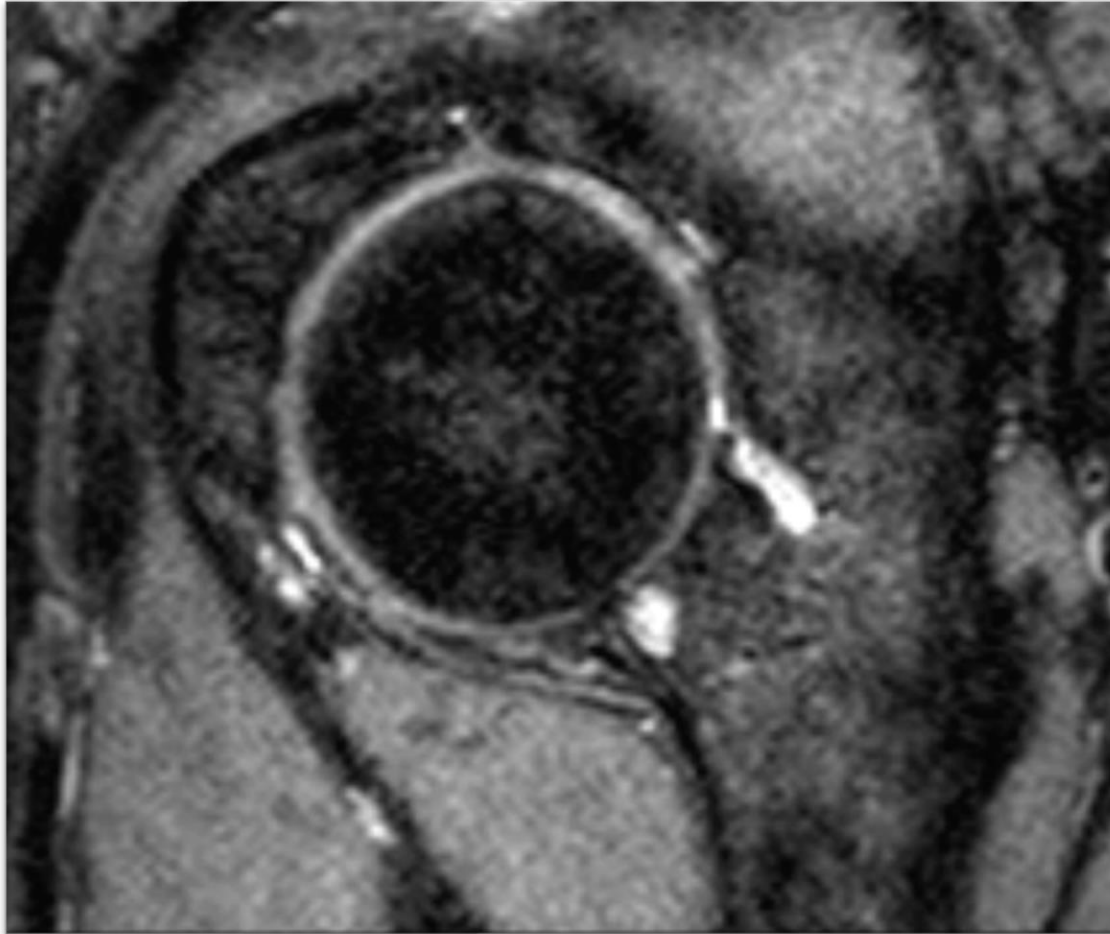
See microcysts in labrum- did you ever see them on 2D?



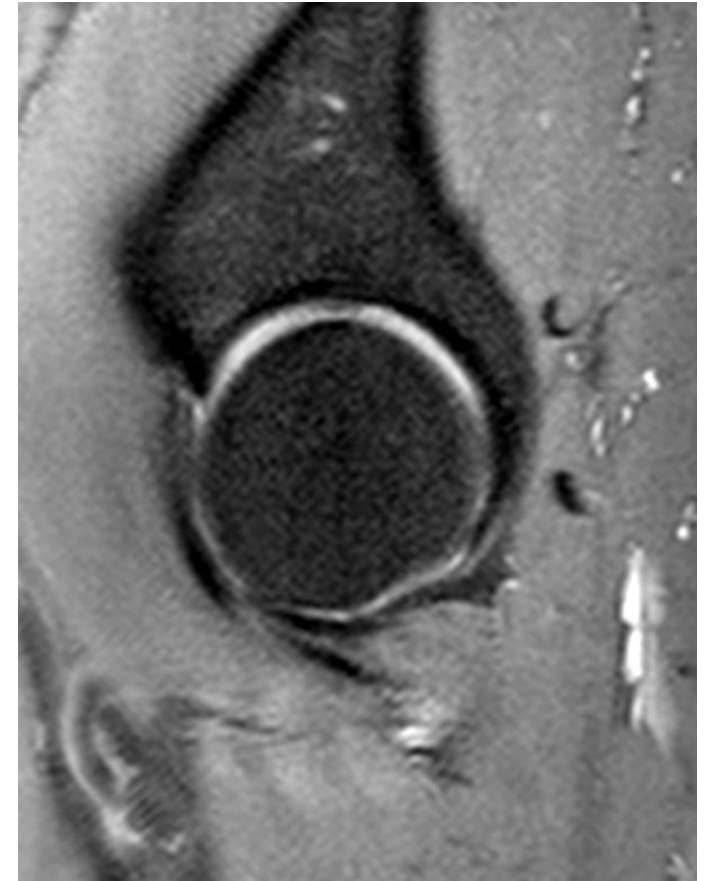
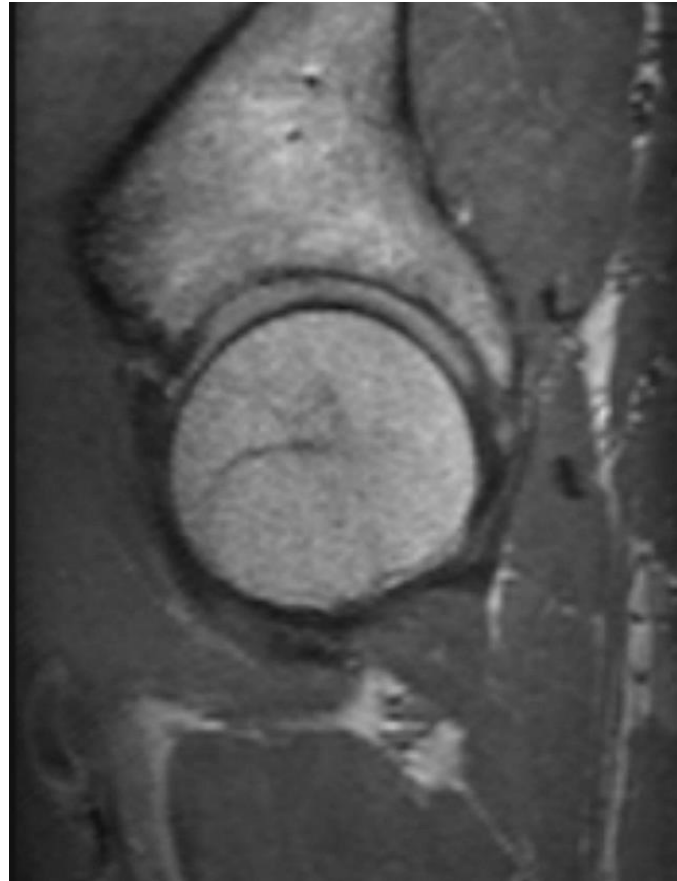
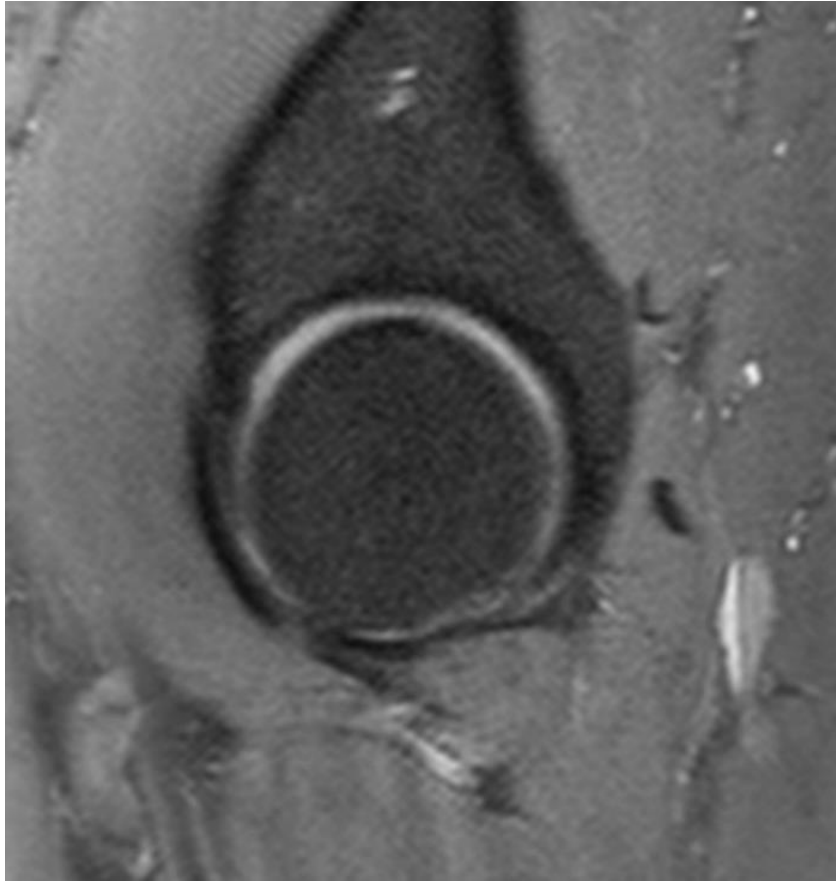
MRA- right cor and ax, 3D – left- you can measure this bucket handle tear



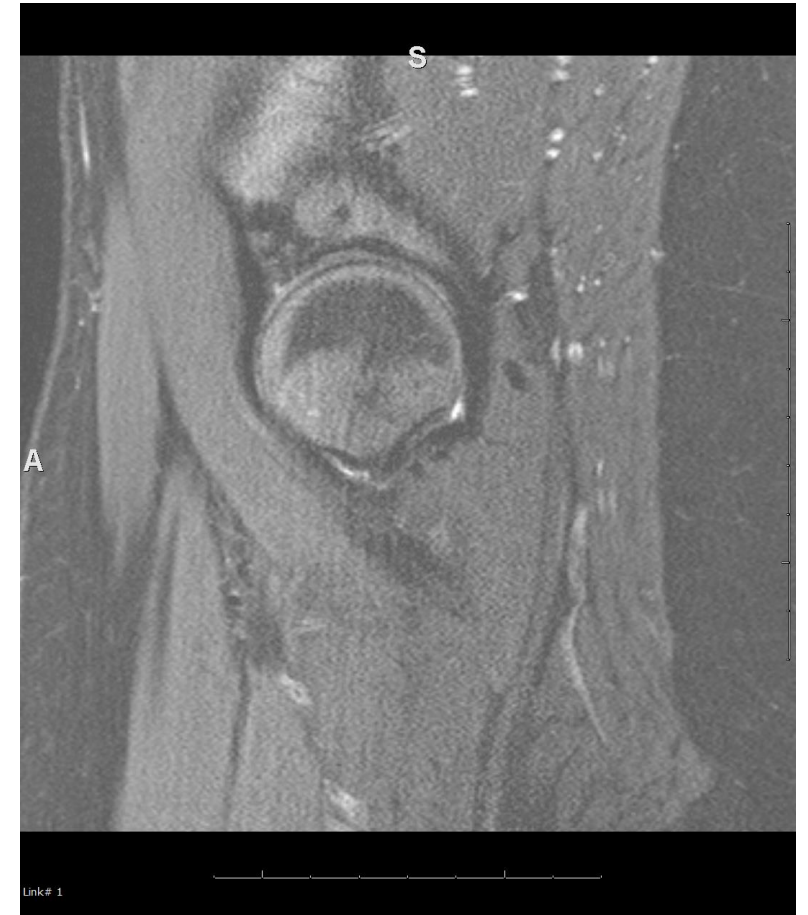
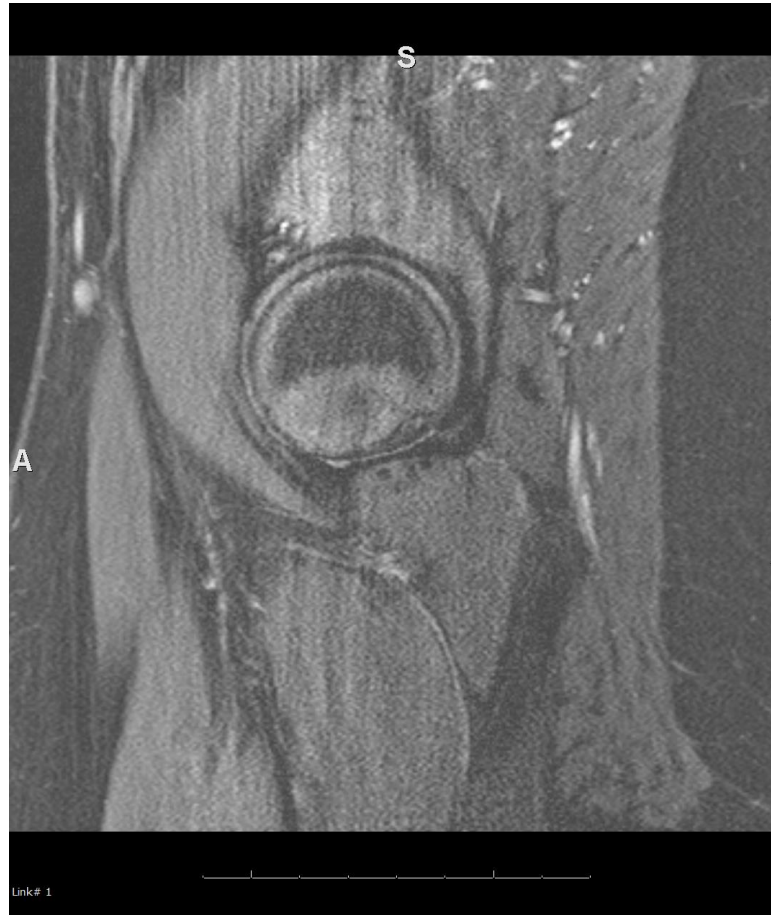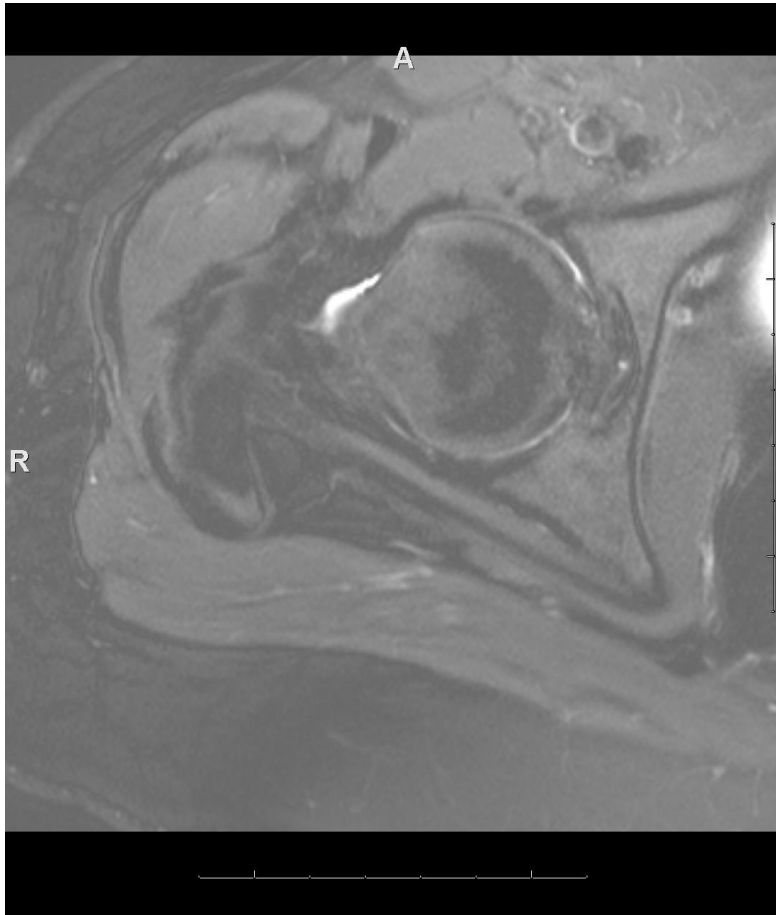
Multifocal tears on 3D



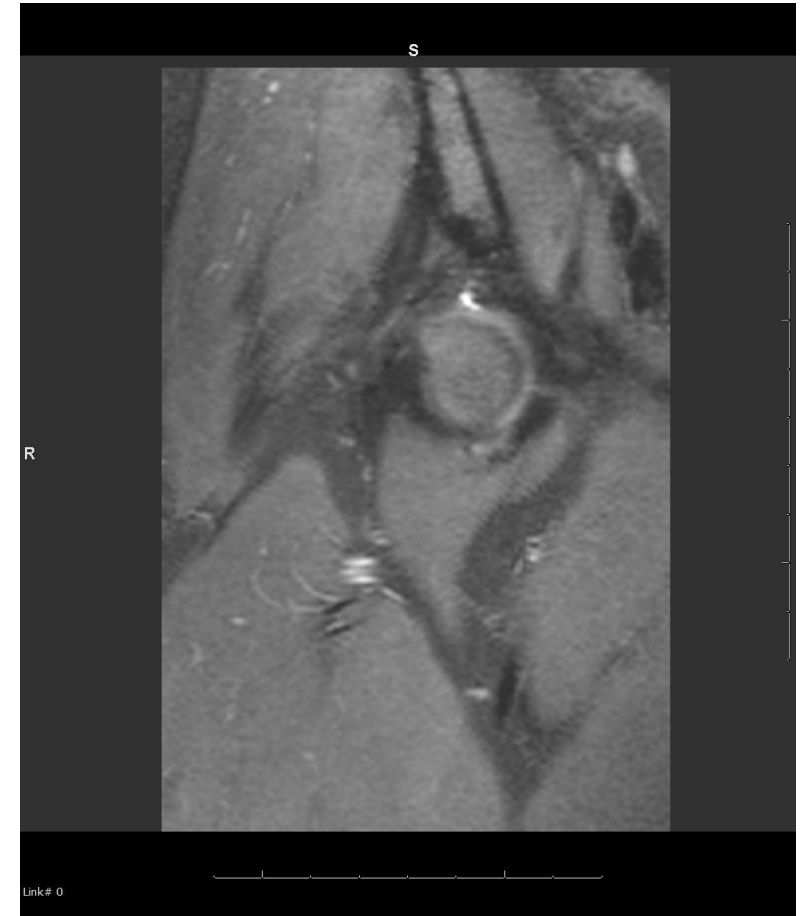
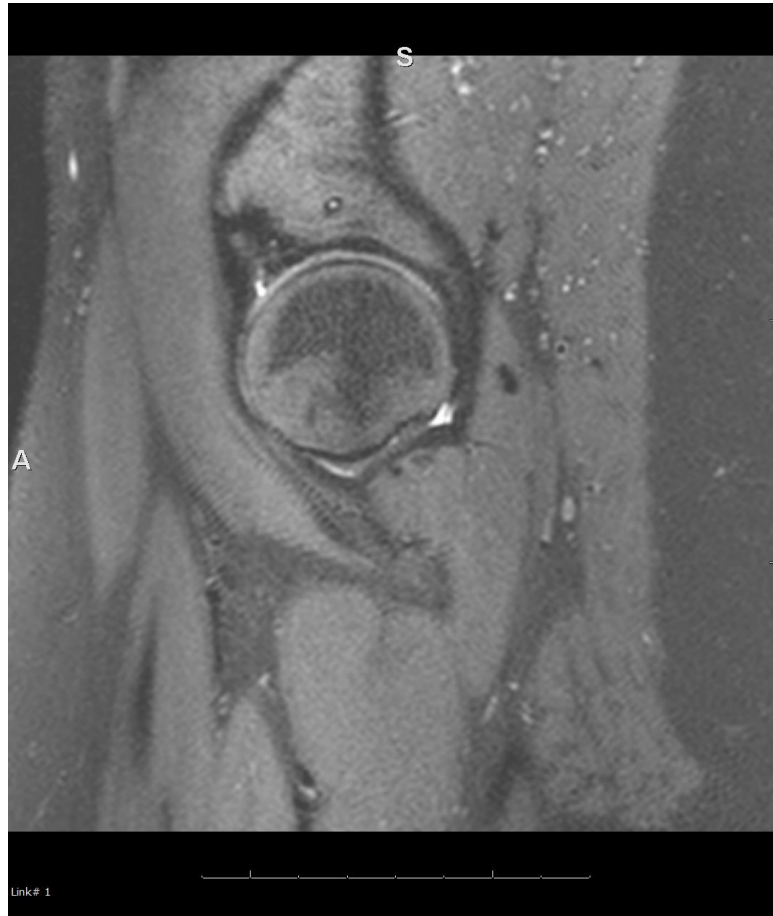
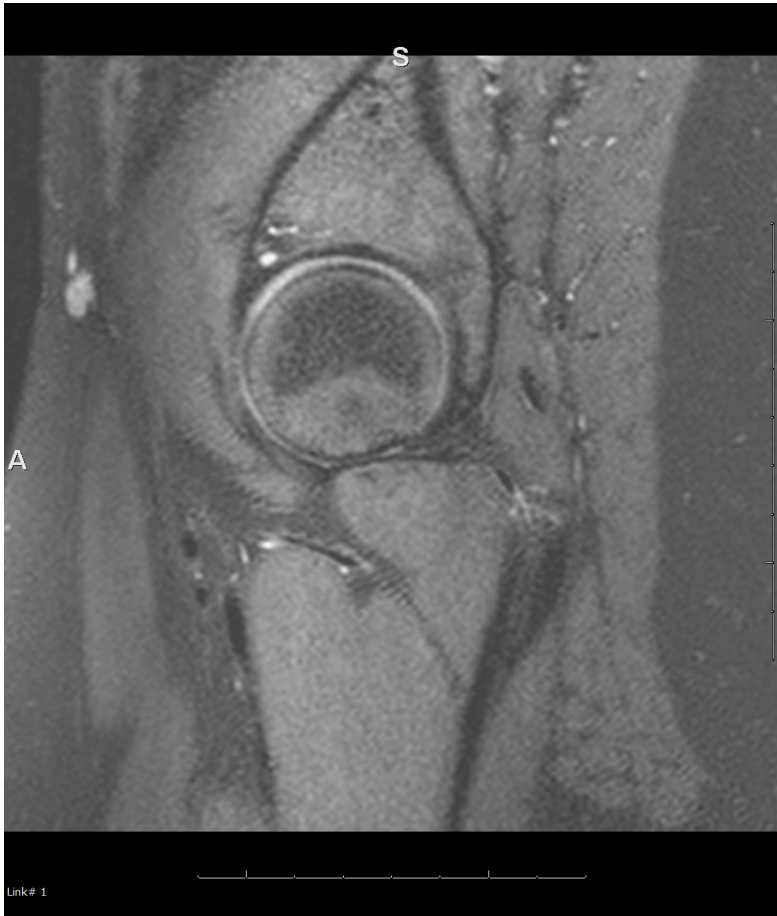
2D (right) and 3D (left two images)- which one shows tear



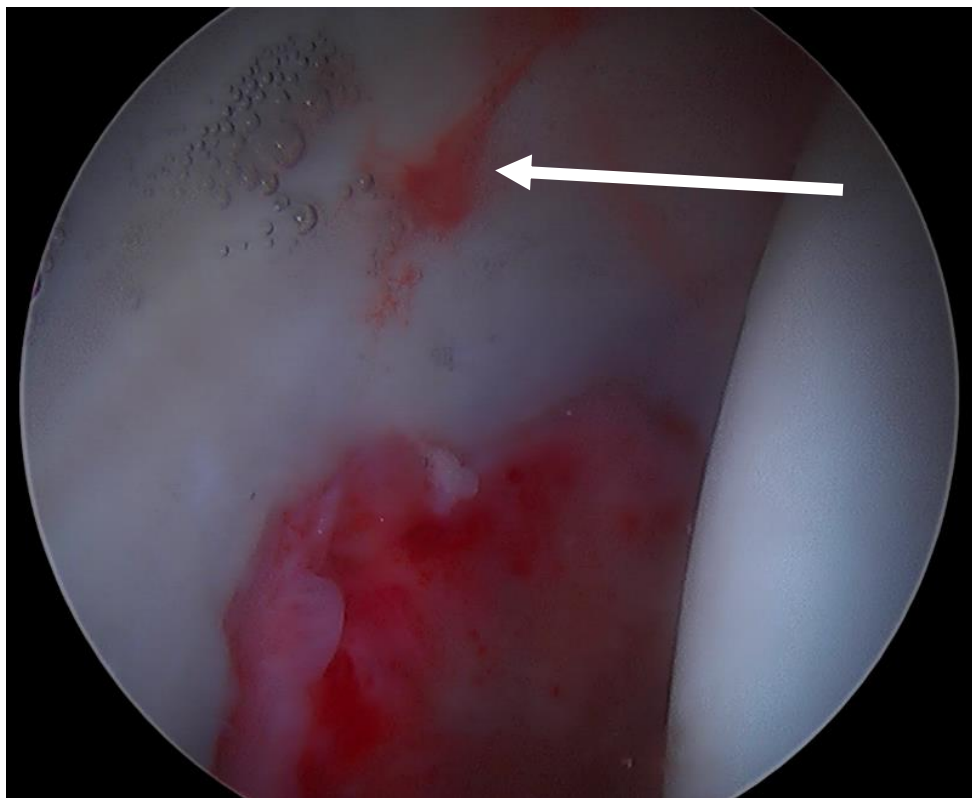
Young female with HD- had cam resection-
persistent s/s- 2Ds non MRA as we stopped MRAs



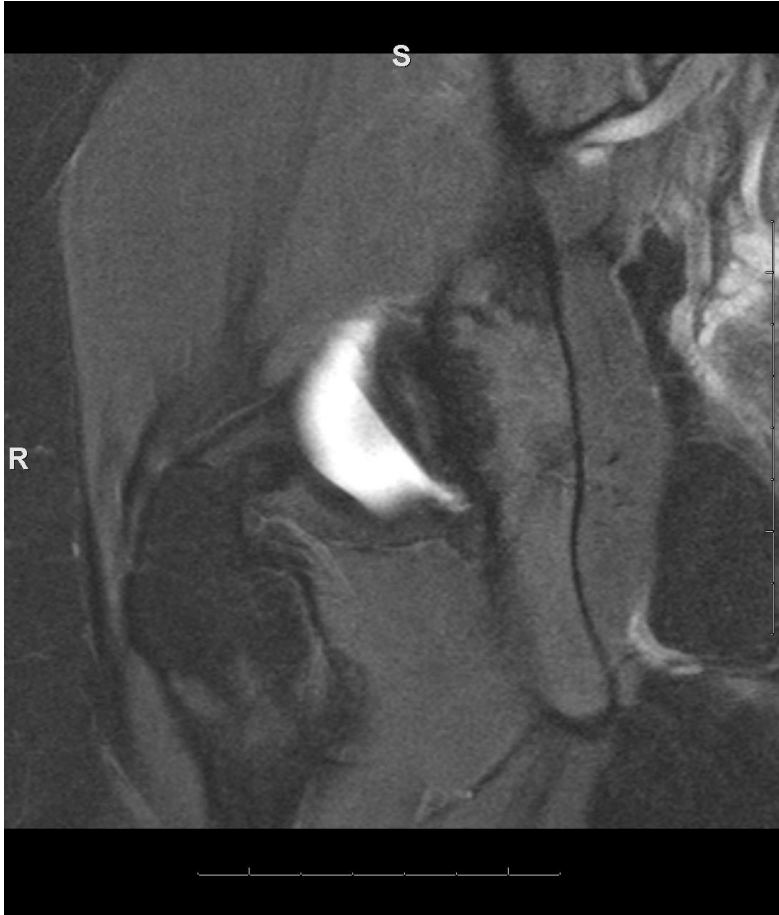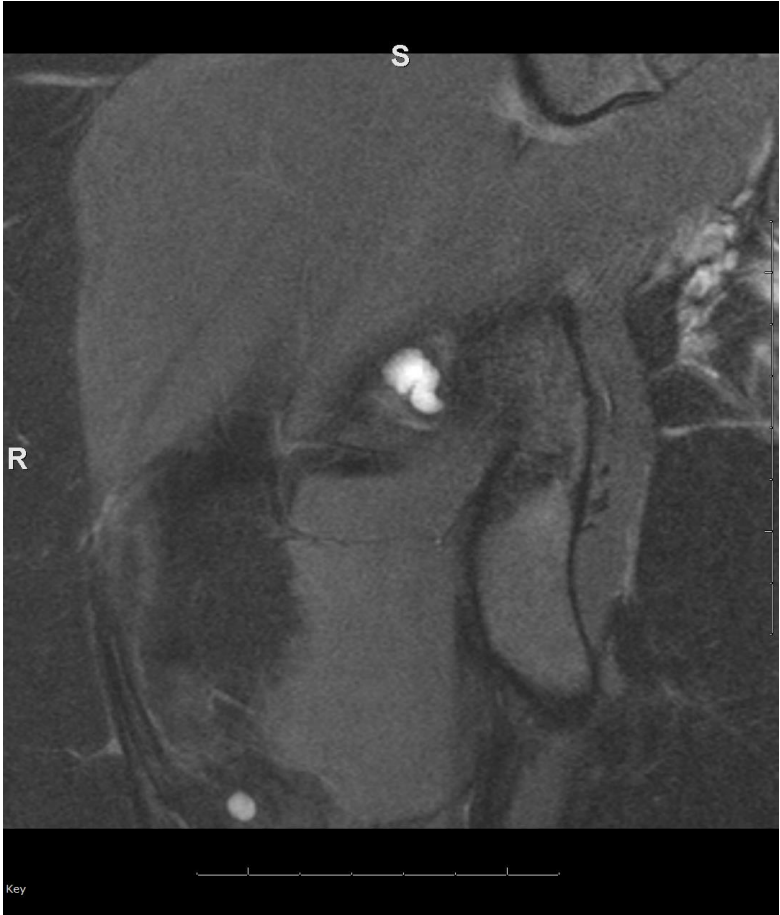3Ds- labral repair ok- see more ant- chondrolab fissure- only seen on 3D and recon



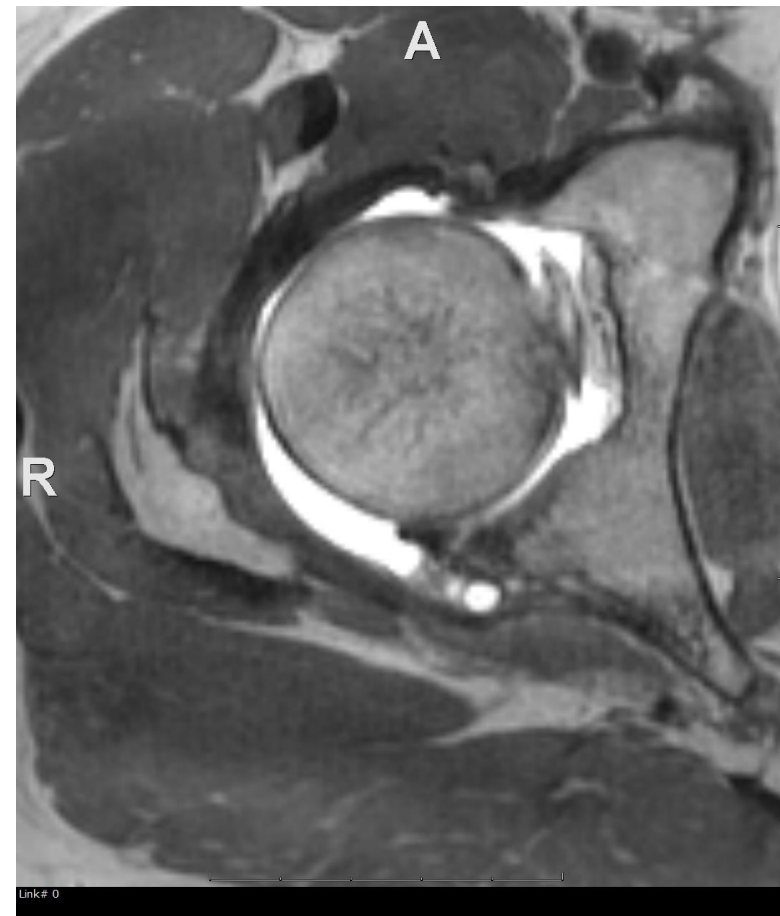
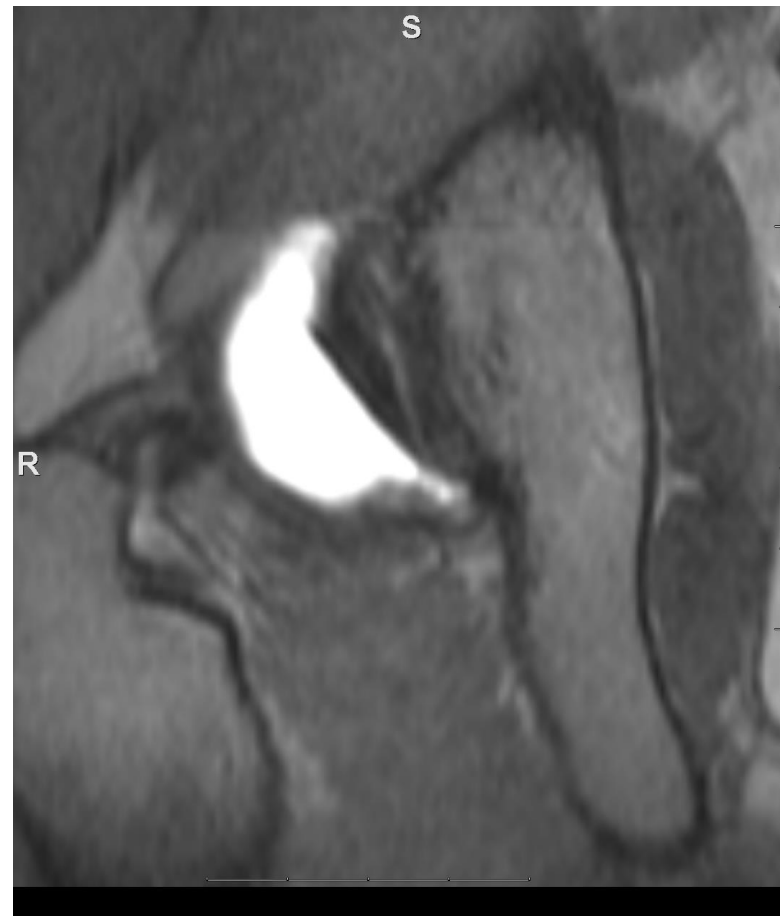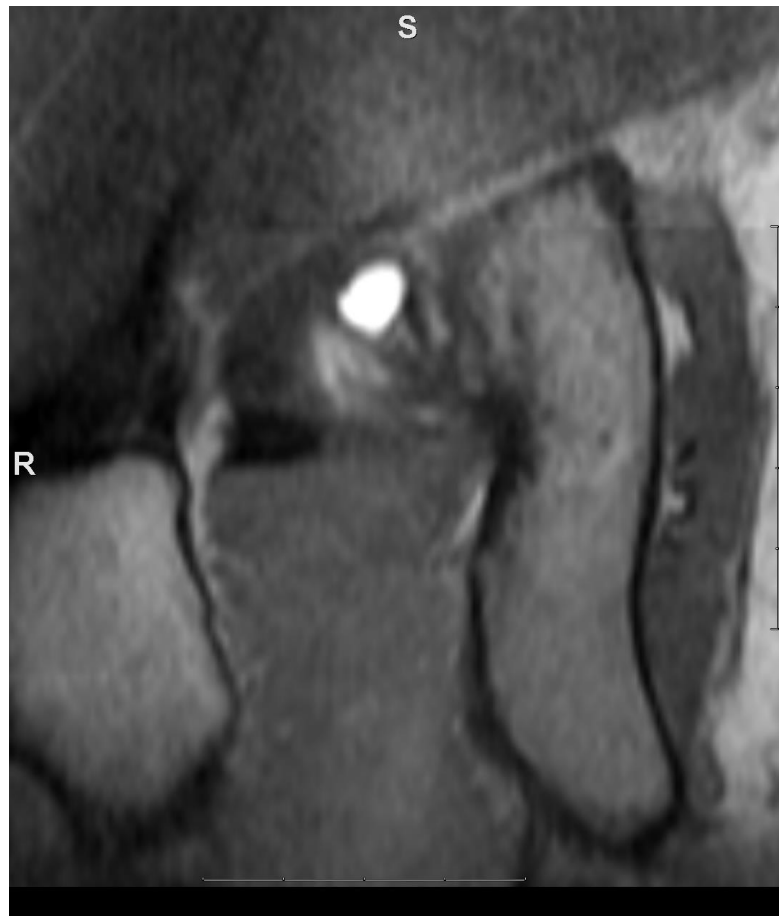On arthroscopy



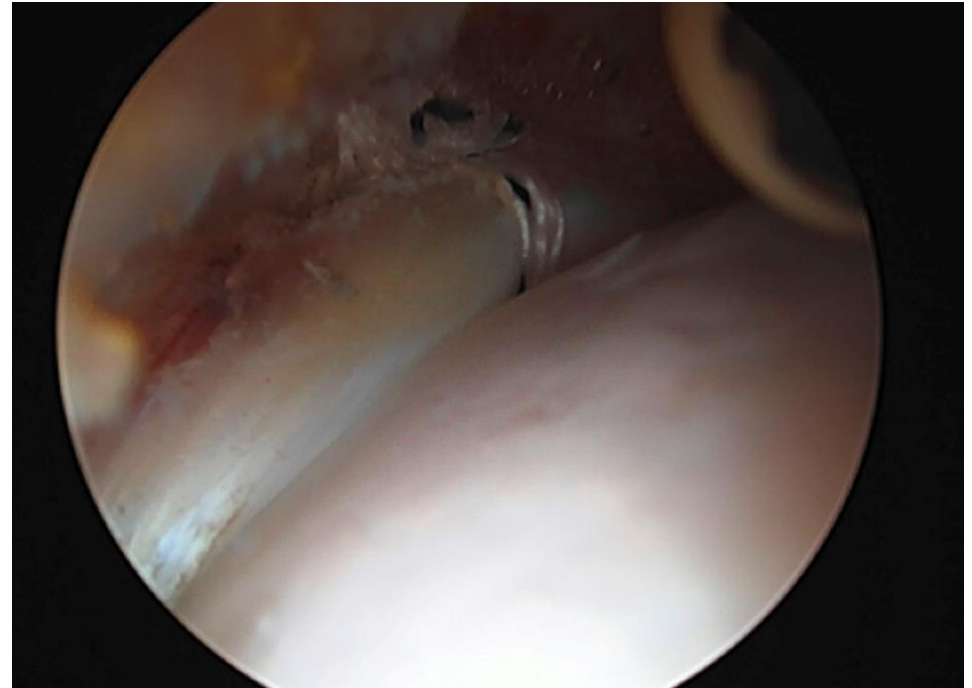
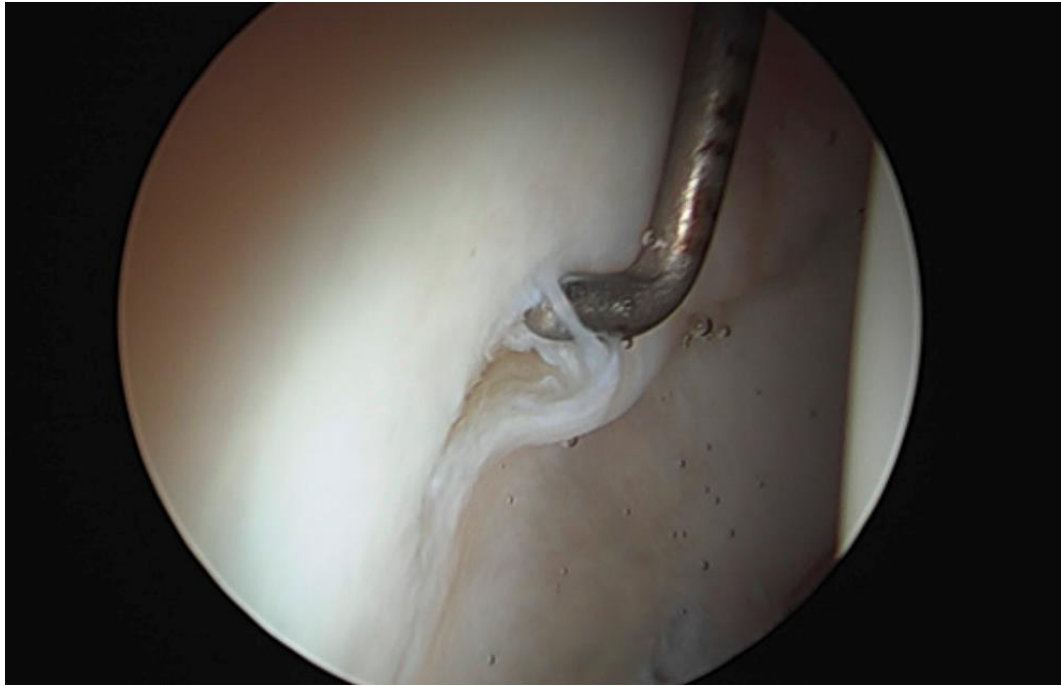
Another HD case- posterior lab tear- MRA- 2D



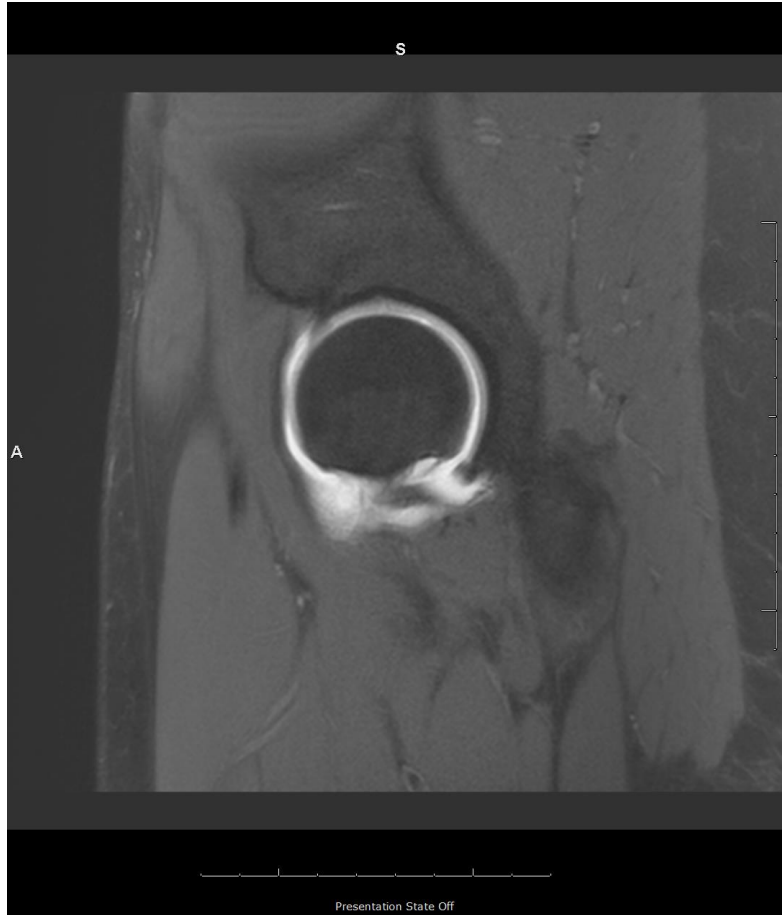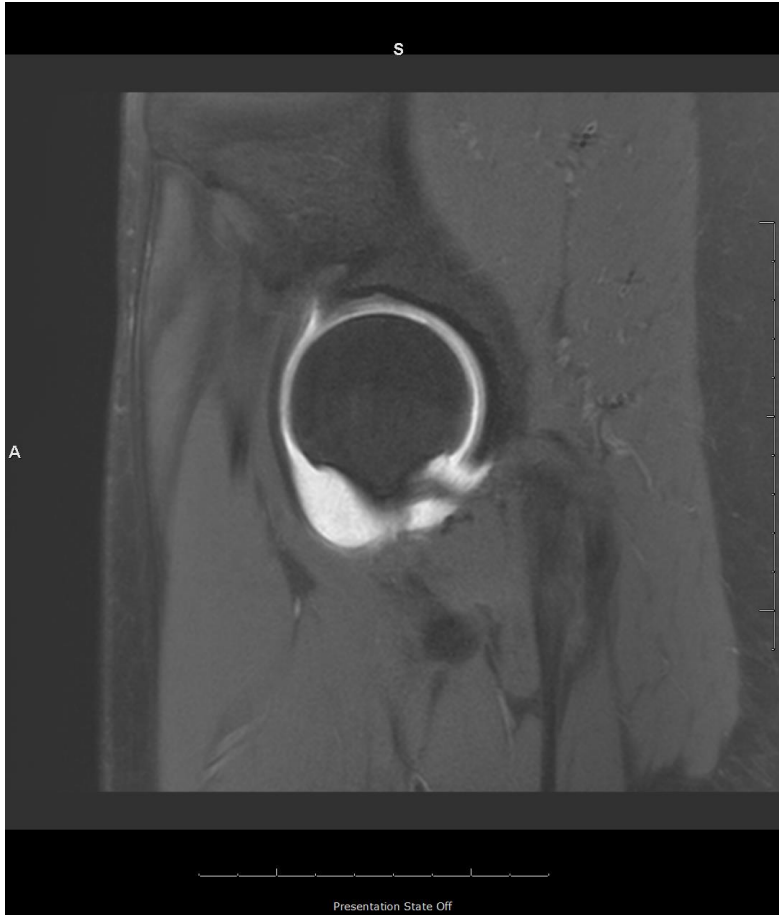Here's 3D- you can measure exactly



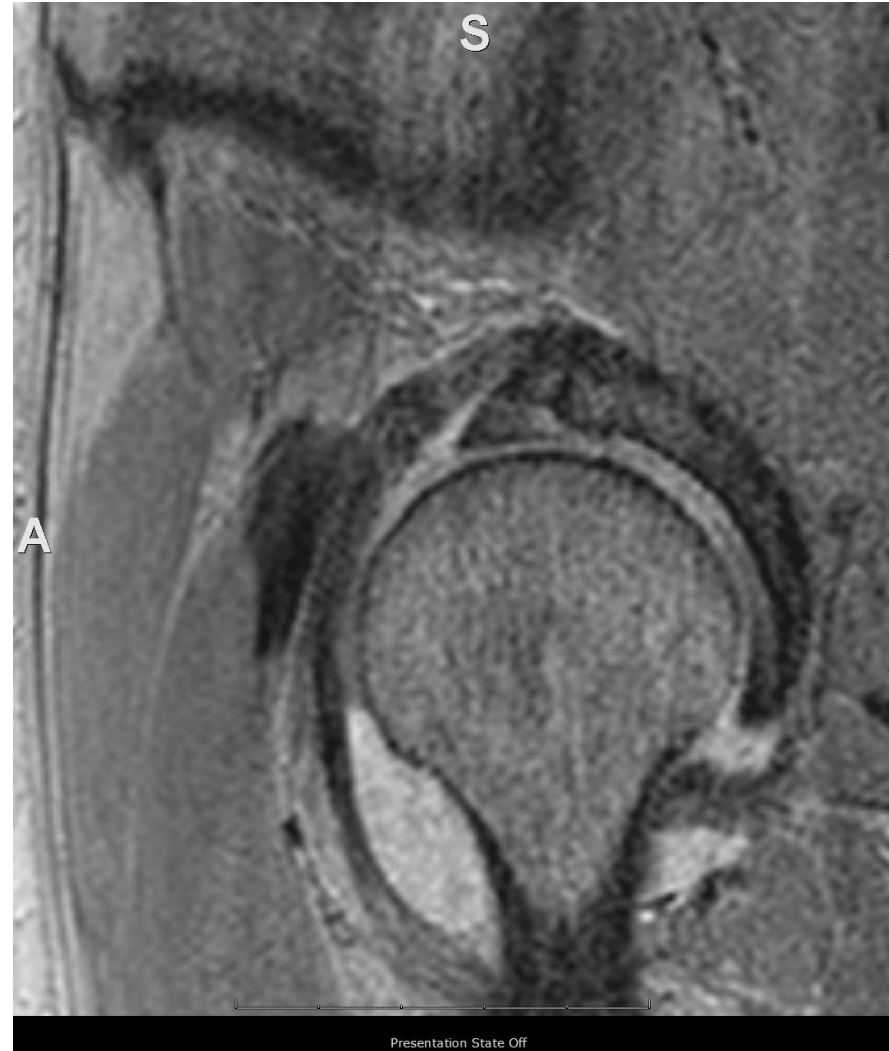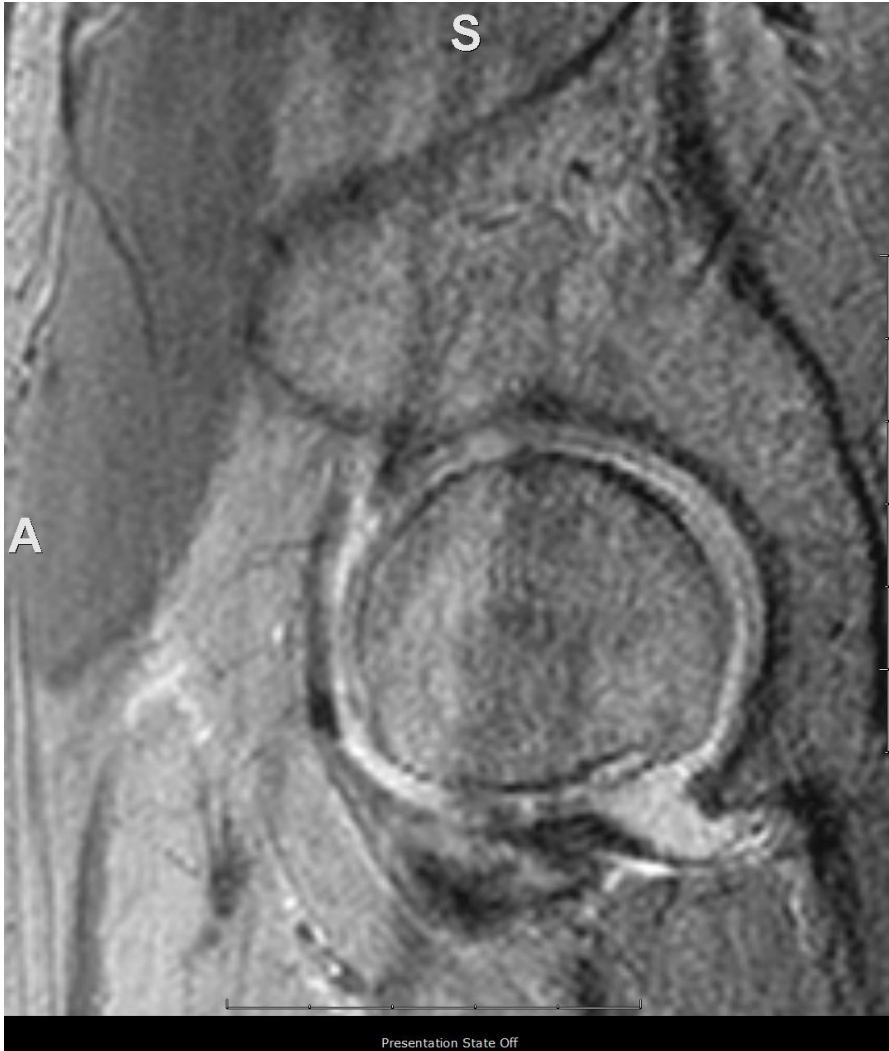Before and after repair



Another HD case- what do you think of fem head cartilage- 2D MRA



3D- artifacts but broad area of grade IV defect is easily seen



Grade IV- bad head

