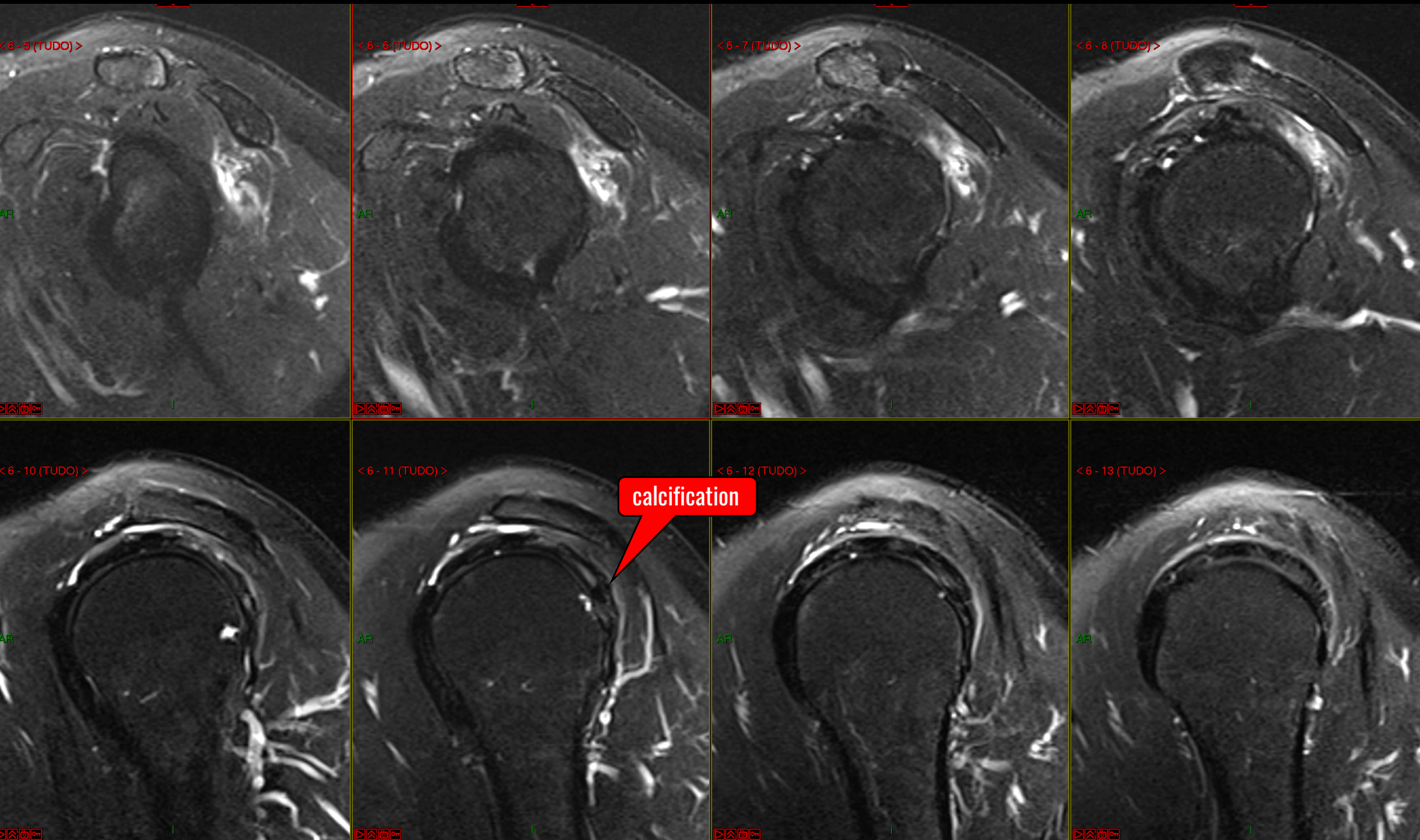
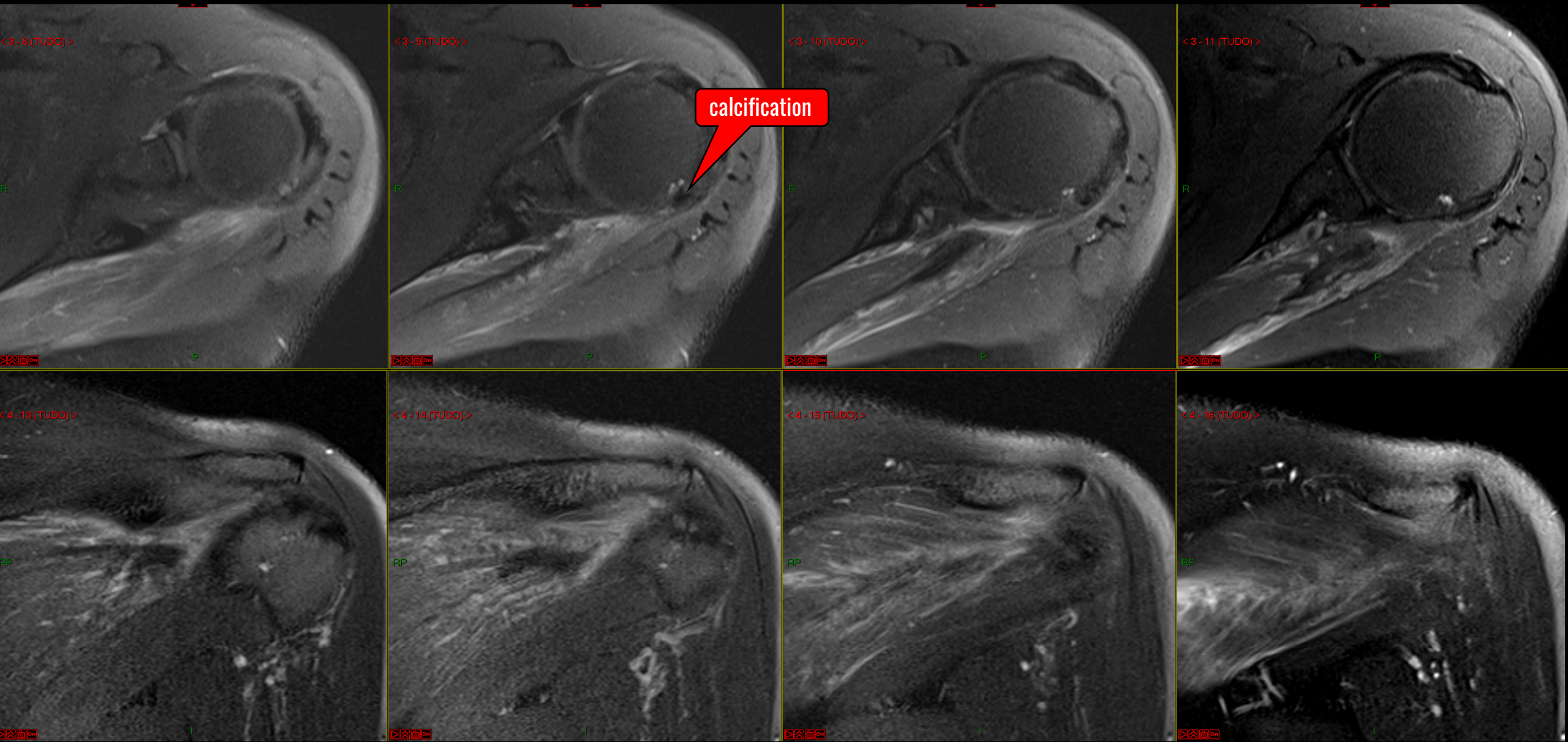


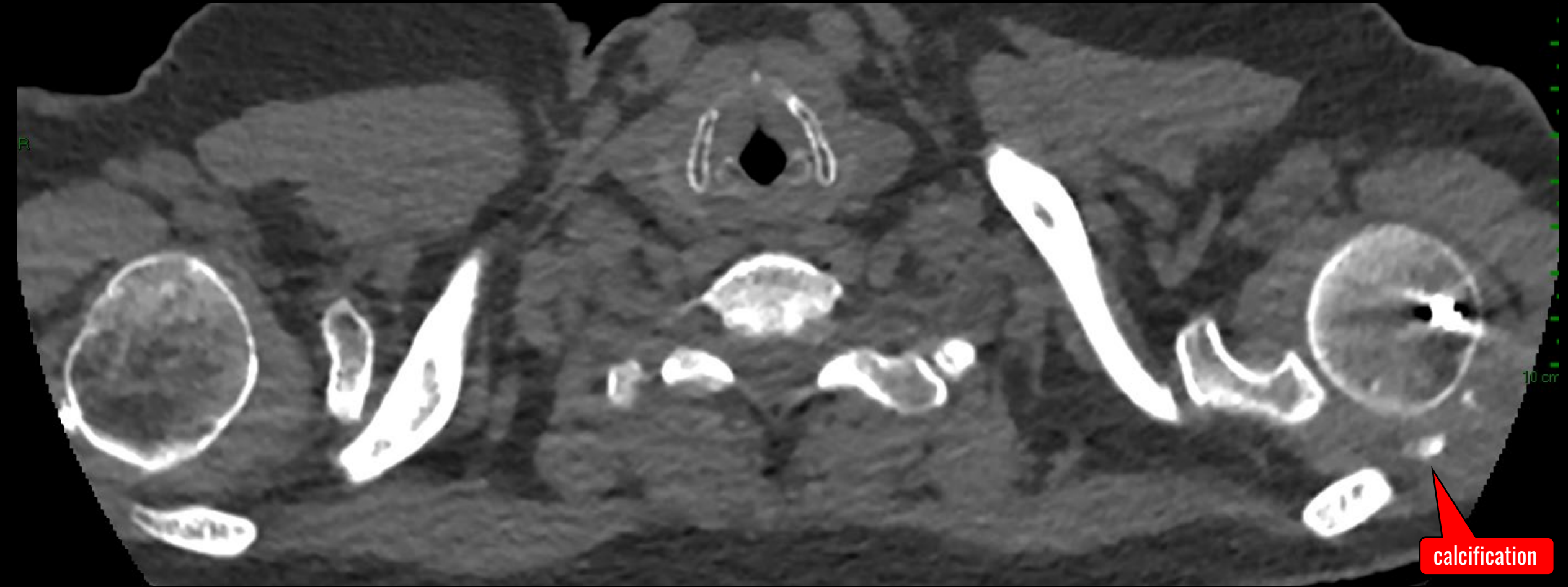
59 yo, female – INFRA myotendineous lesion



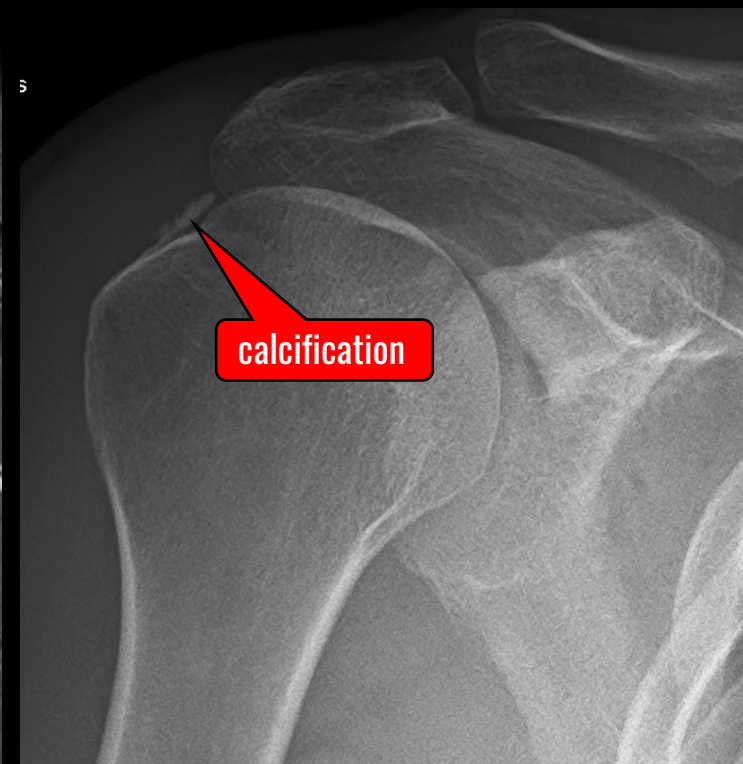
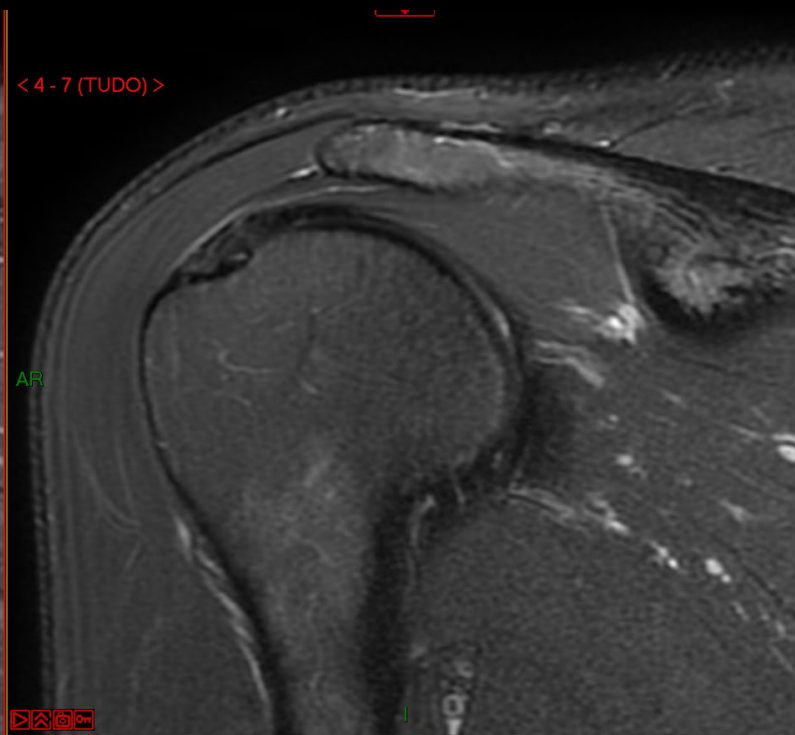
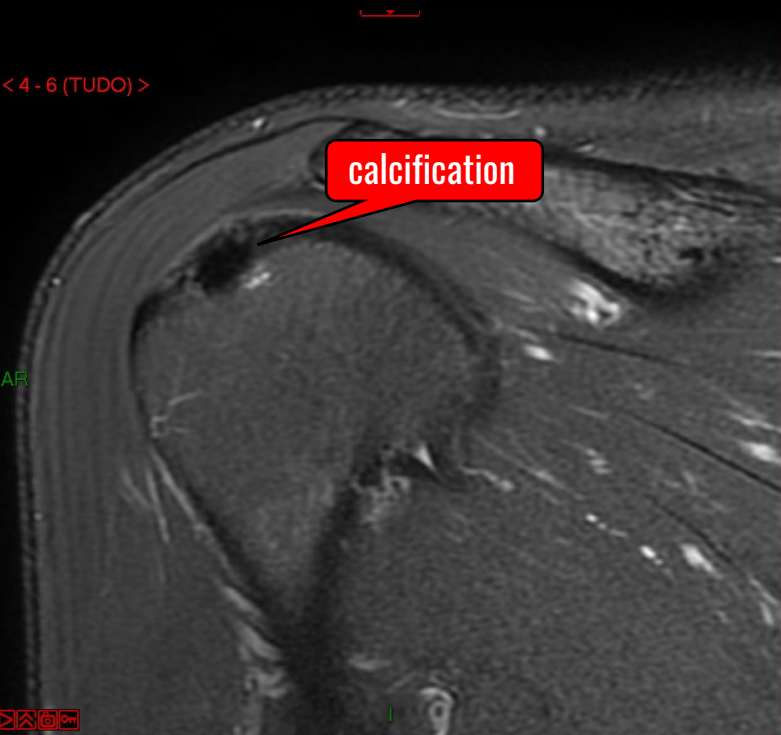
59 yo, female – INFRA myotendineous lesion



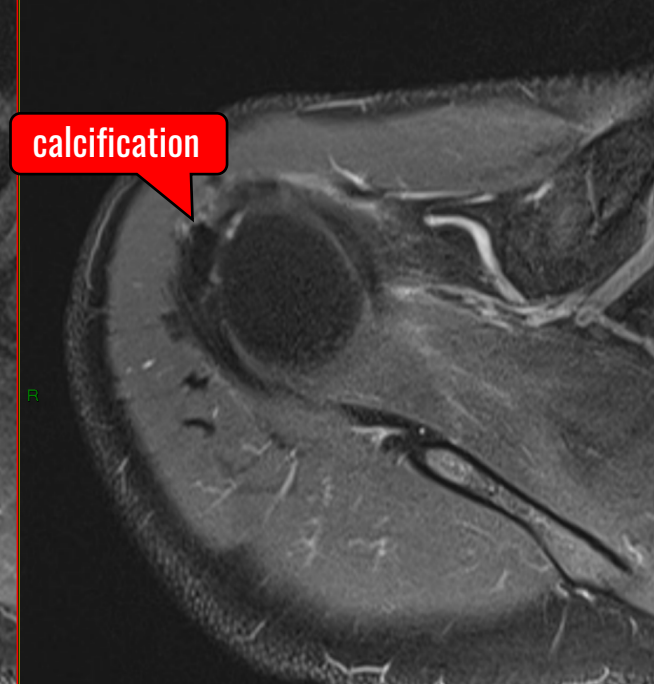
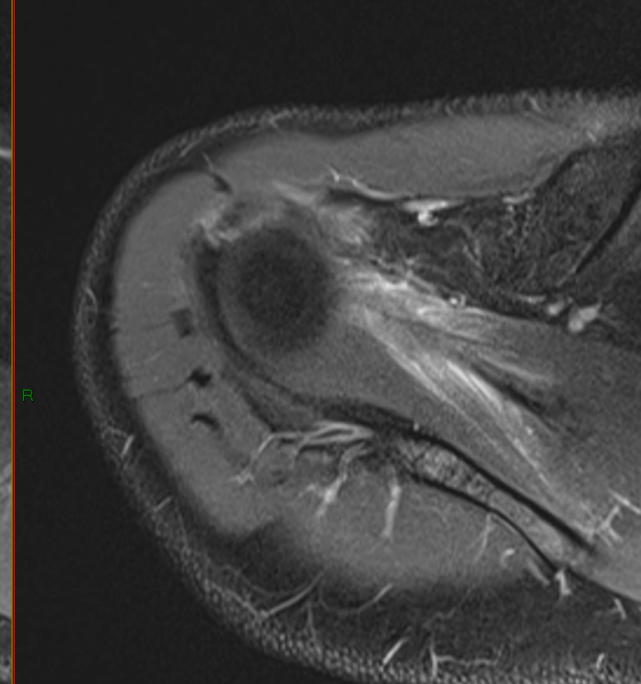
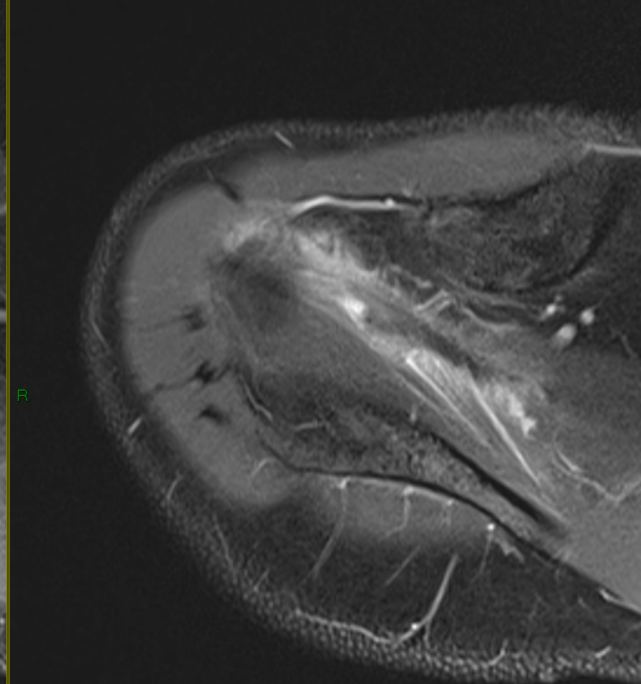
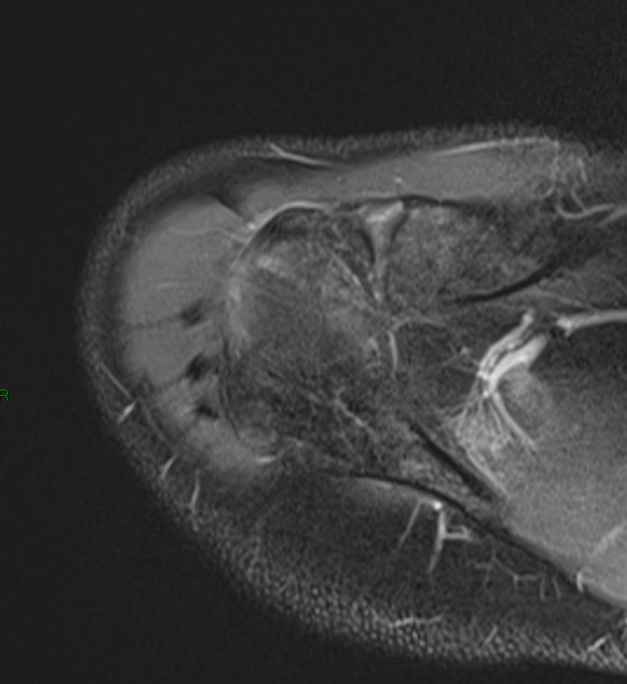
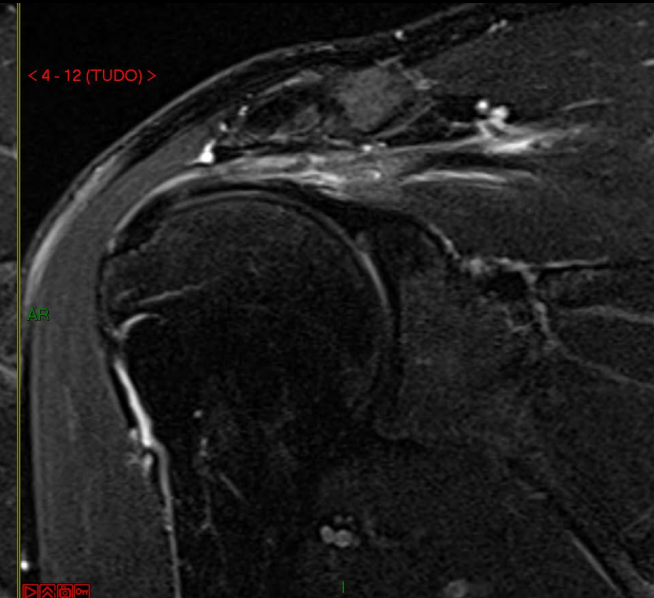
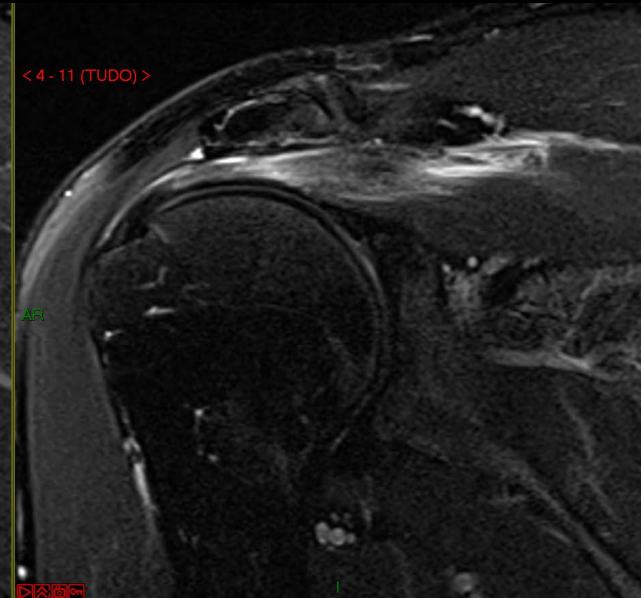
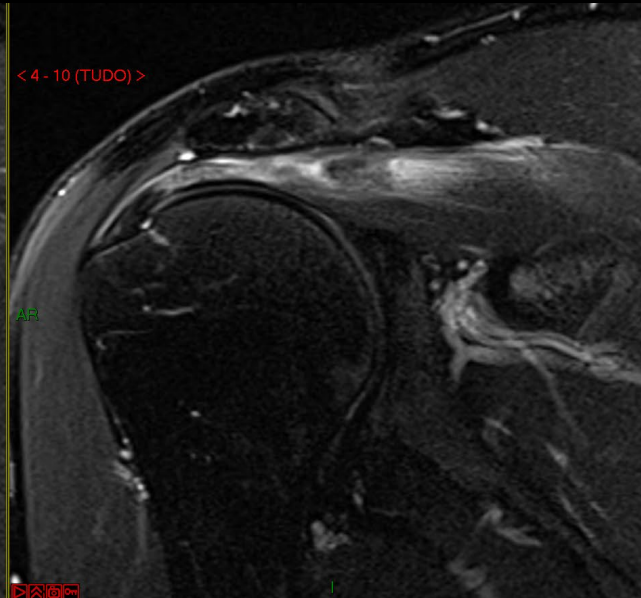
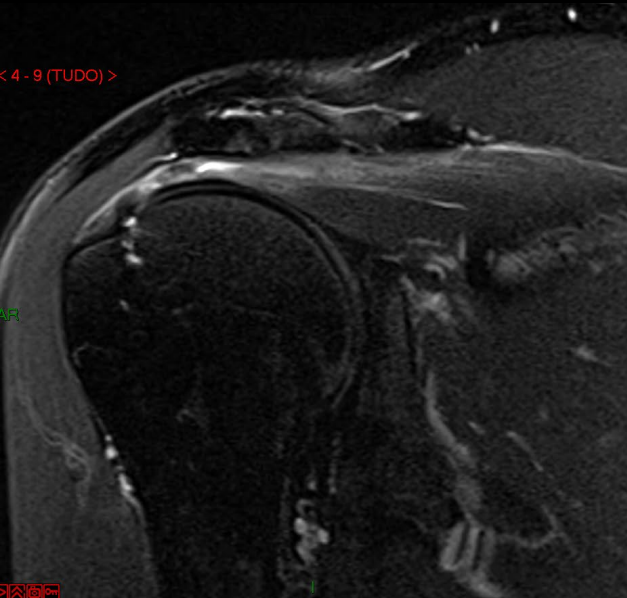
Chest CT – months after rc surgery



39 yo, male – BEFORE SUPRA myotendinous lesion



39 yo, male – SUPRA myotendinous lesion (2 months later)



39 yo, male – SUPRA myotendinous lesion (2 months later)

