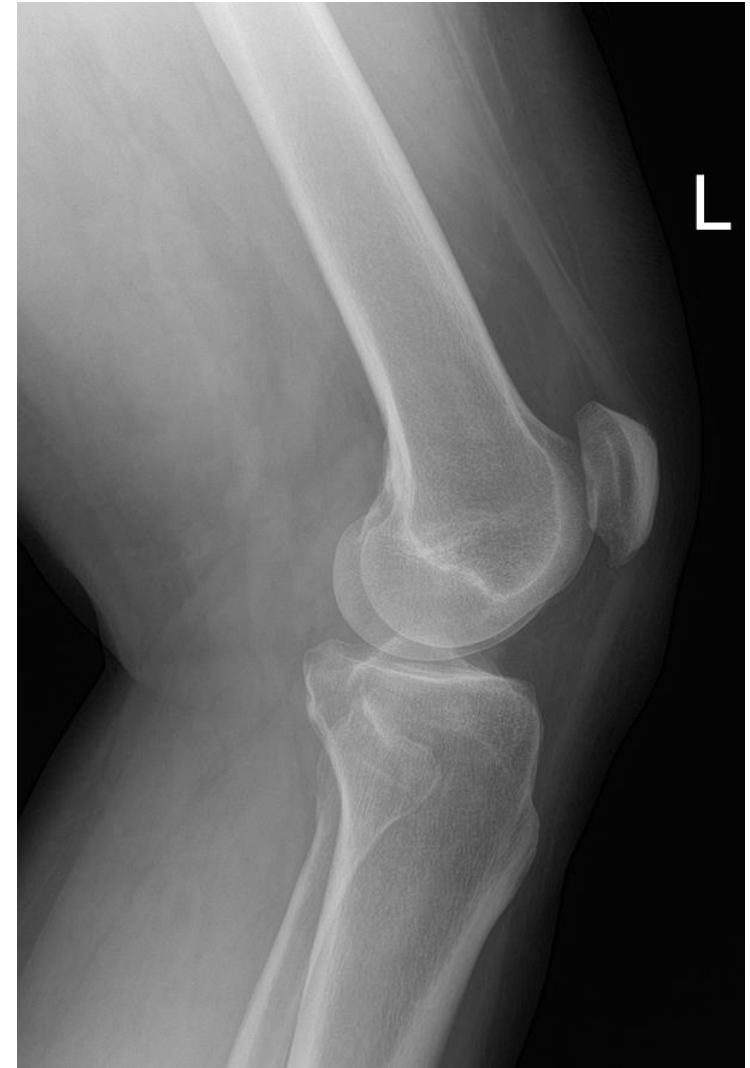
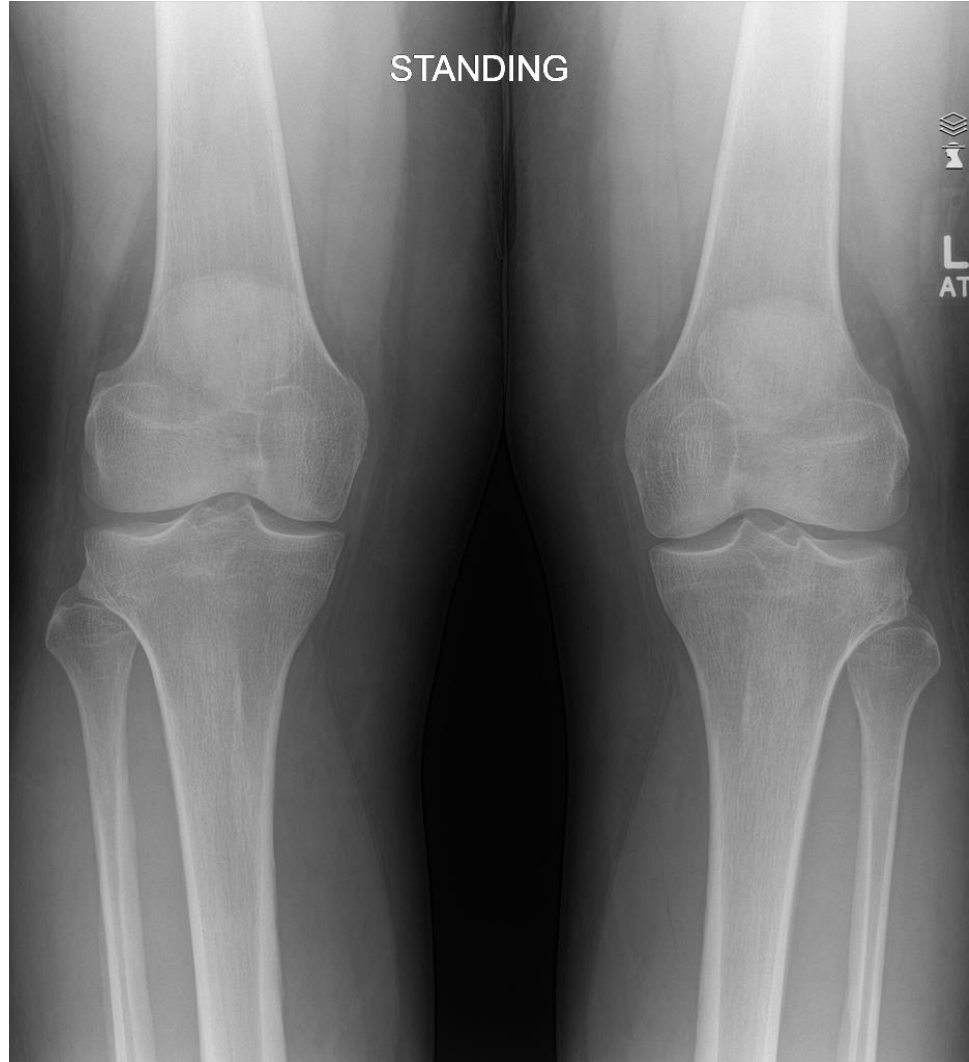
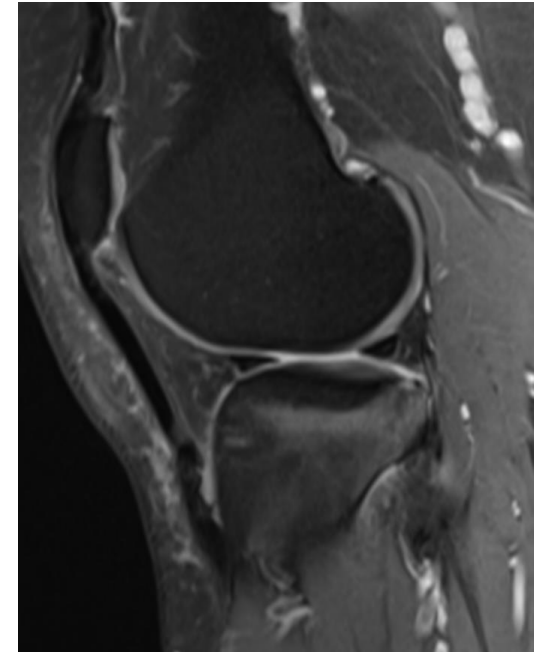
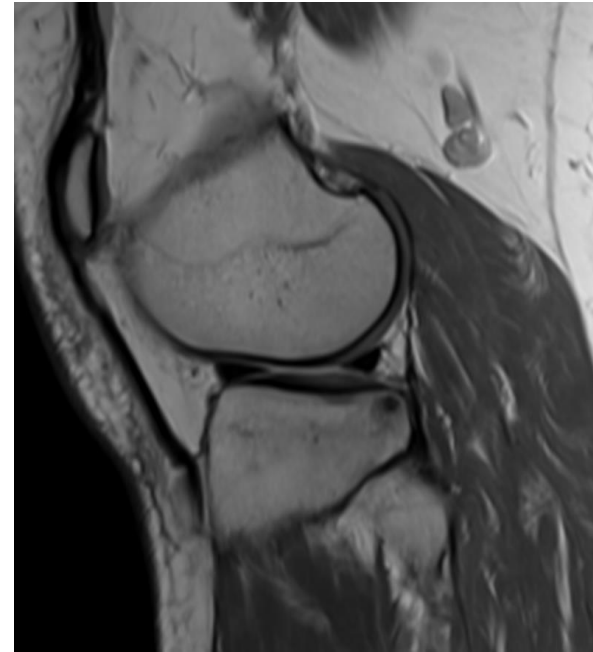
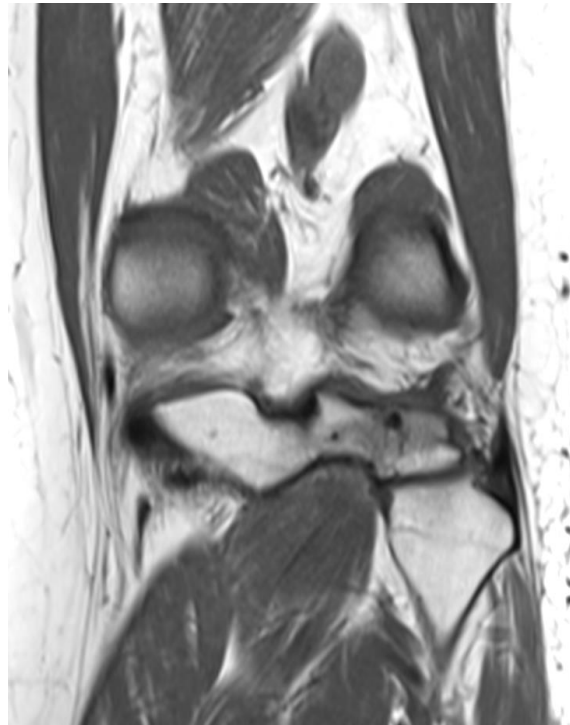
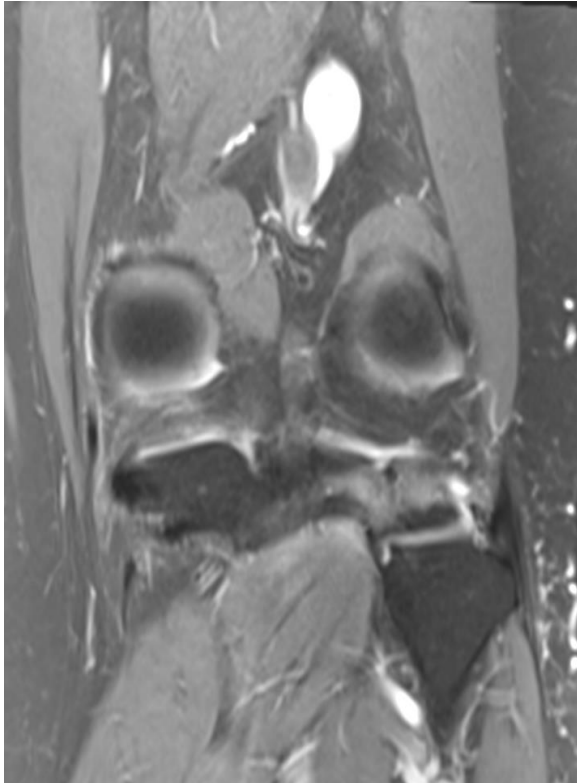
Posterior lateral tibial
plateau lesion

- 42 year old male with focal area of signal abnormality along the posterior aspect of the lateral tibial plateau that has been growing since 2020:
 - Left knee pain following a fall at work on 05/13/2020.
 - PMHx of diabetes and HTN
- On 01/28/2021 pt had a left knee arthroscopy with partial lateral meniscectomy, patellofemoral chondroplasty and subchondroplasty left proximal tibia.
 - The subchondroplasty was performed through a track more anterior to the area of signal abnormality.
- Pt has continued pain

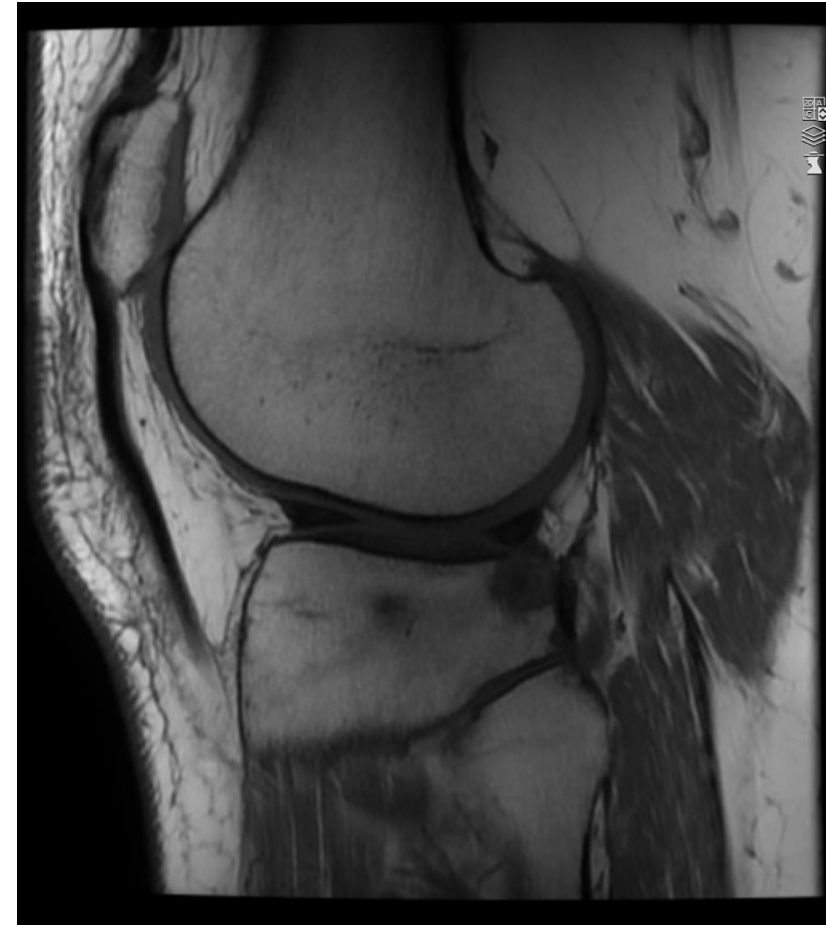
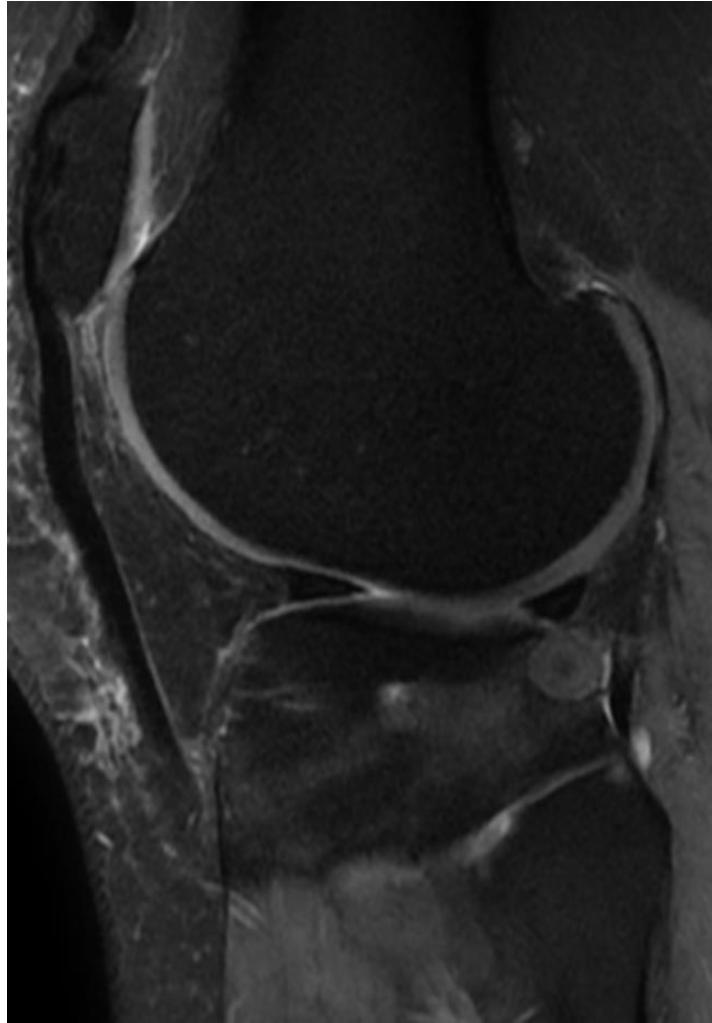
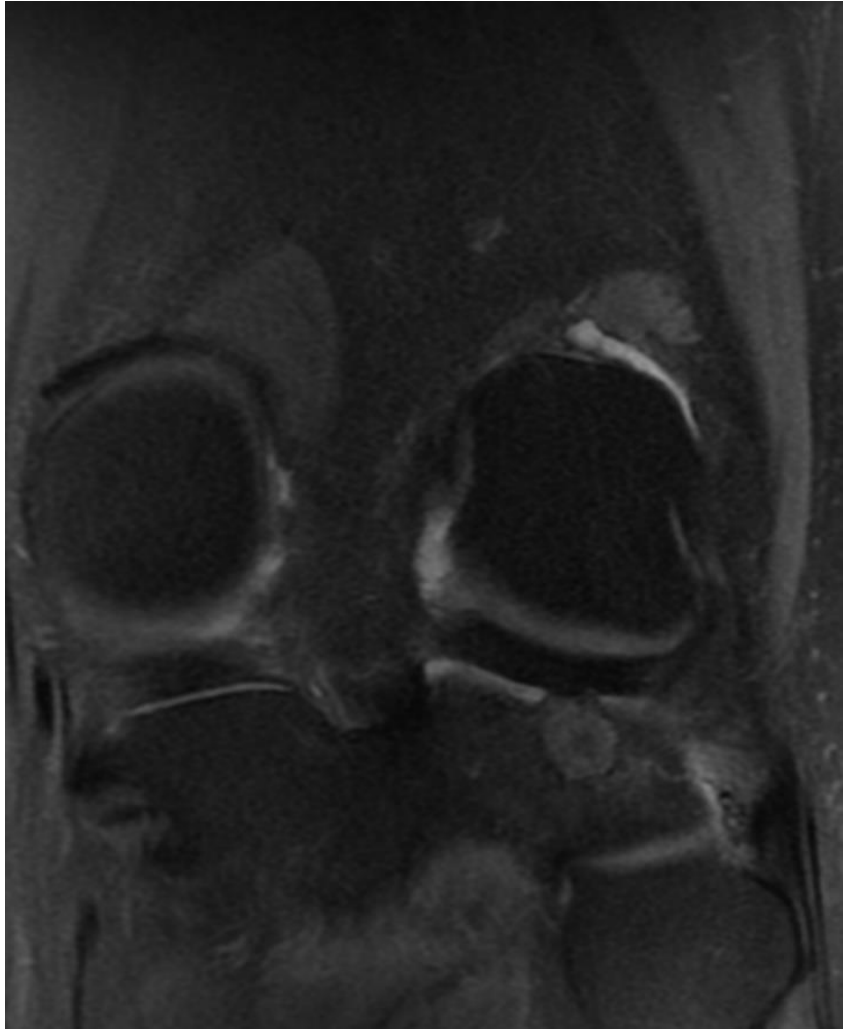Radiograph 05/18/2020



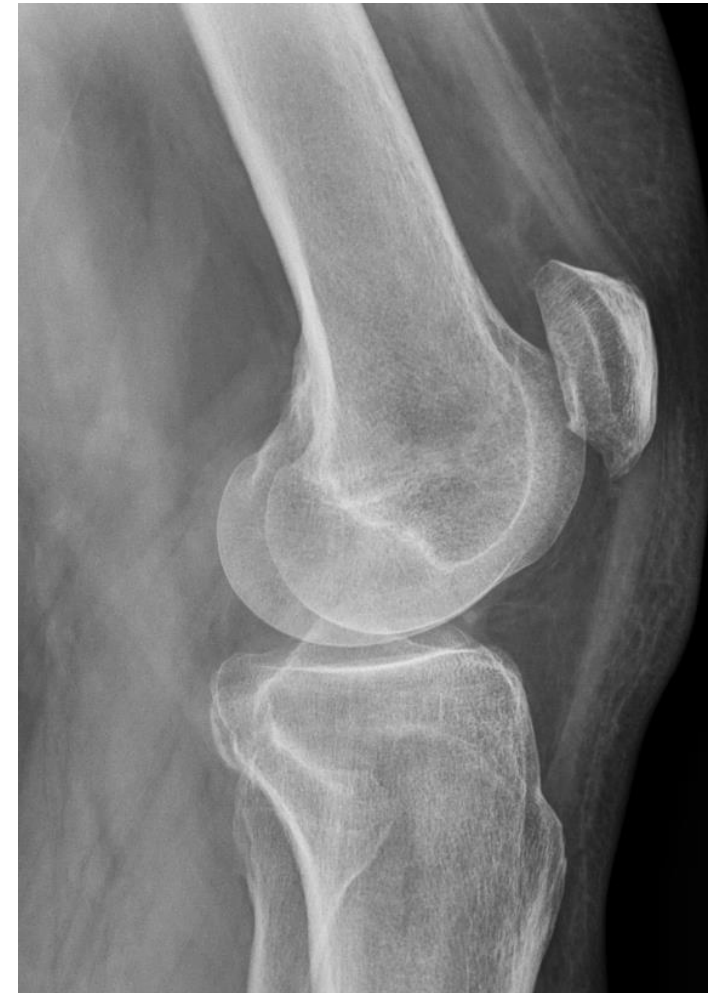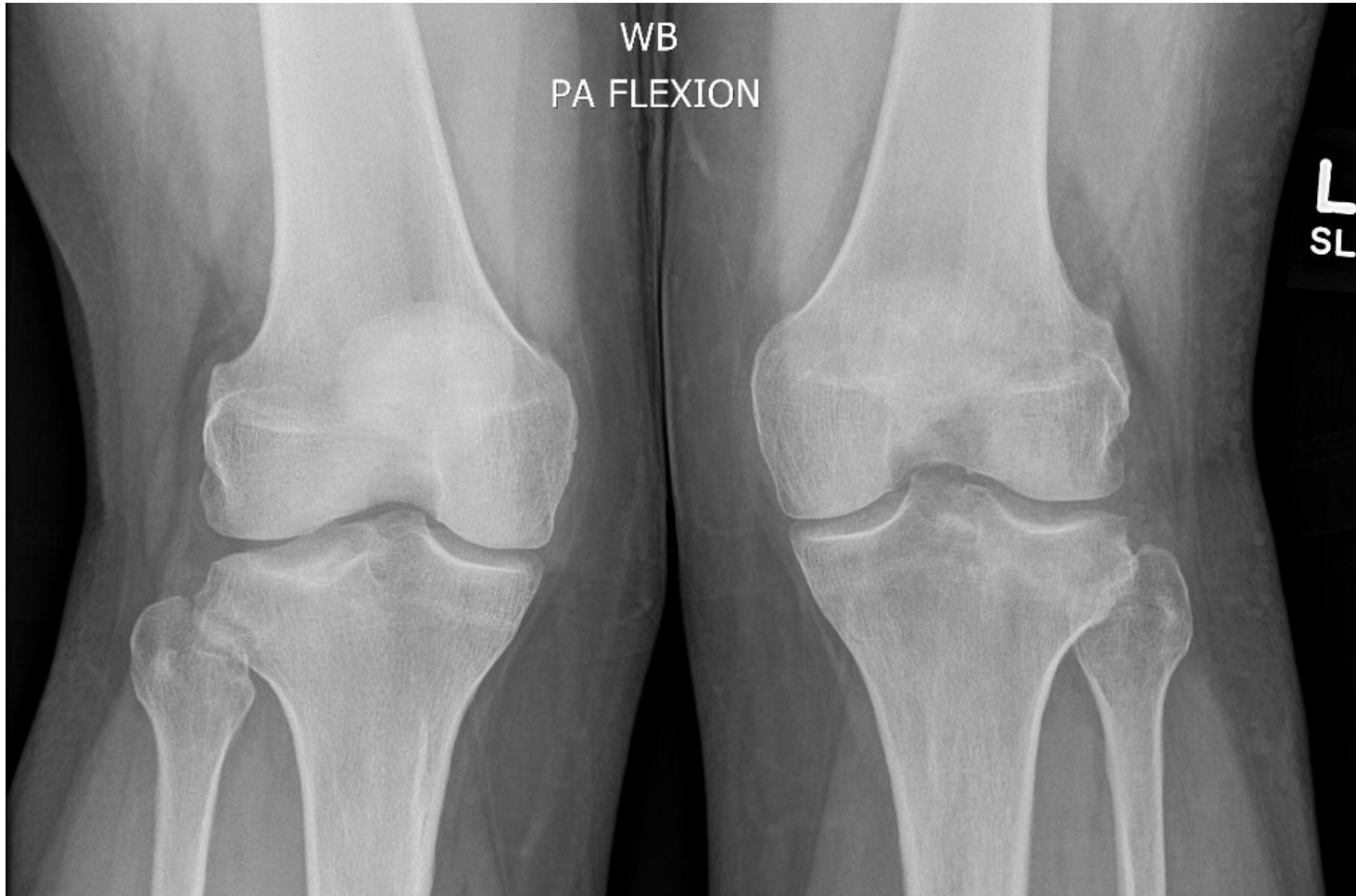MRI 06/08/2020



MRI 11/27/2021



Radiograph 01/06/2022



CT Arthrogram 01/07/2022

