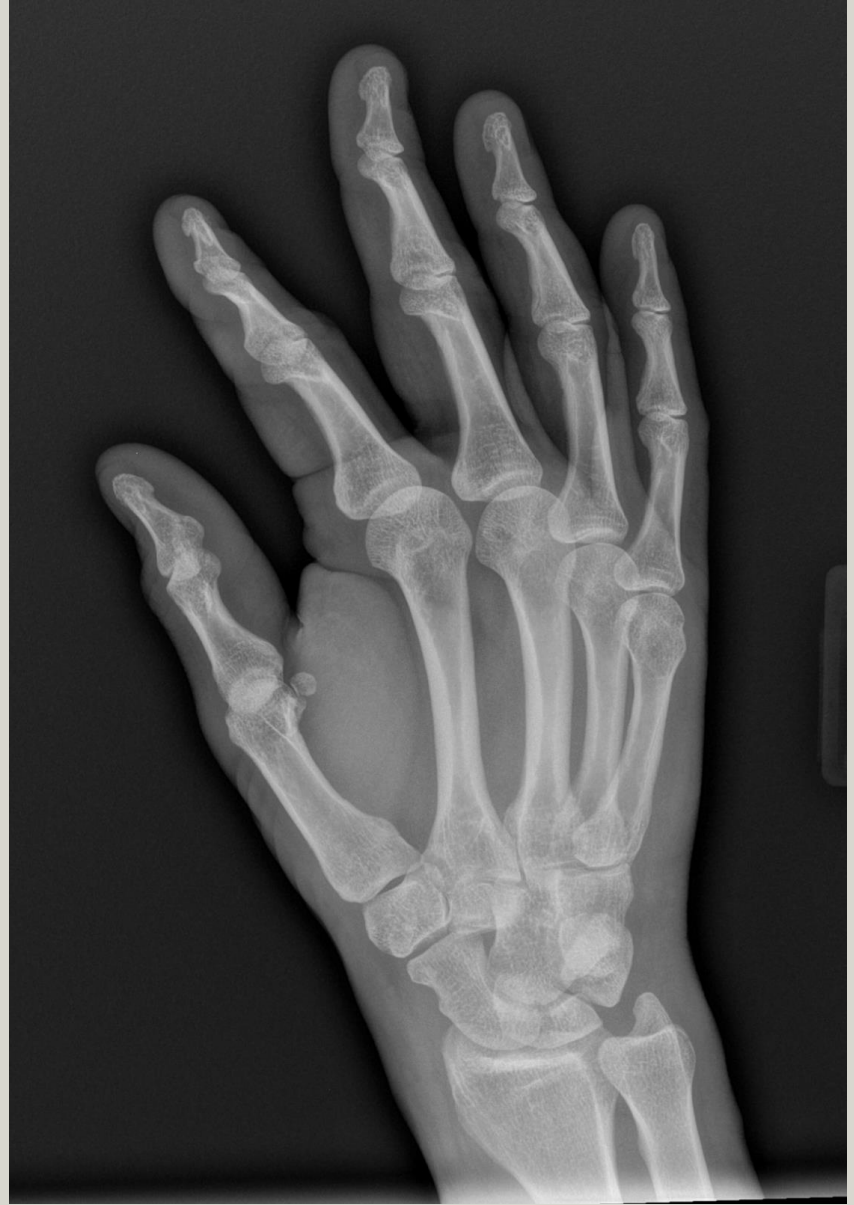
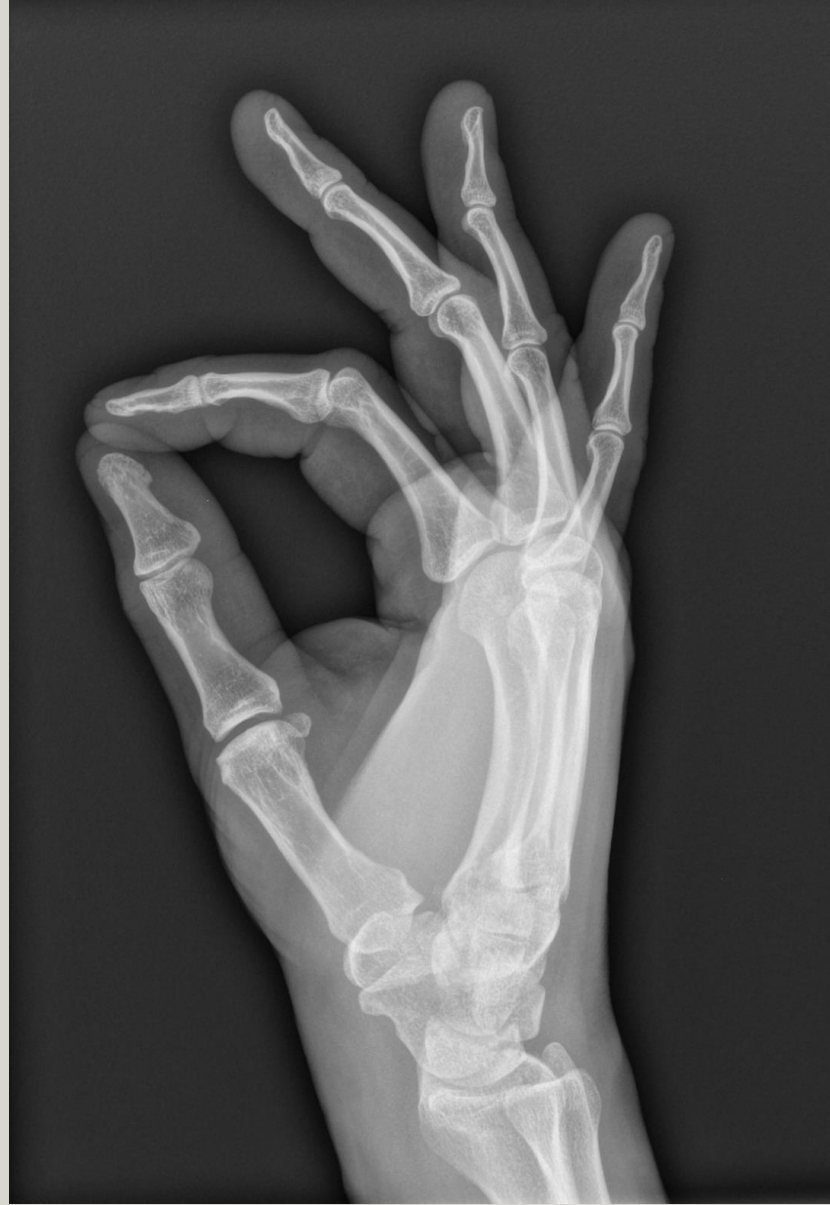
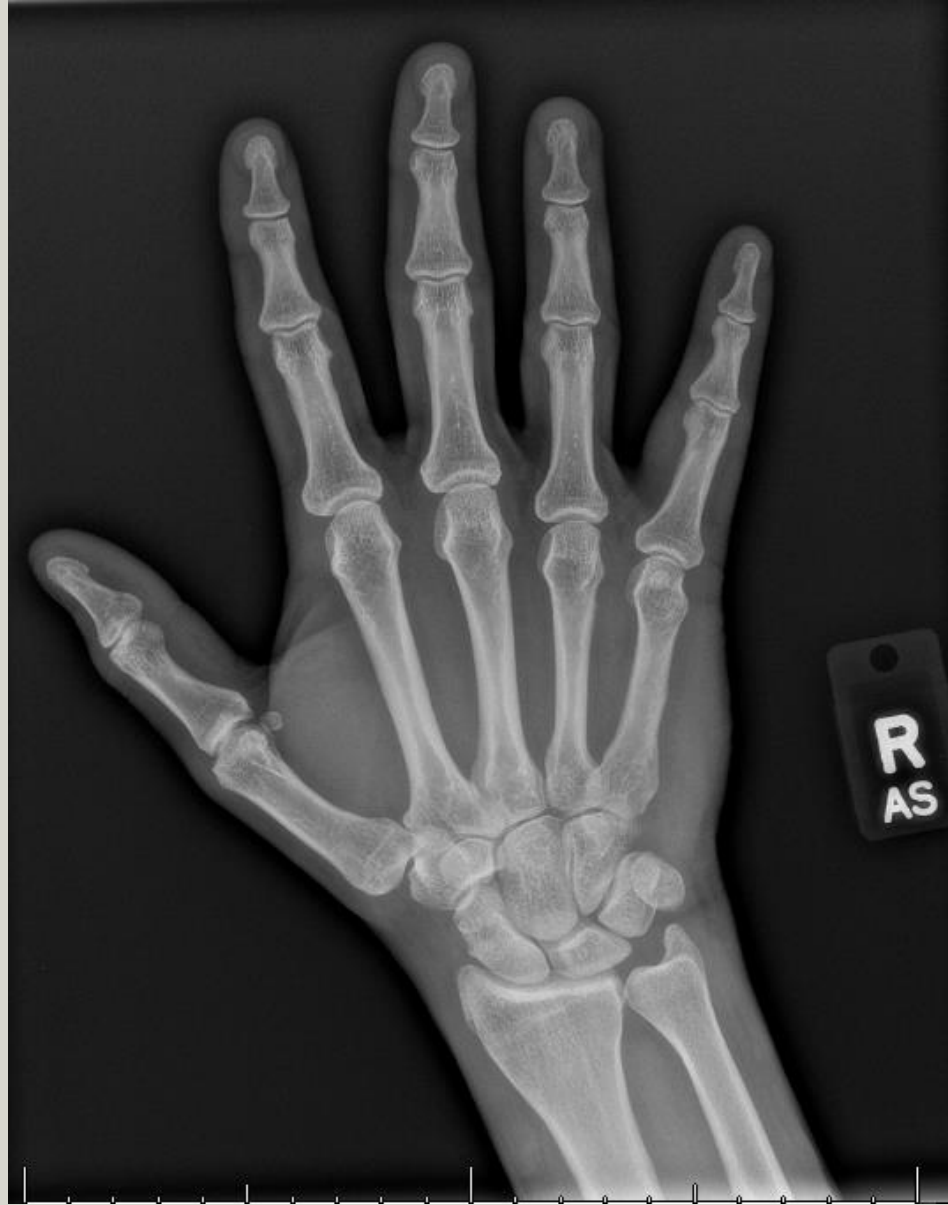

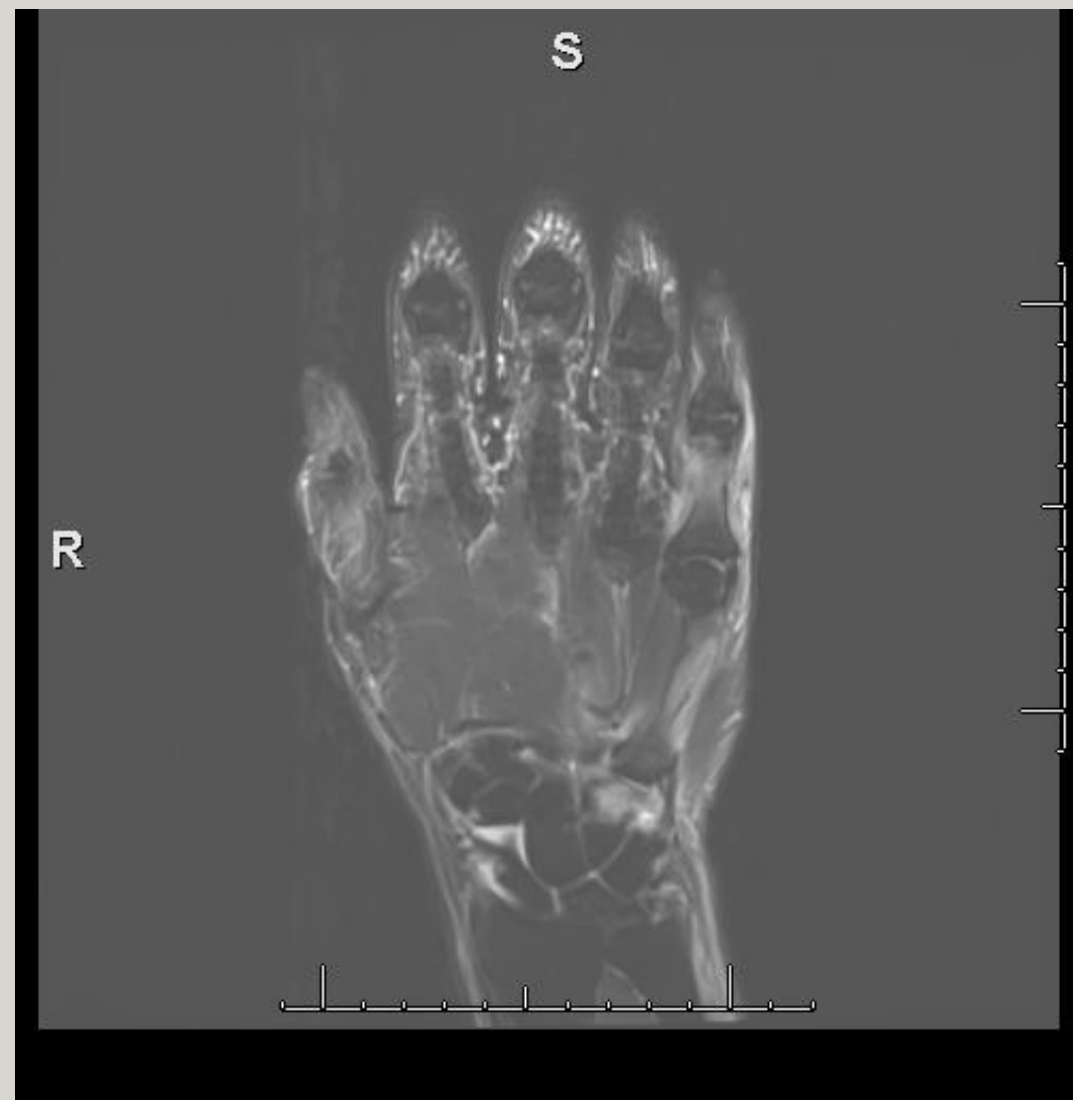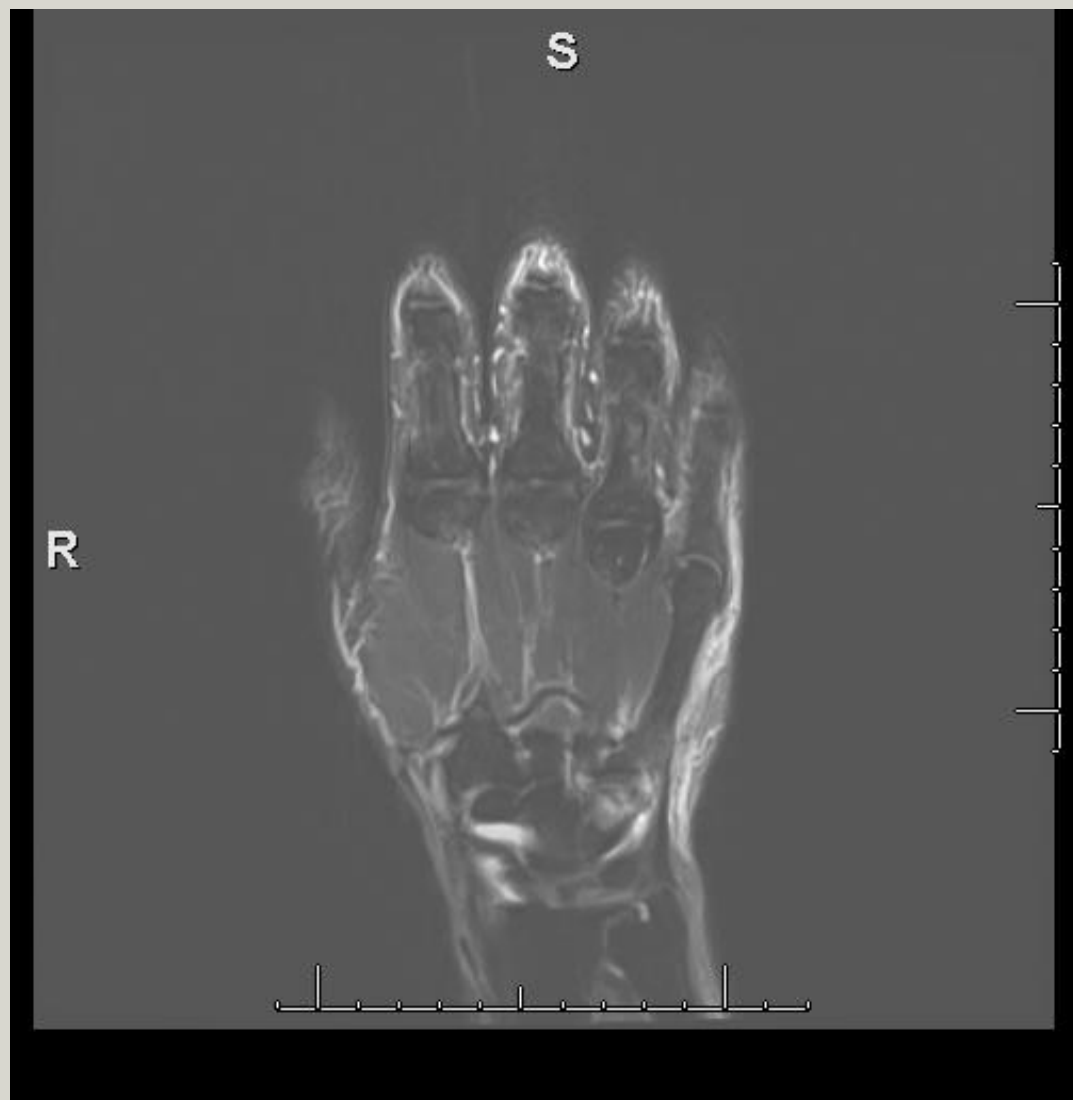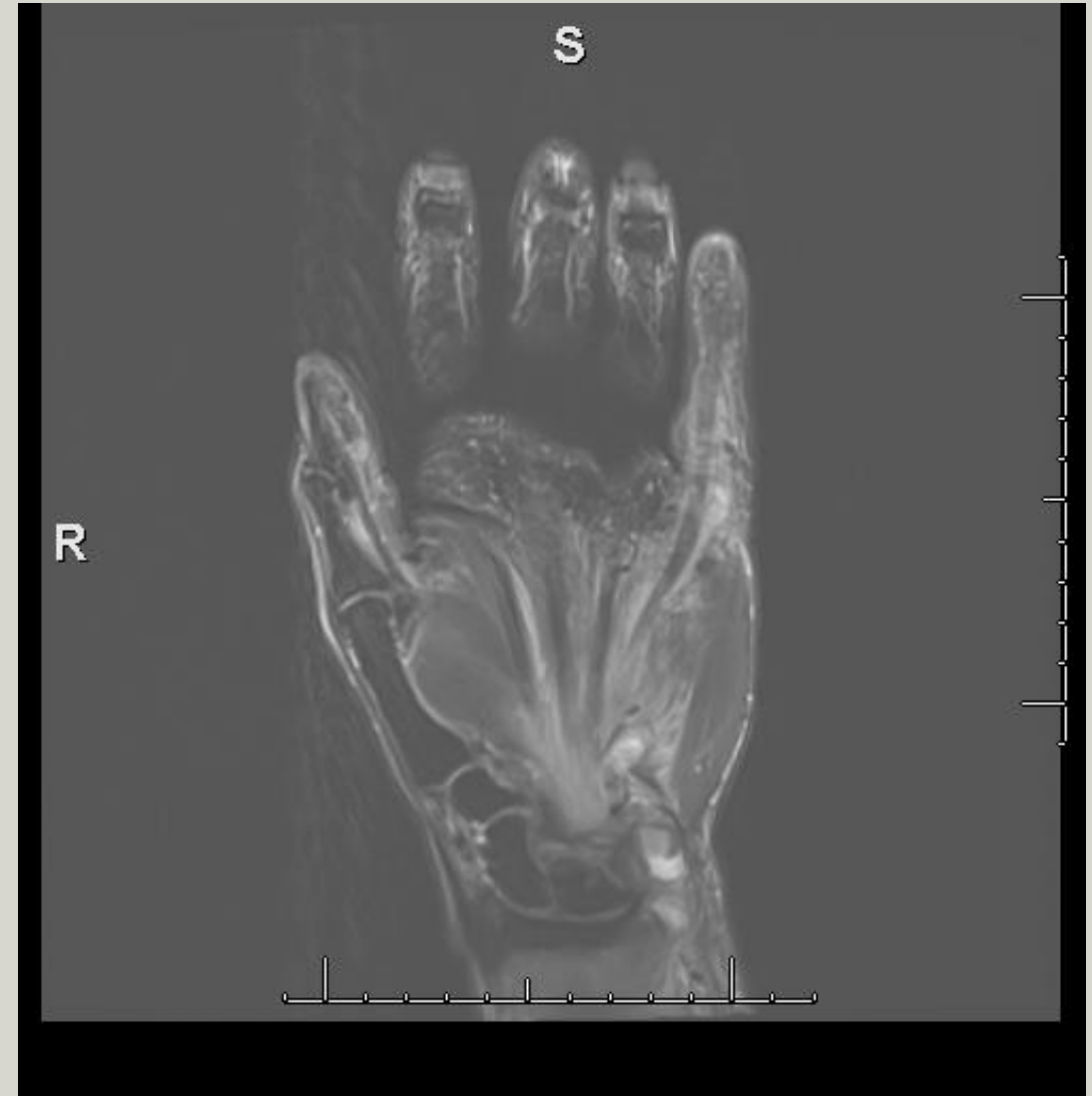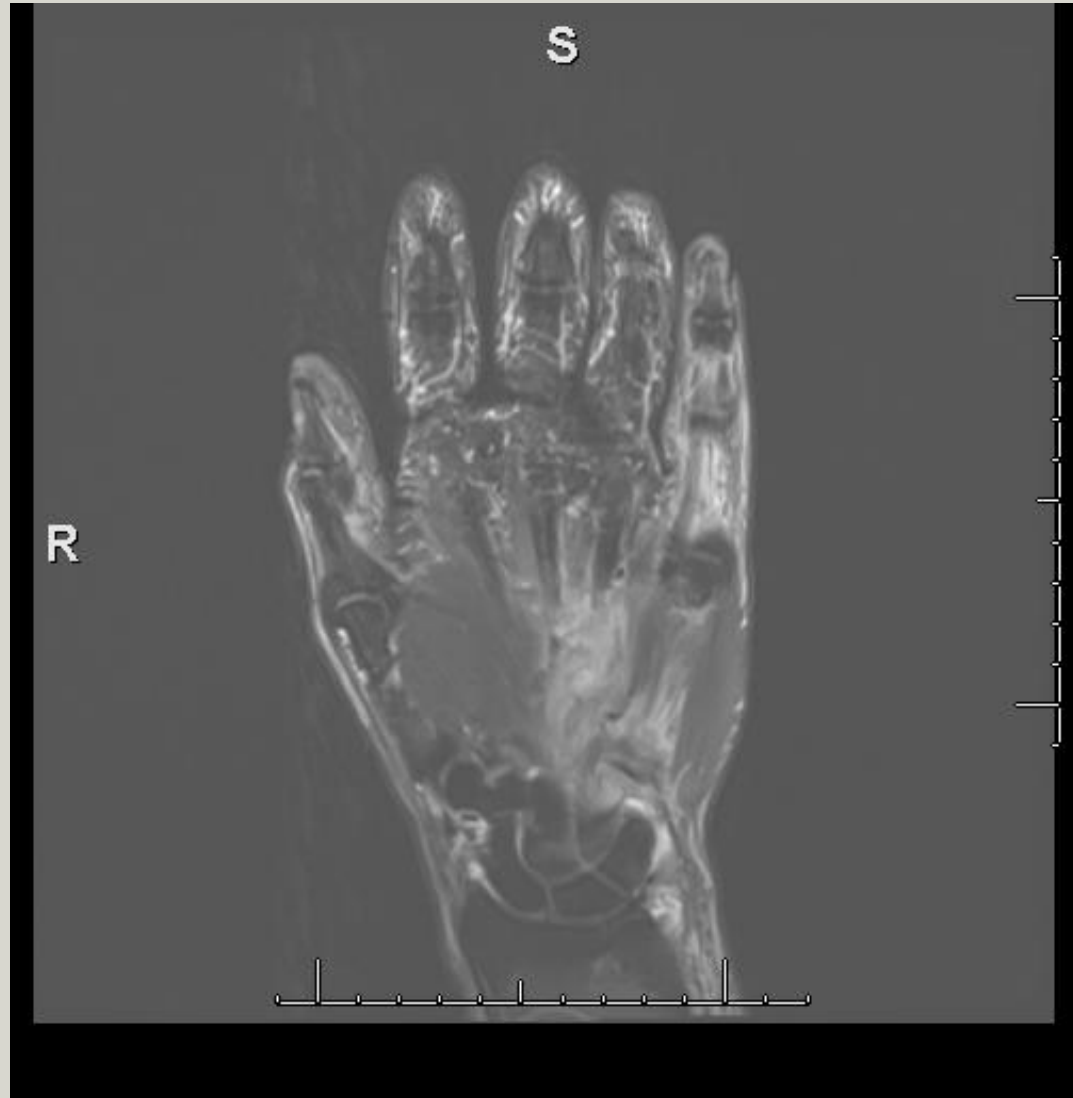Hand pain and swelling following mini-carpal tunnel surgery

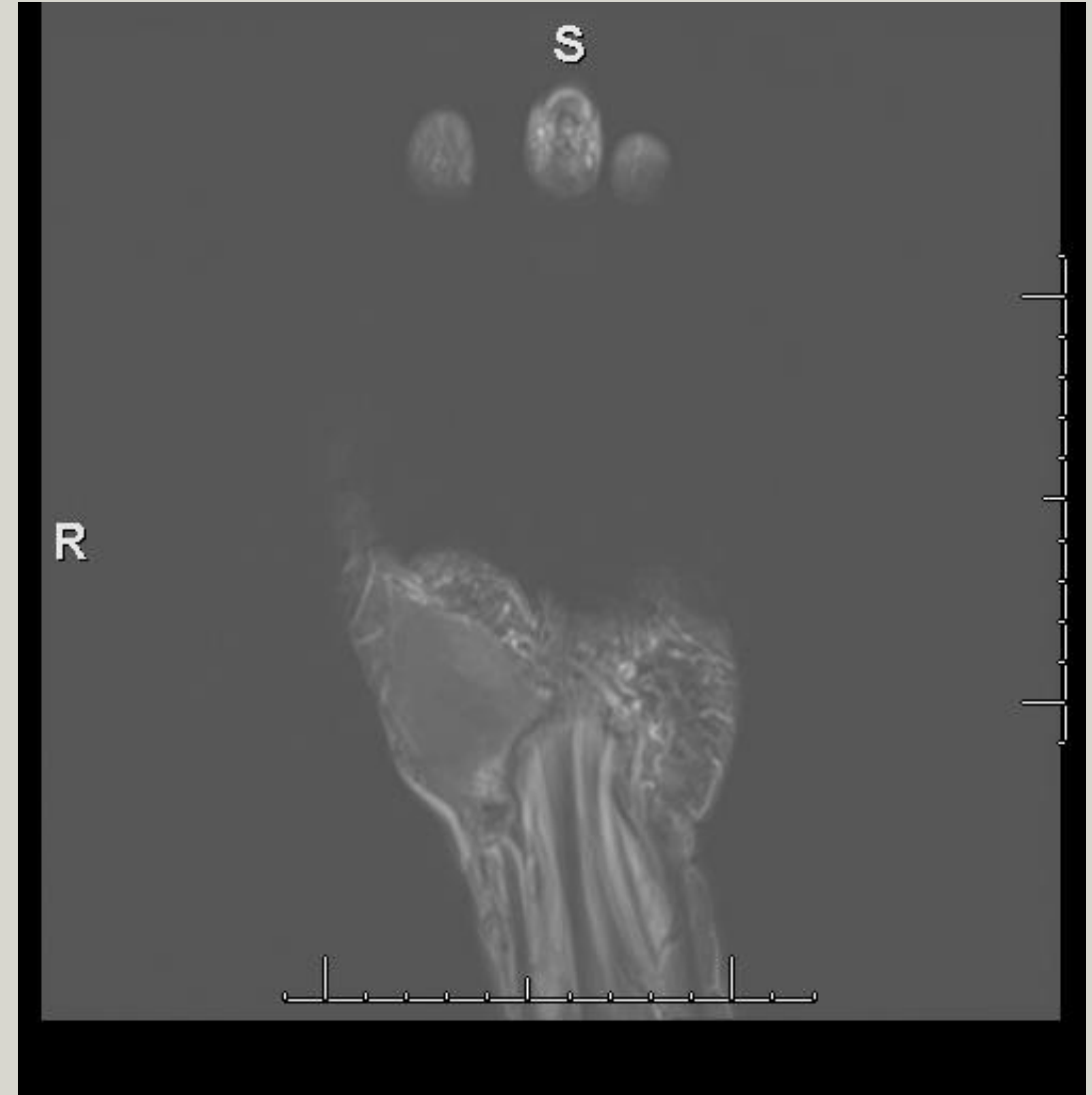
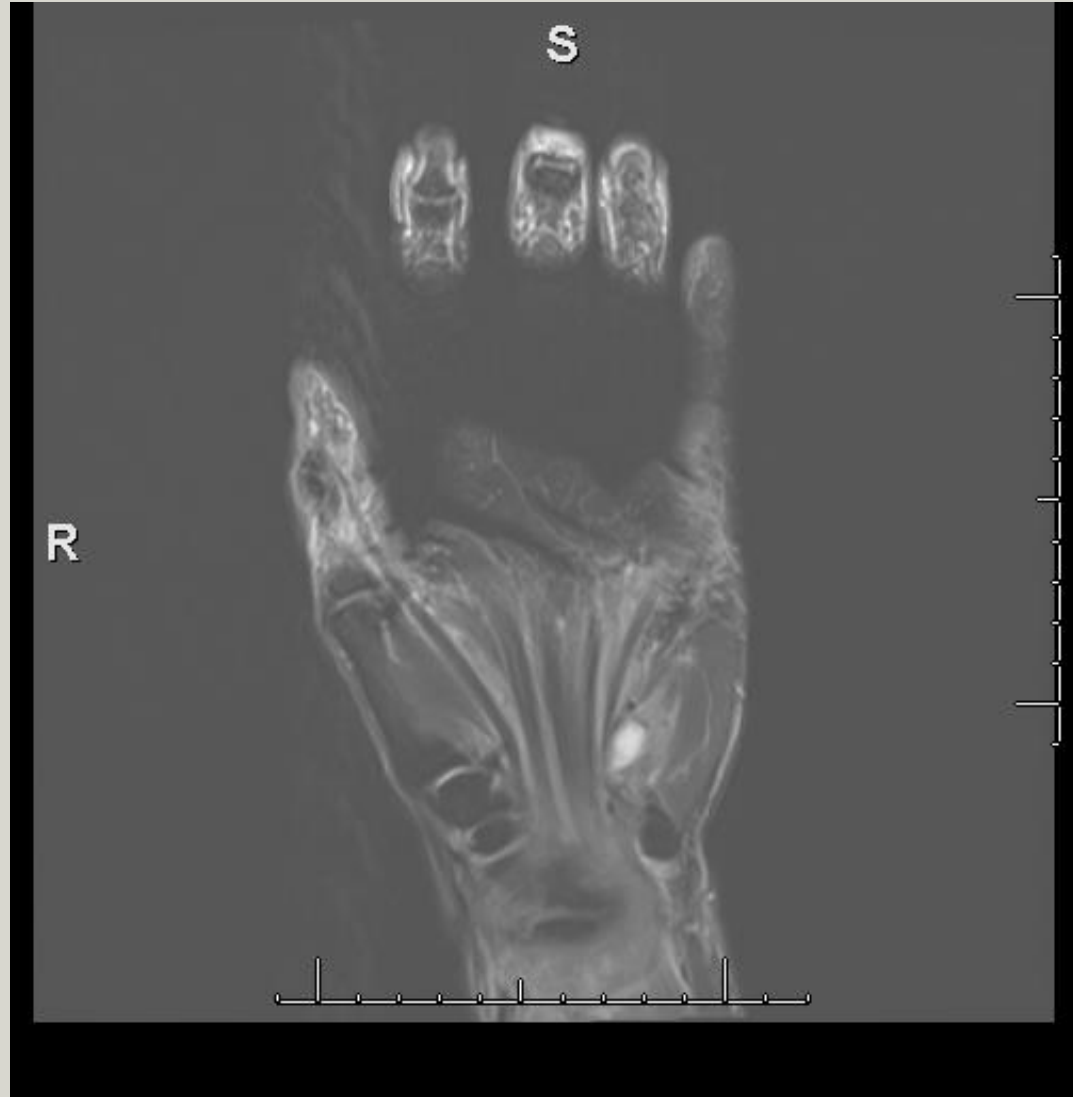

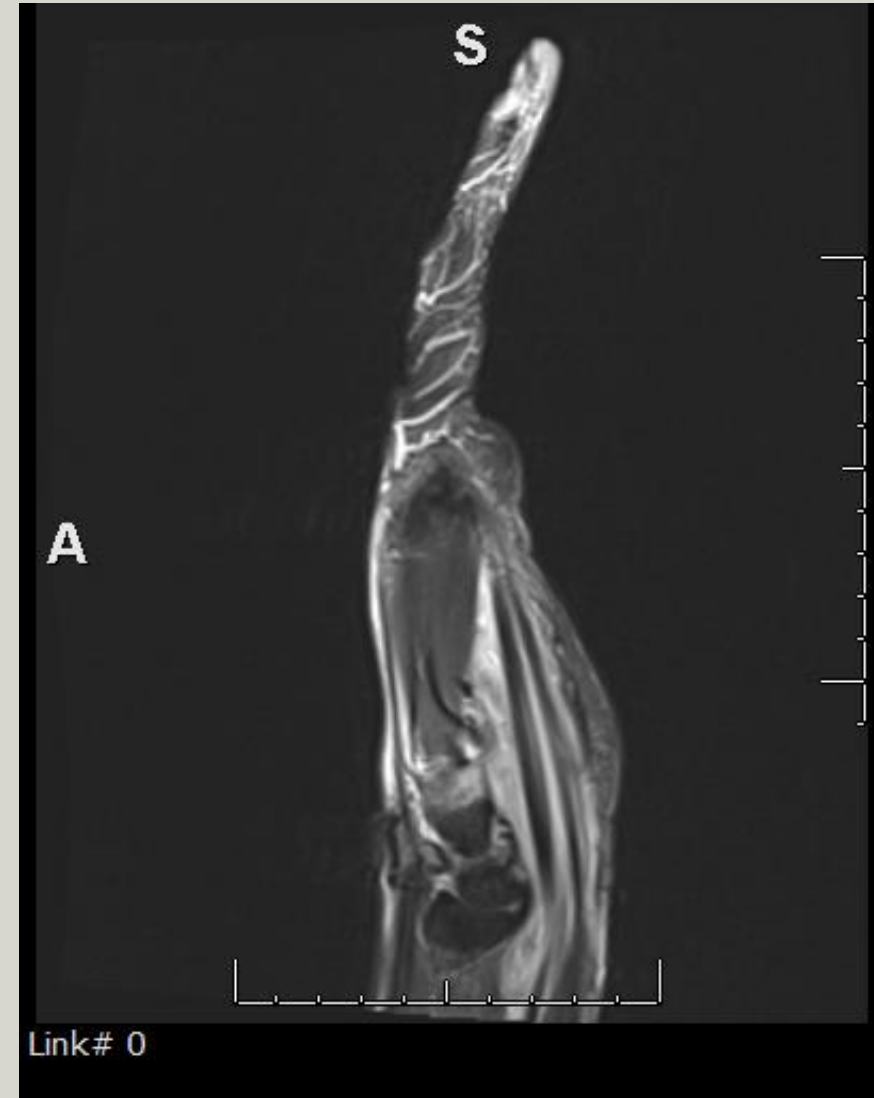

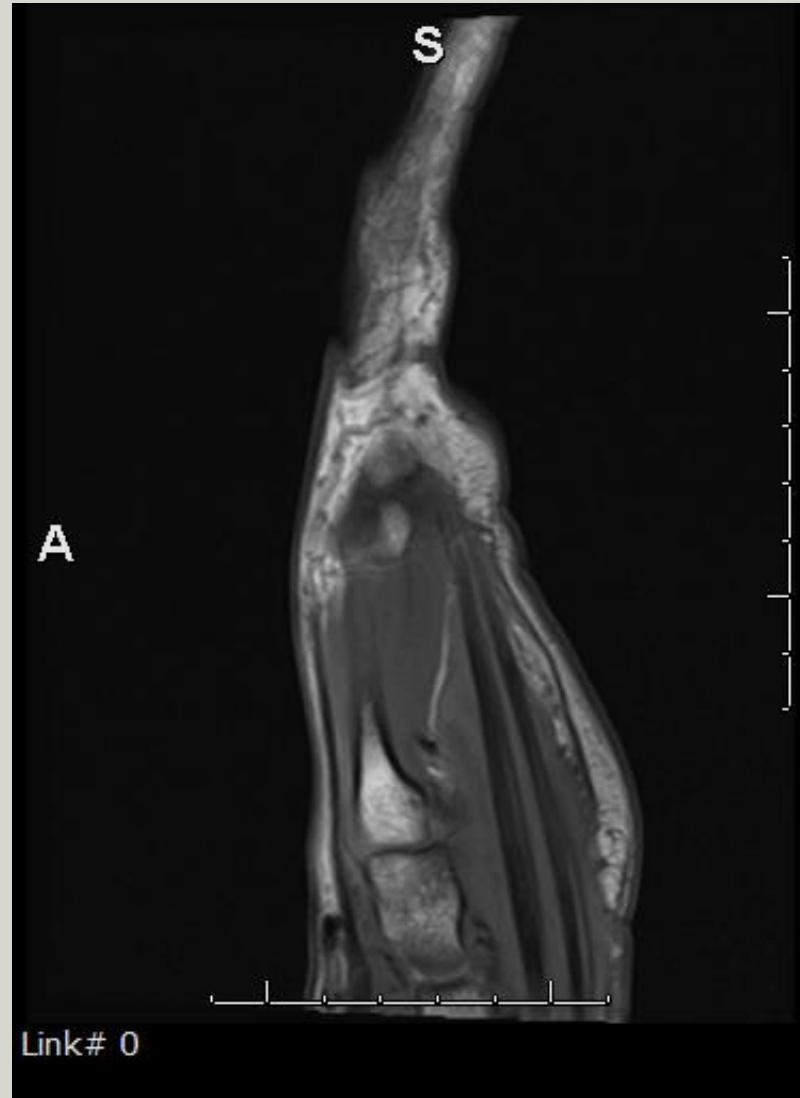
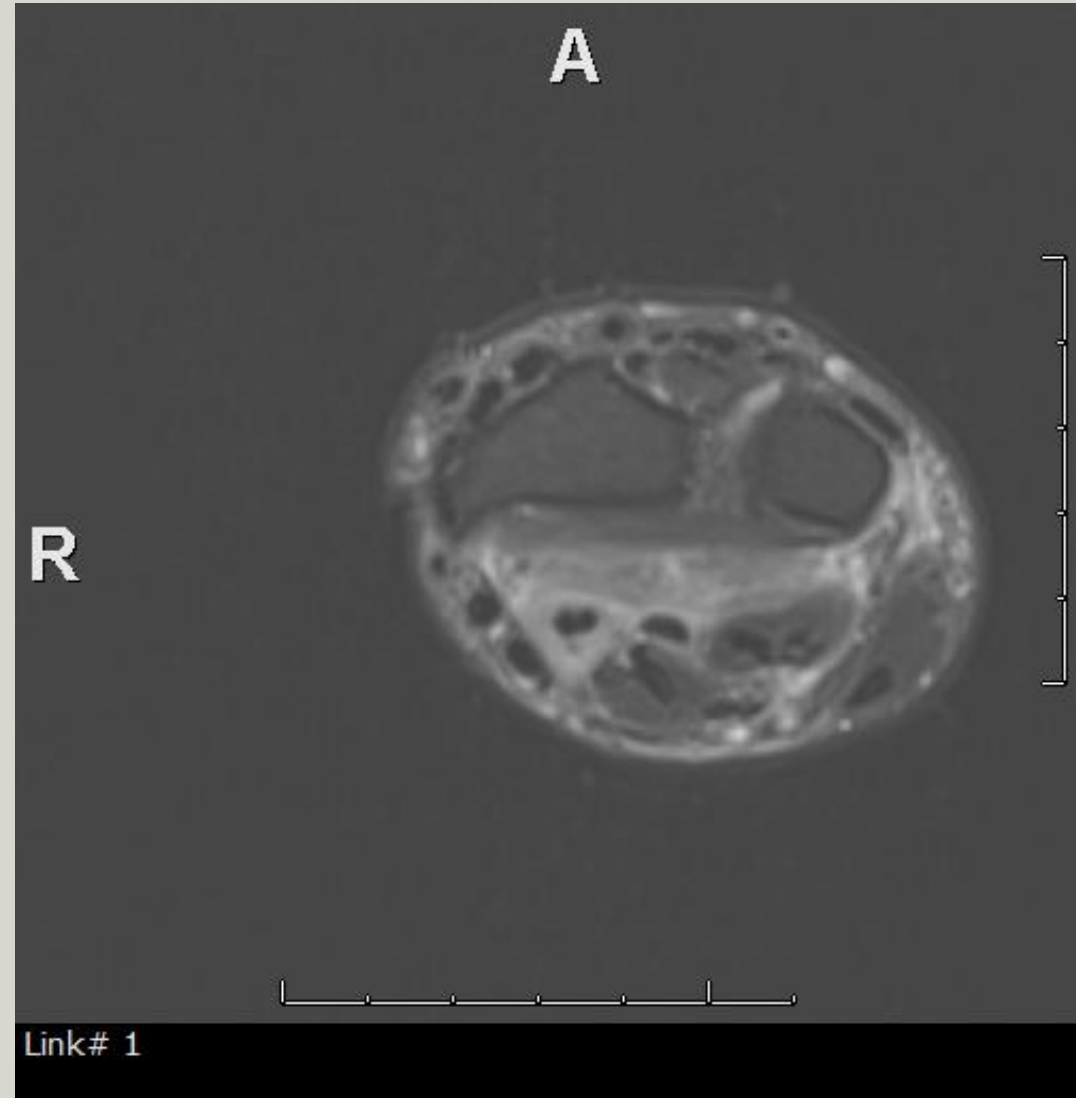
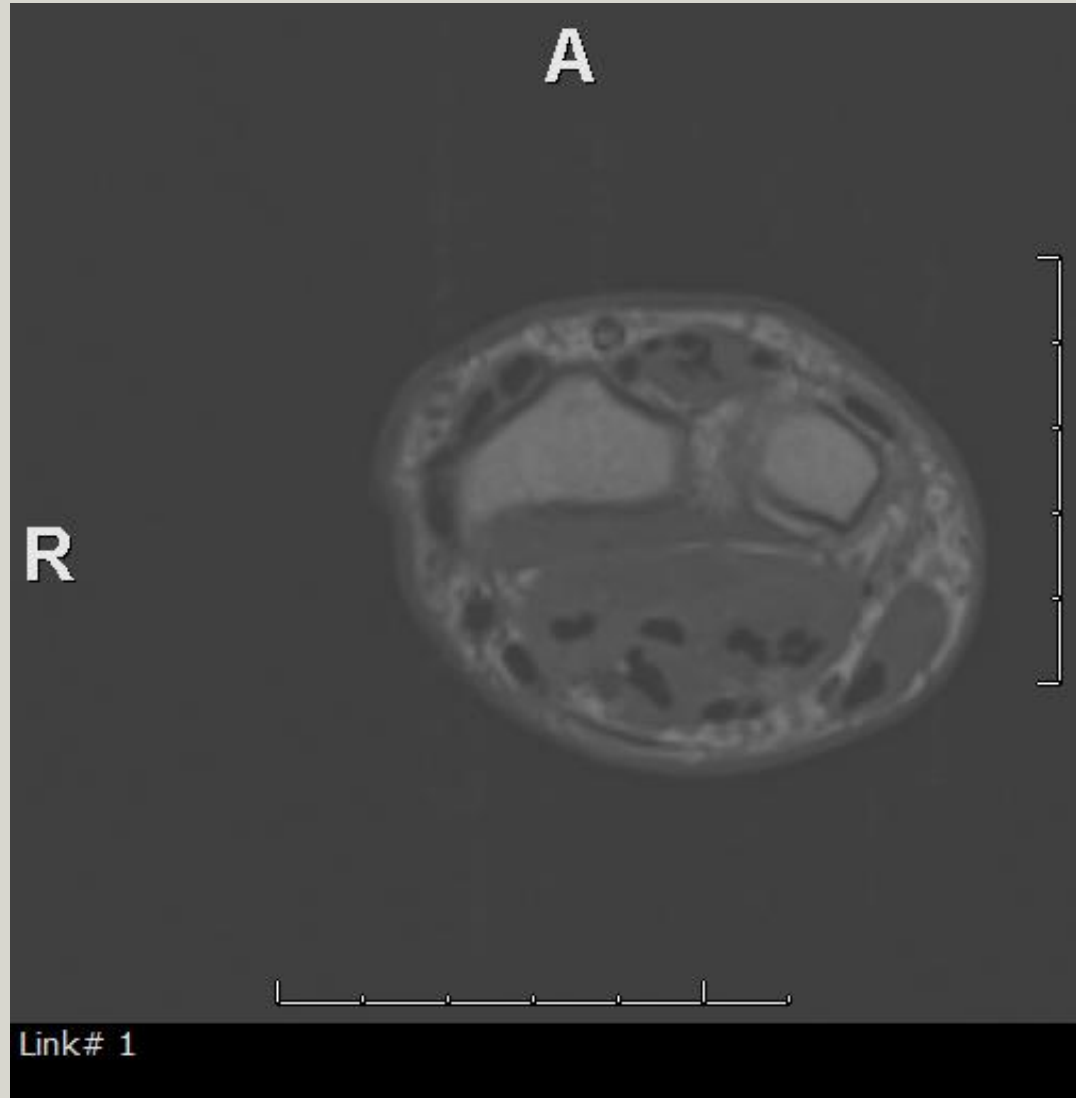
fsT2W

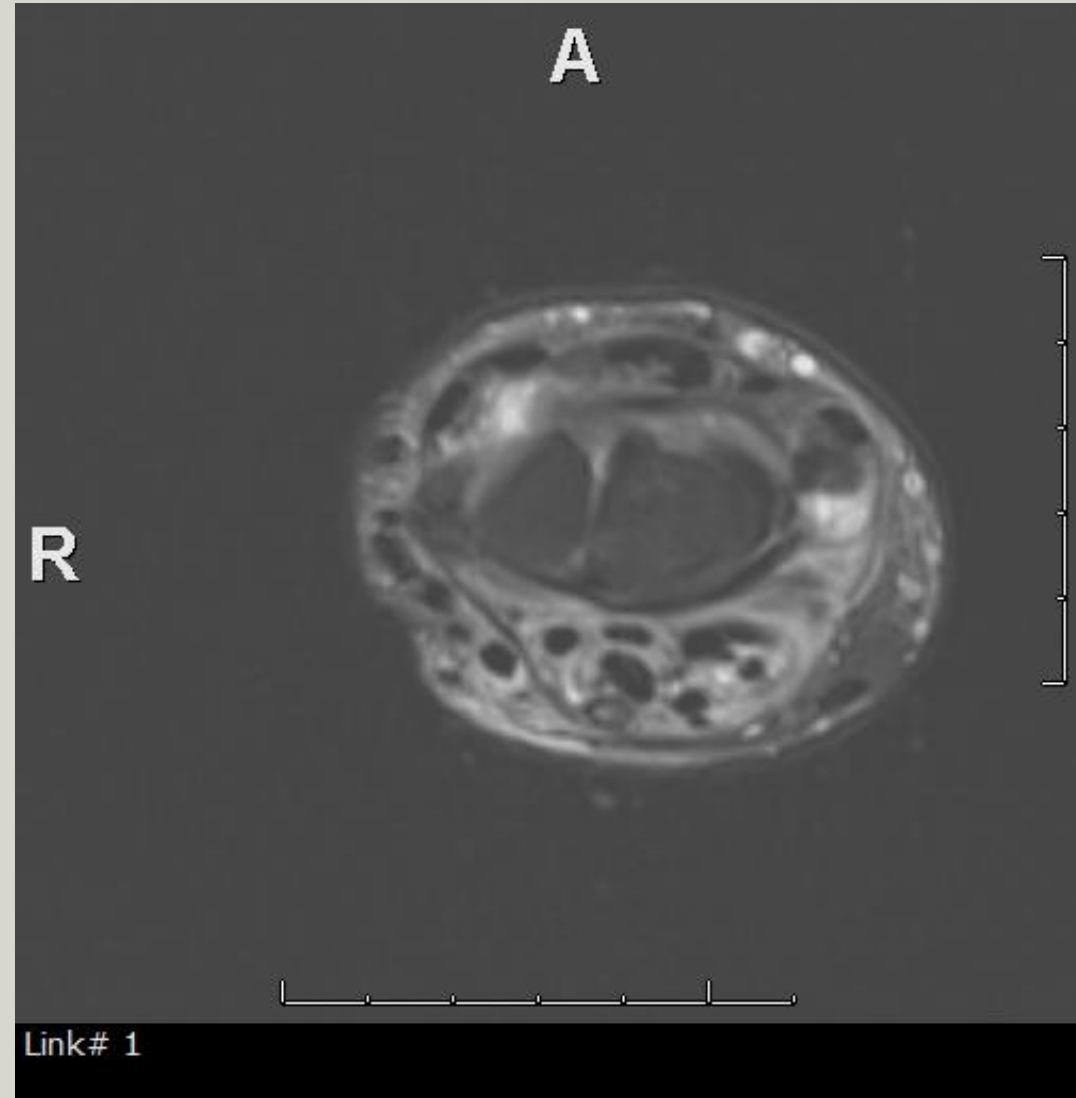
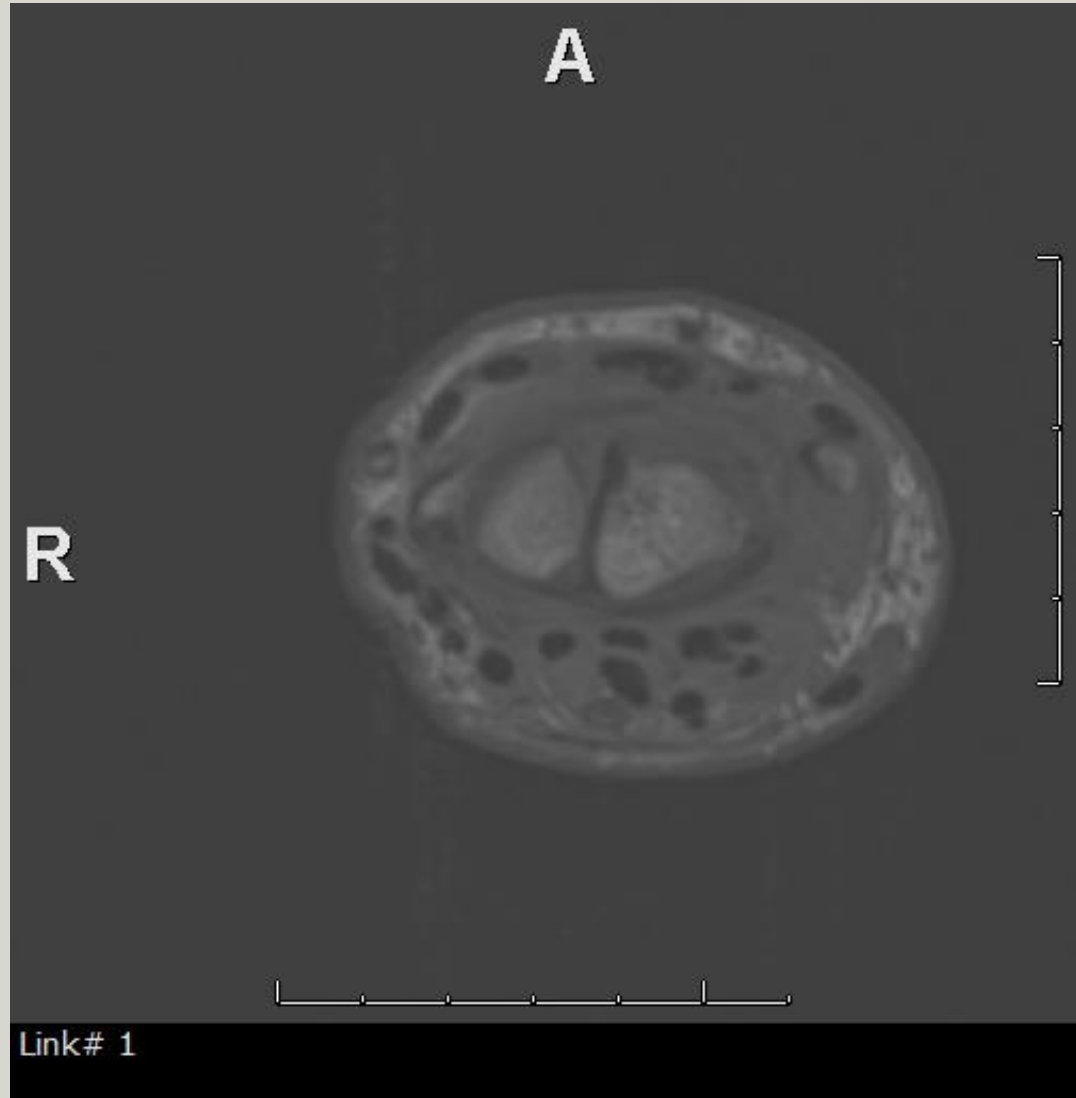

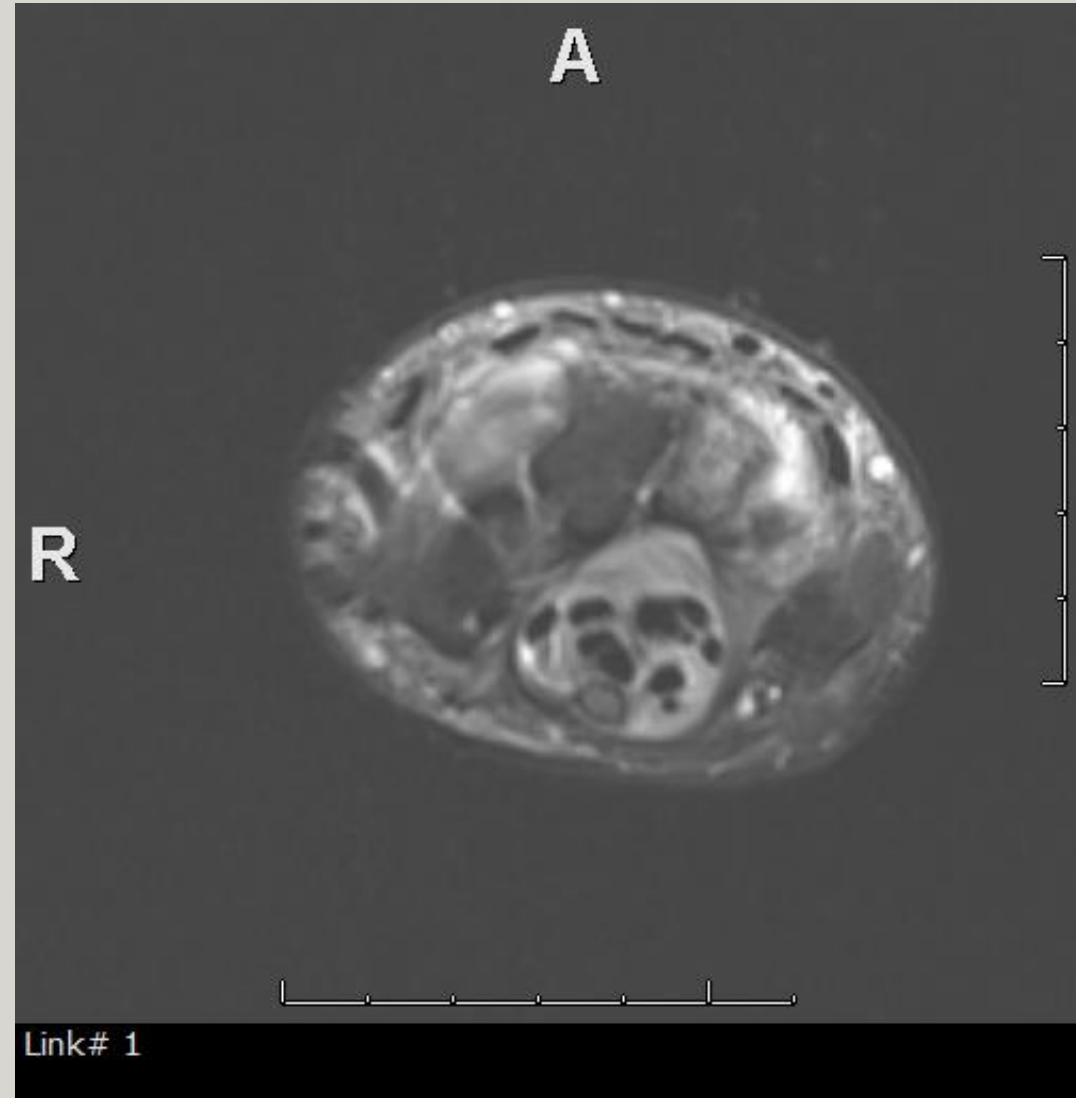
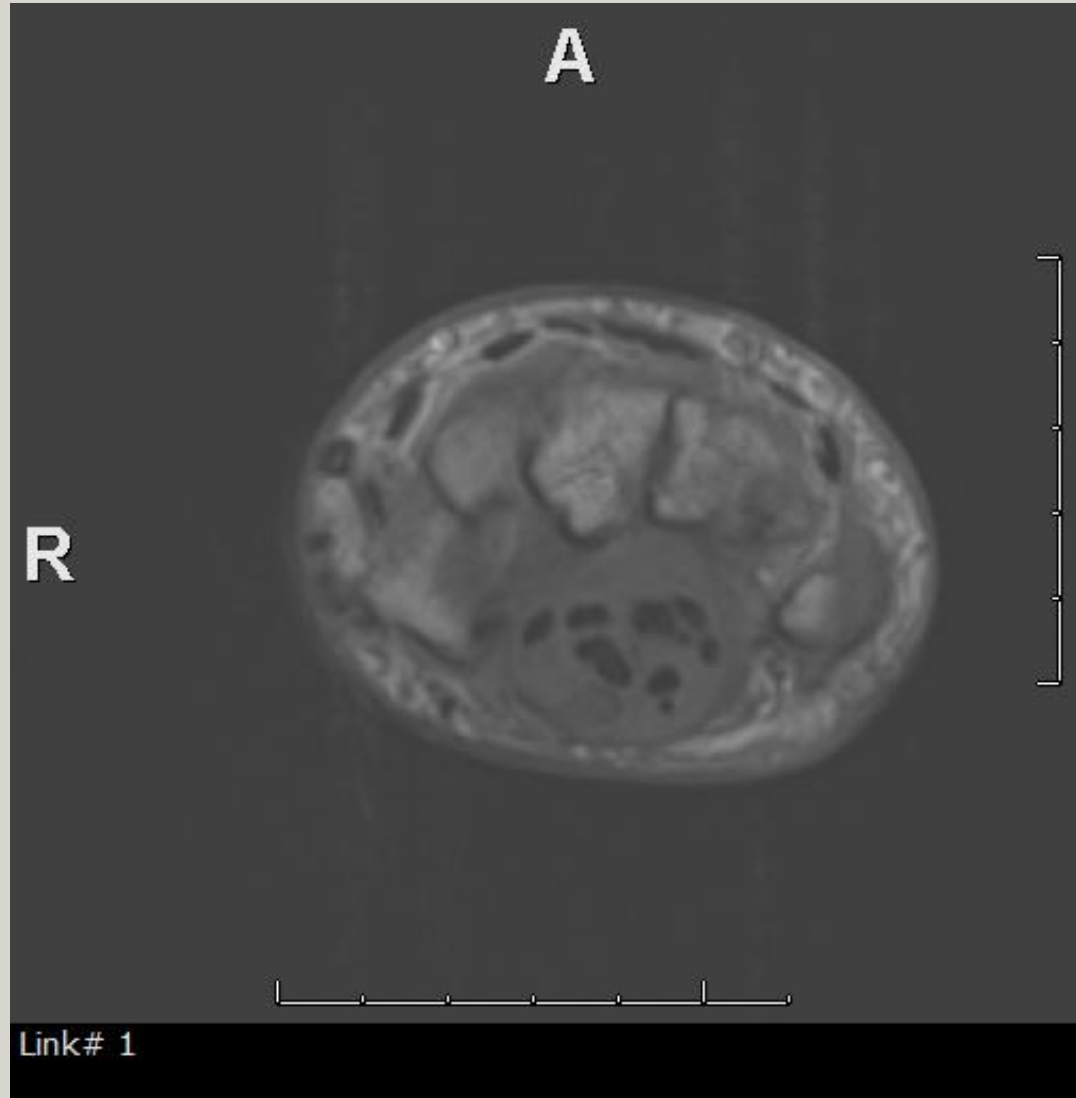


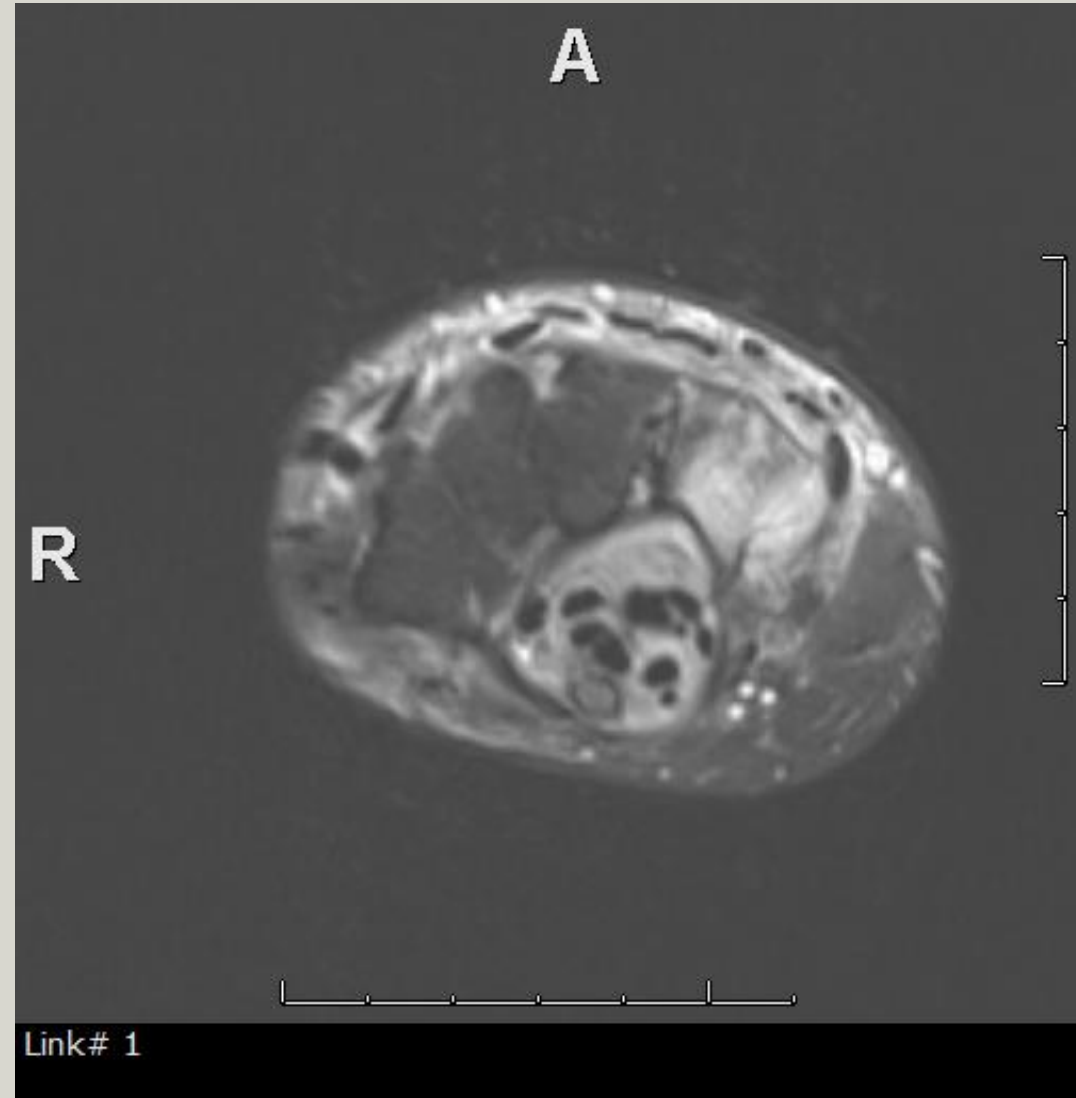

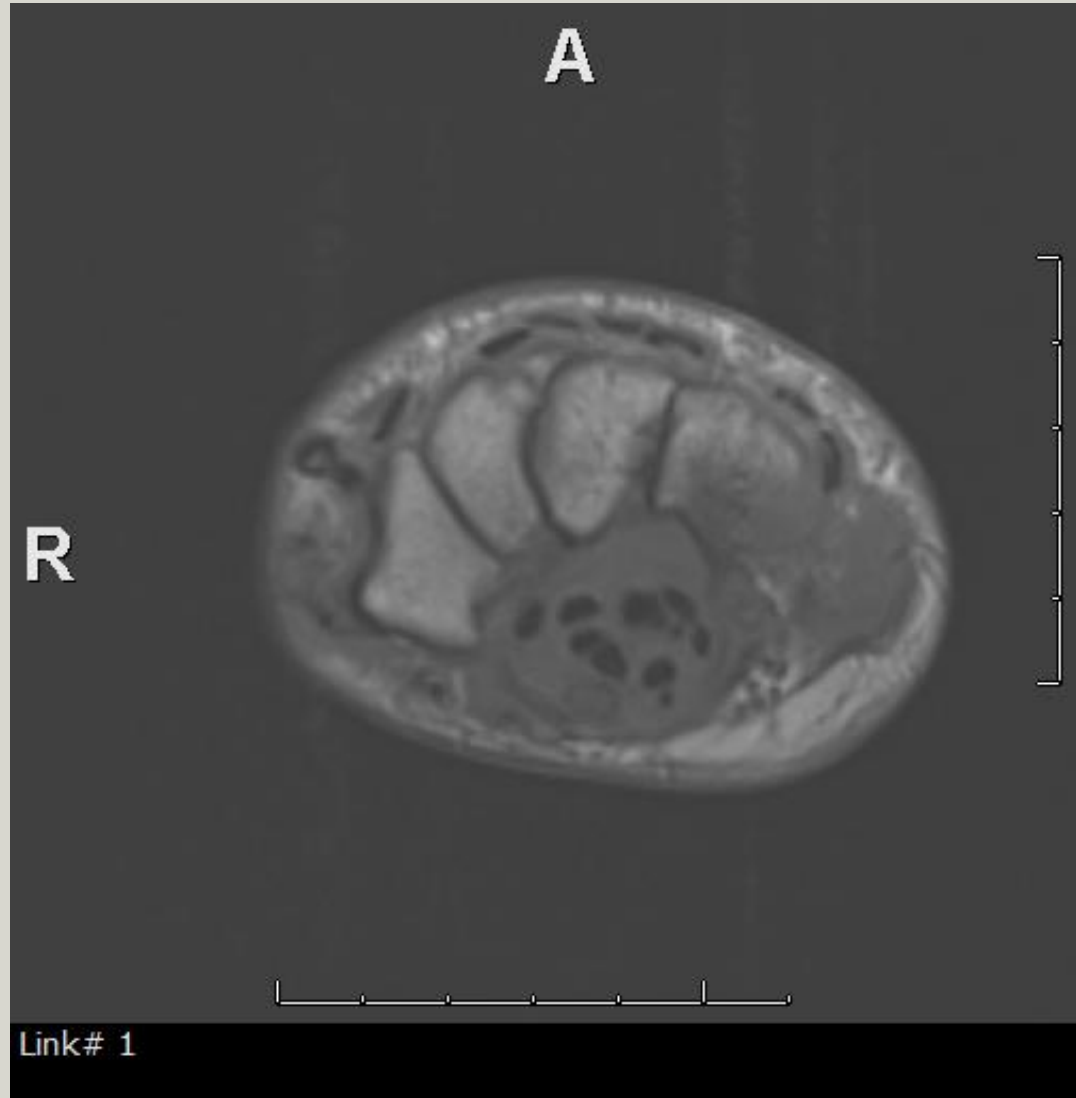
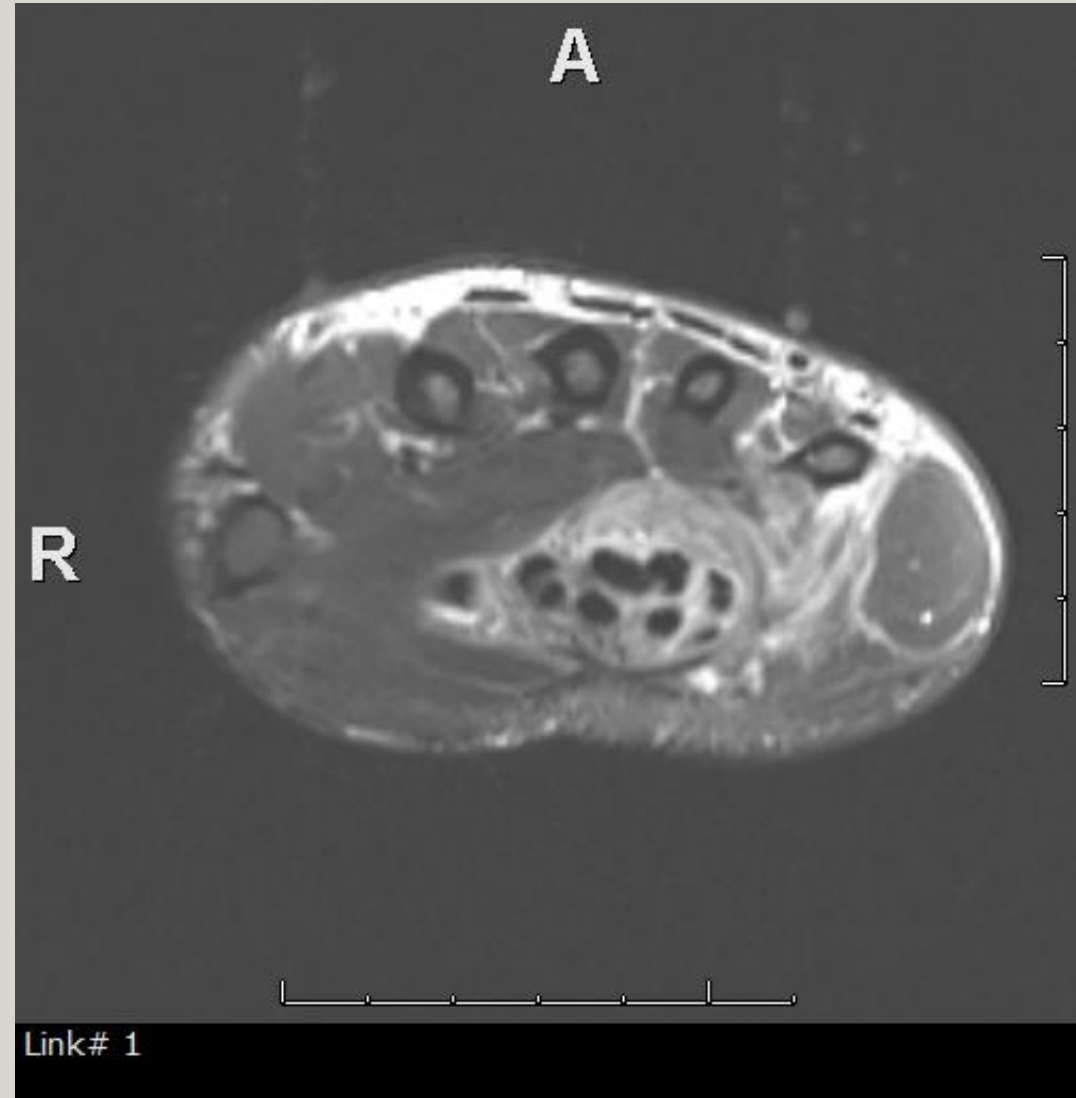
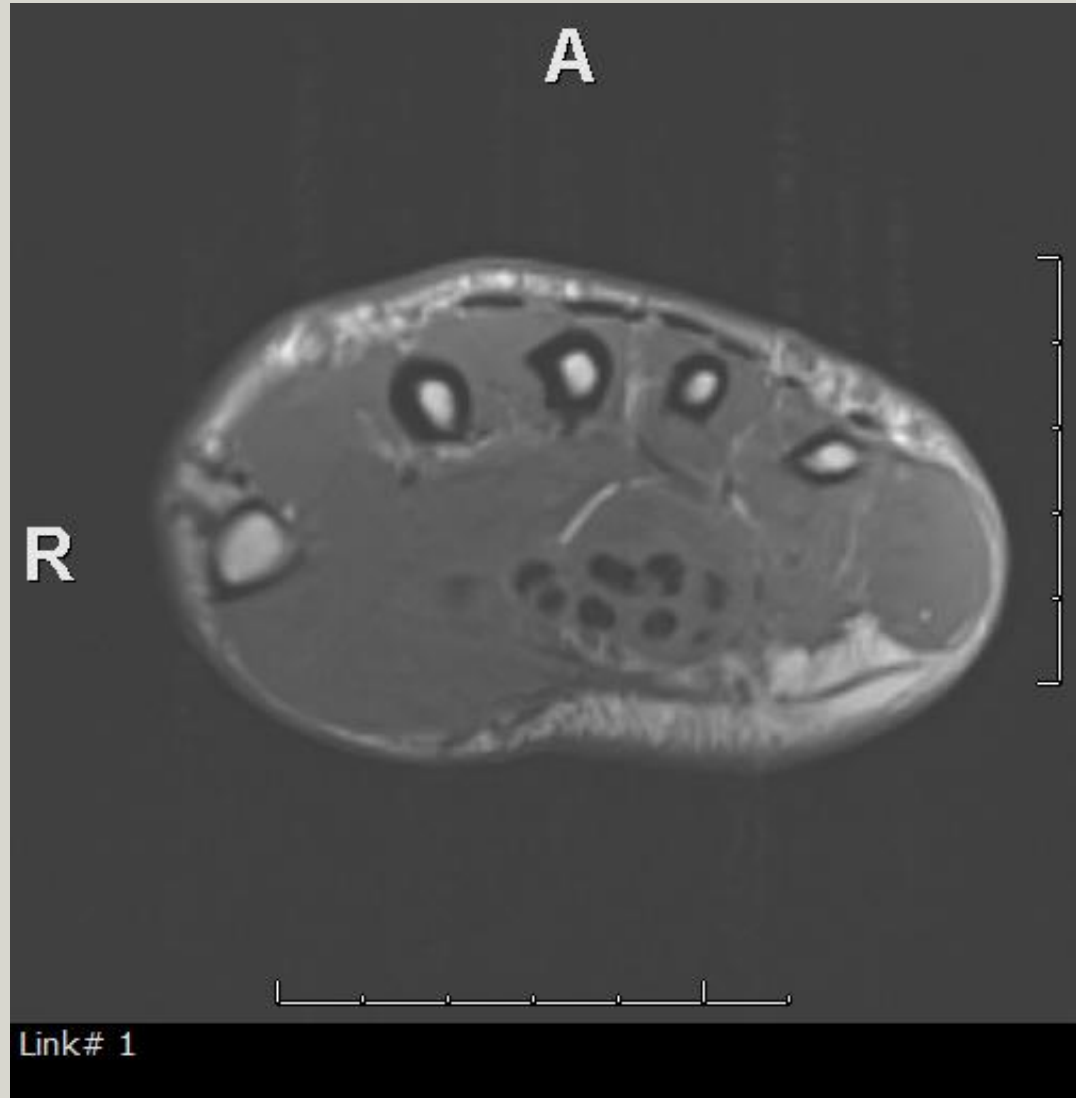


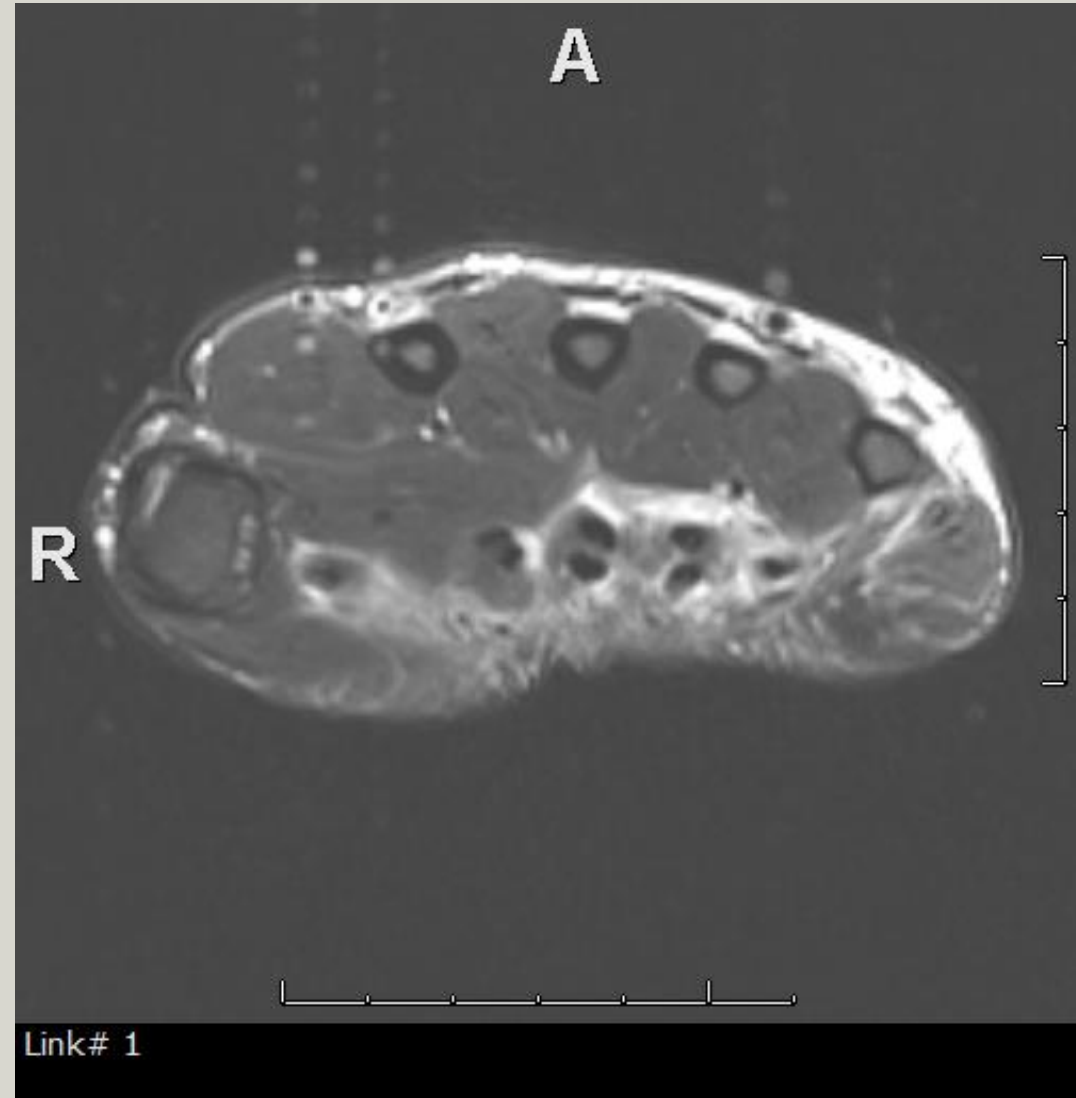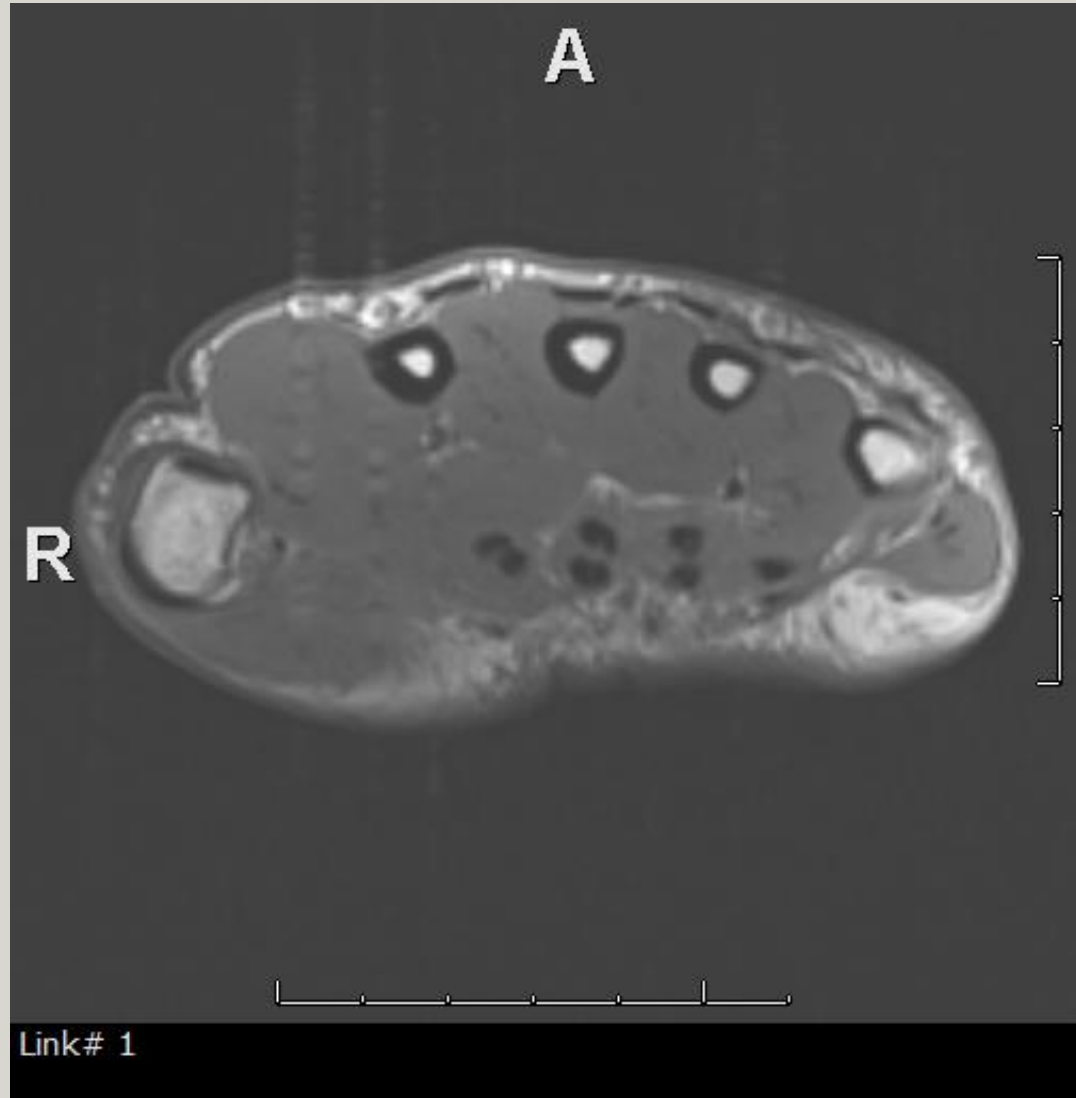




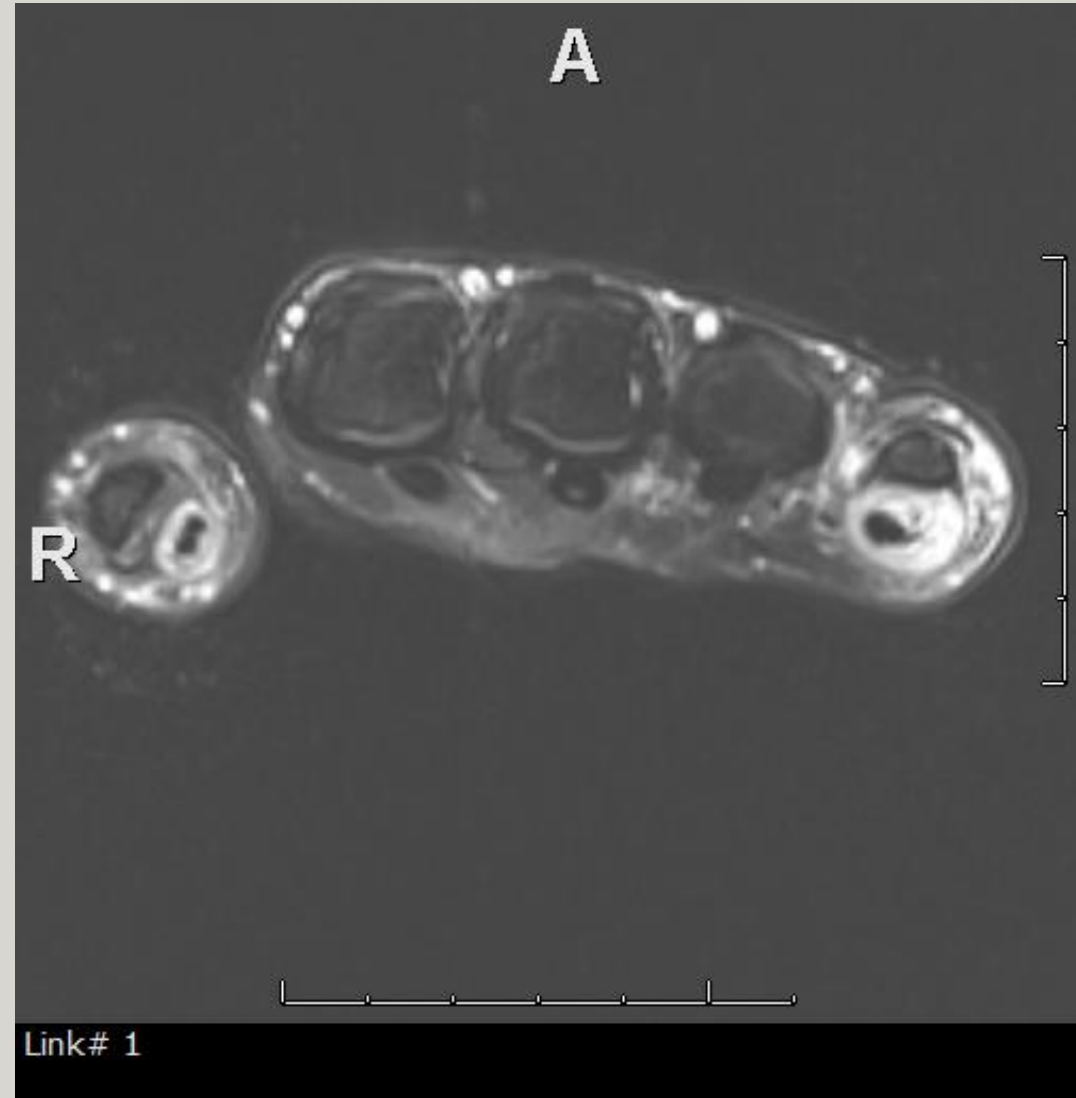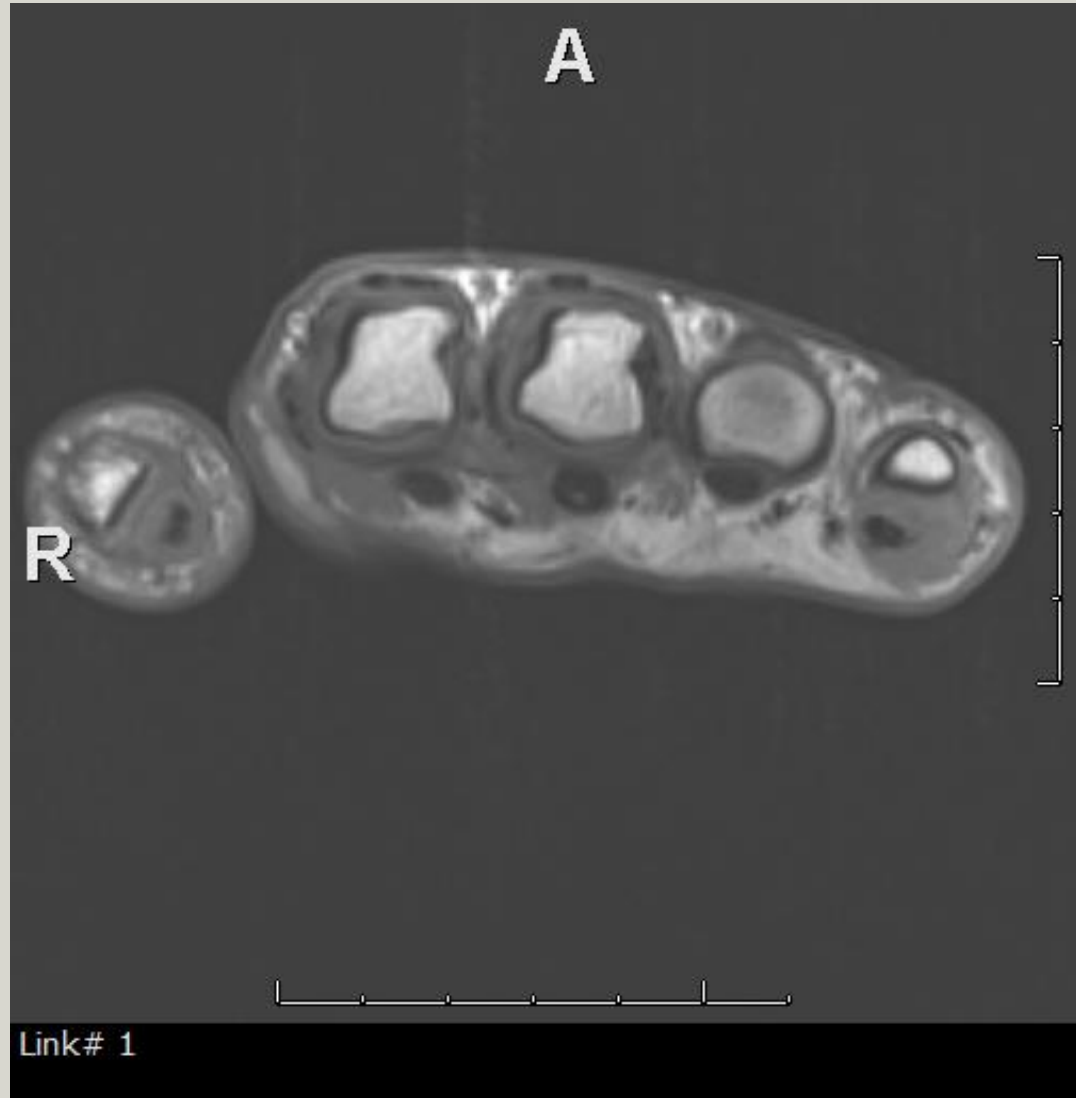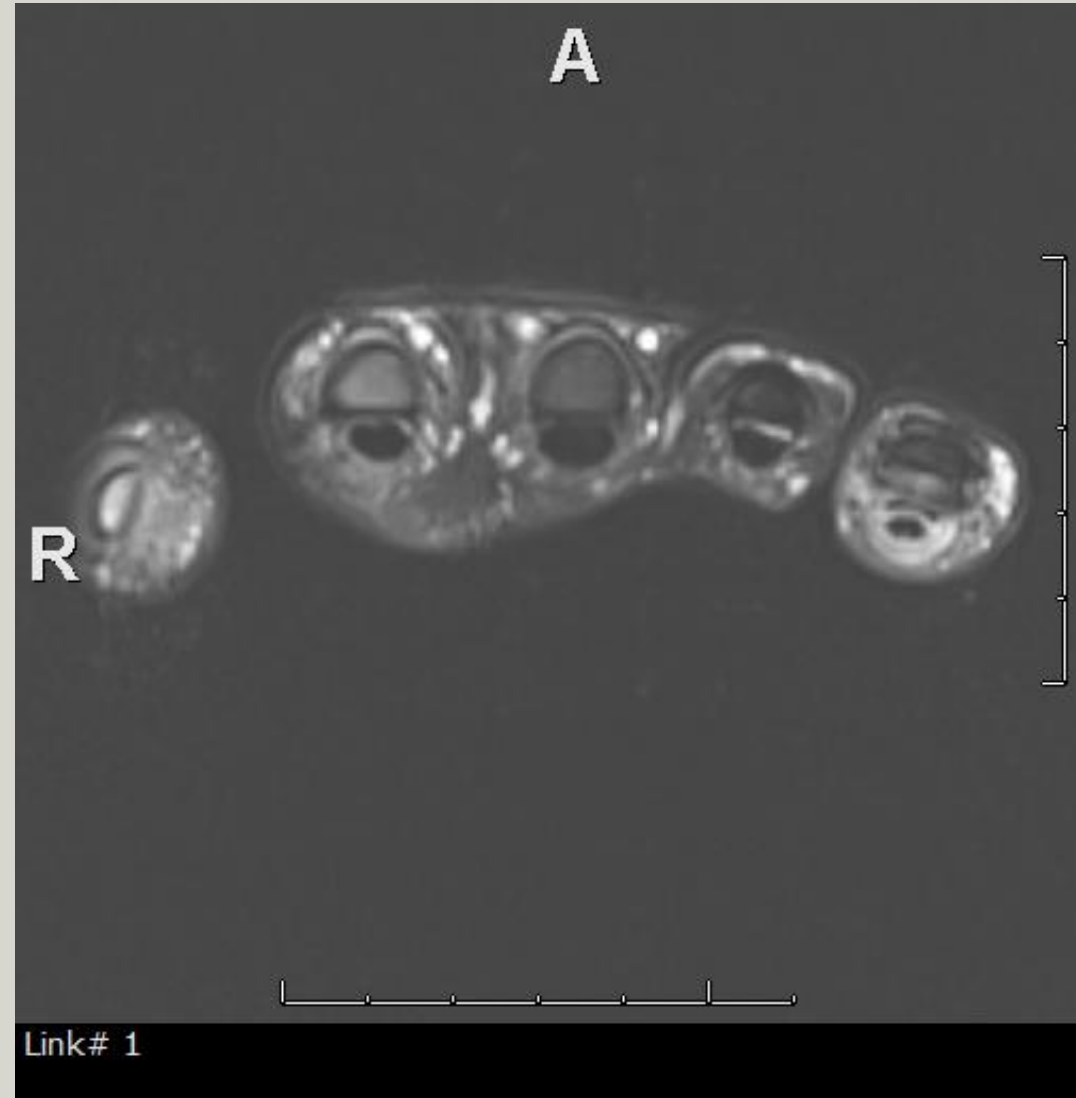
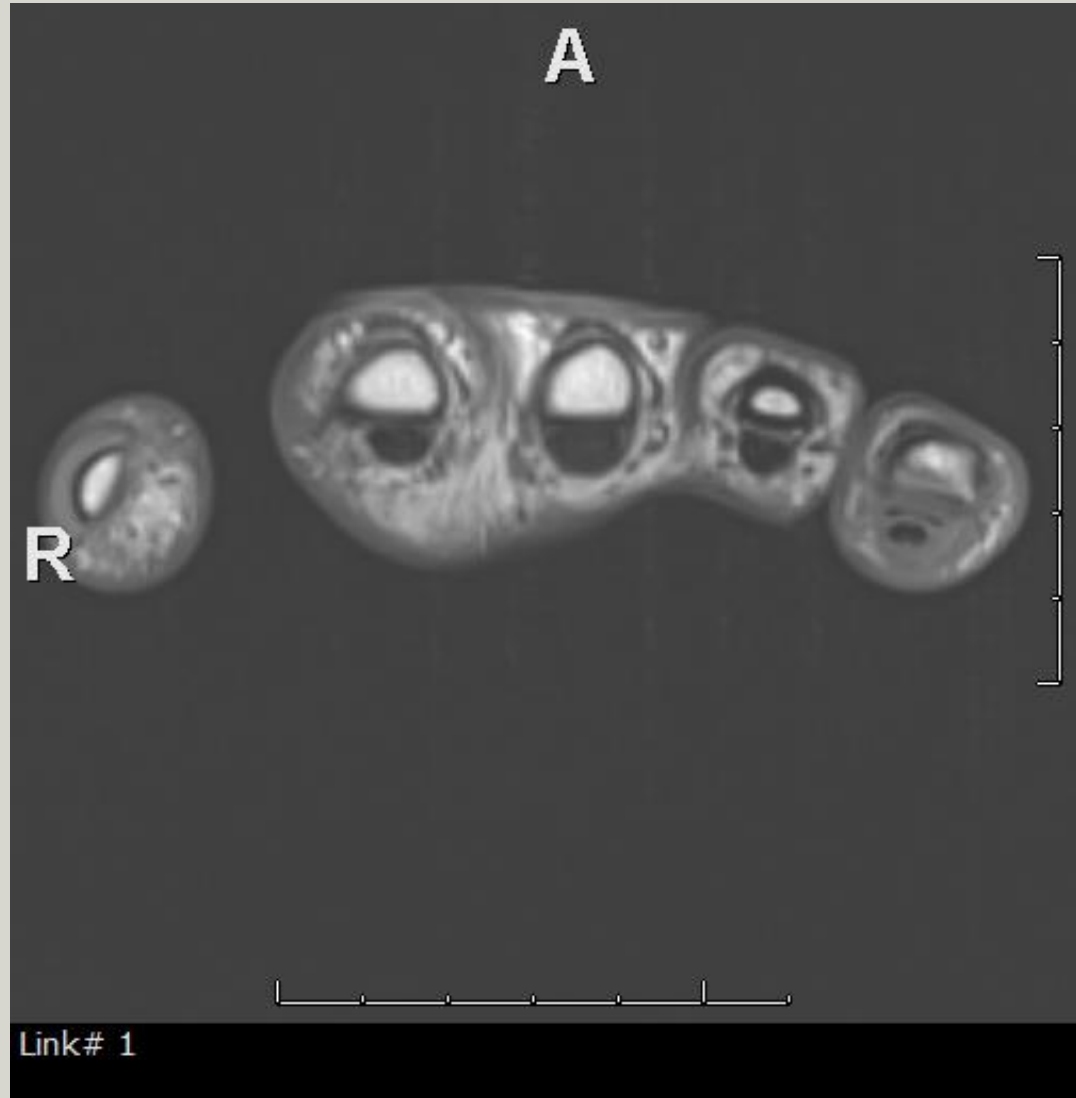




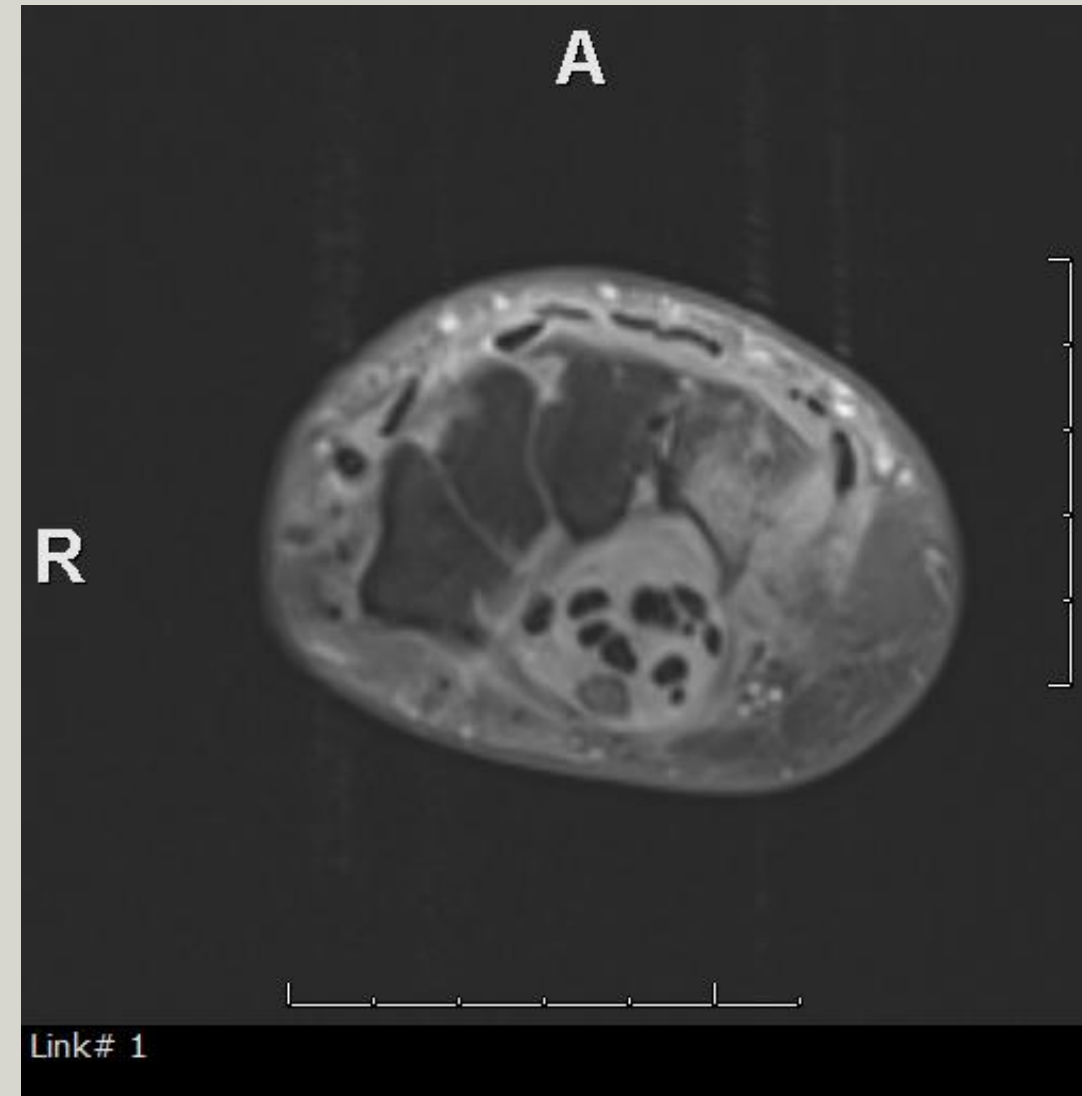
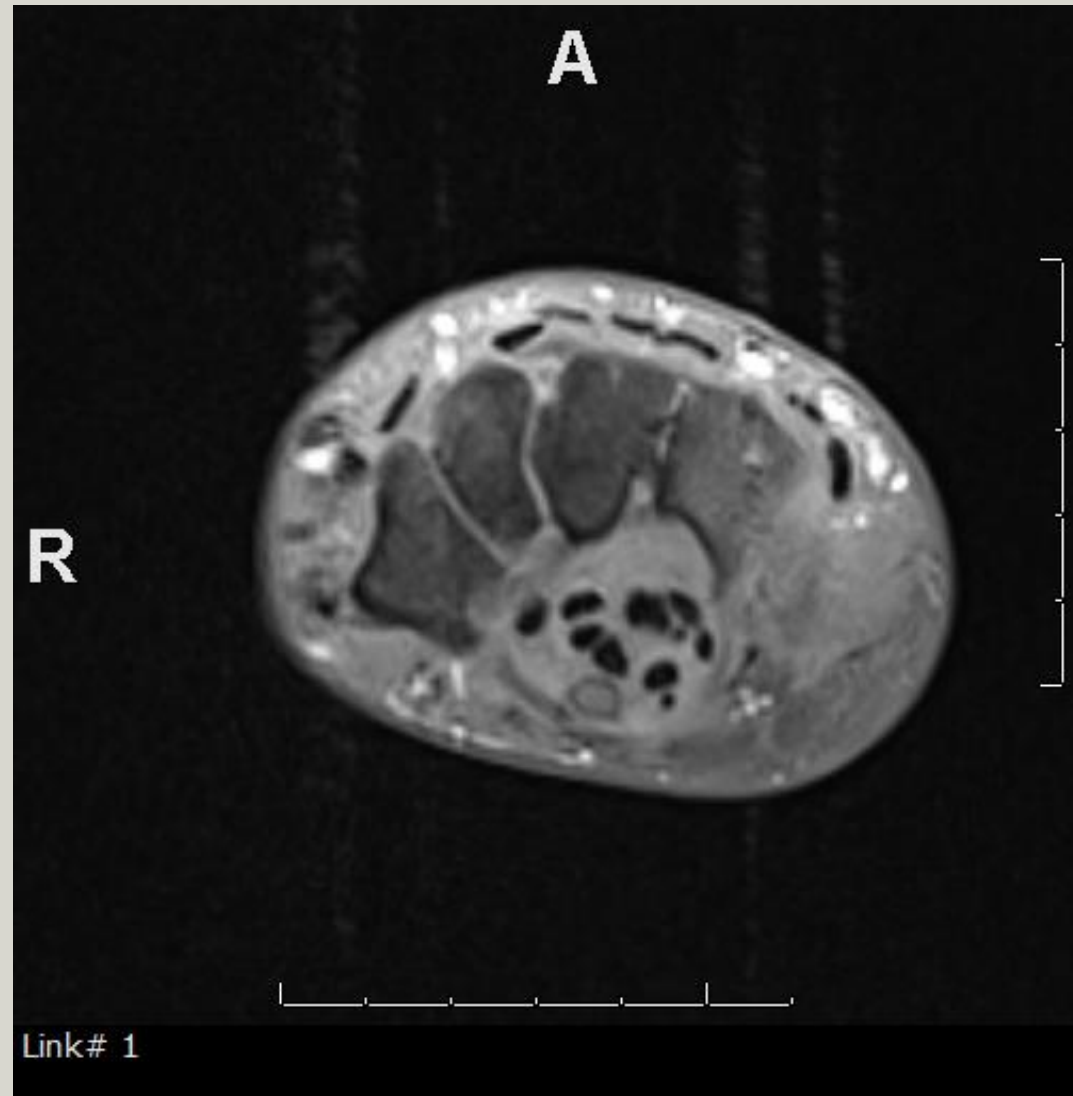


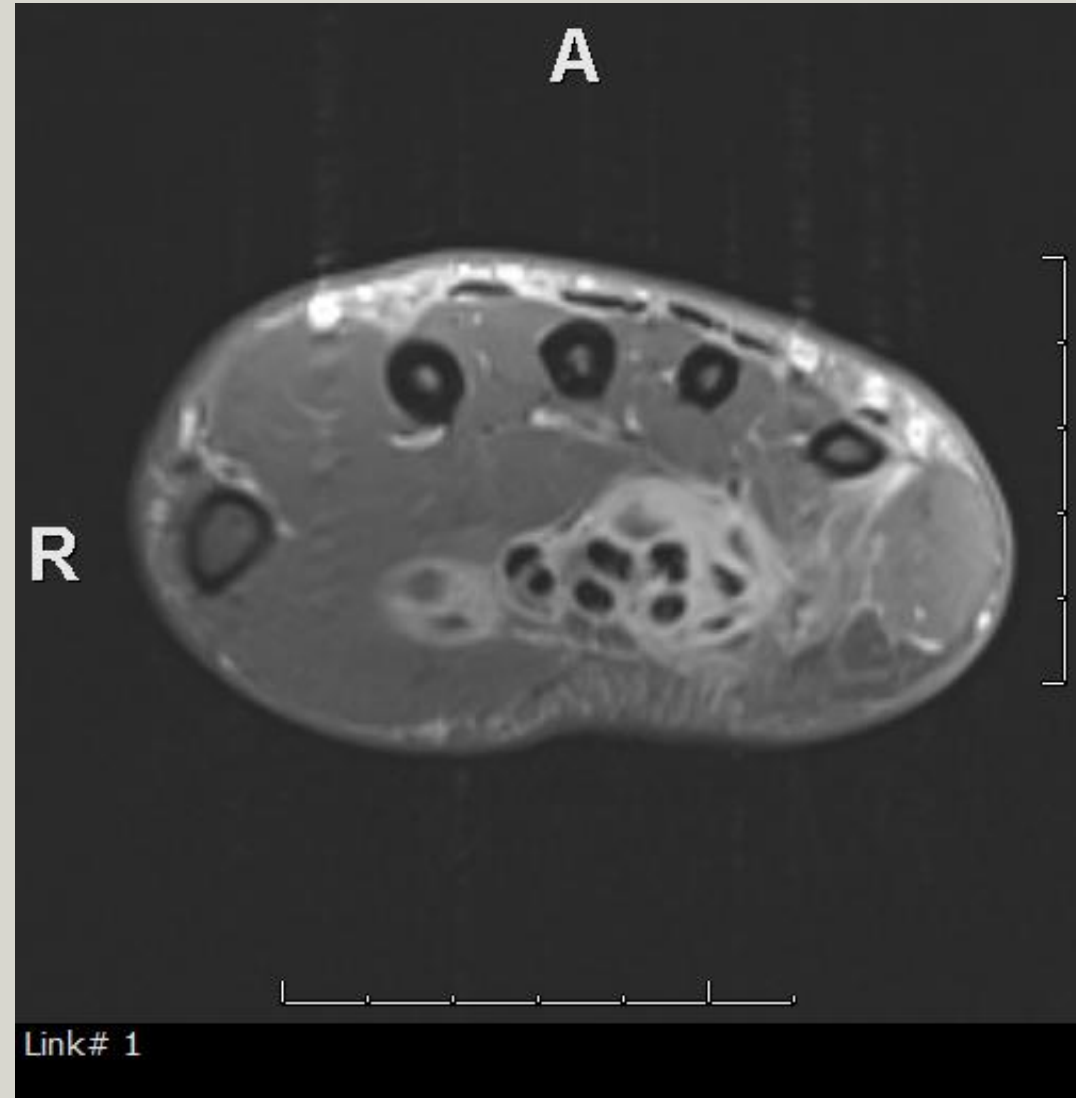




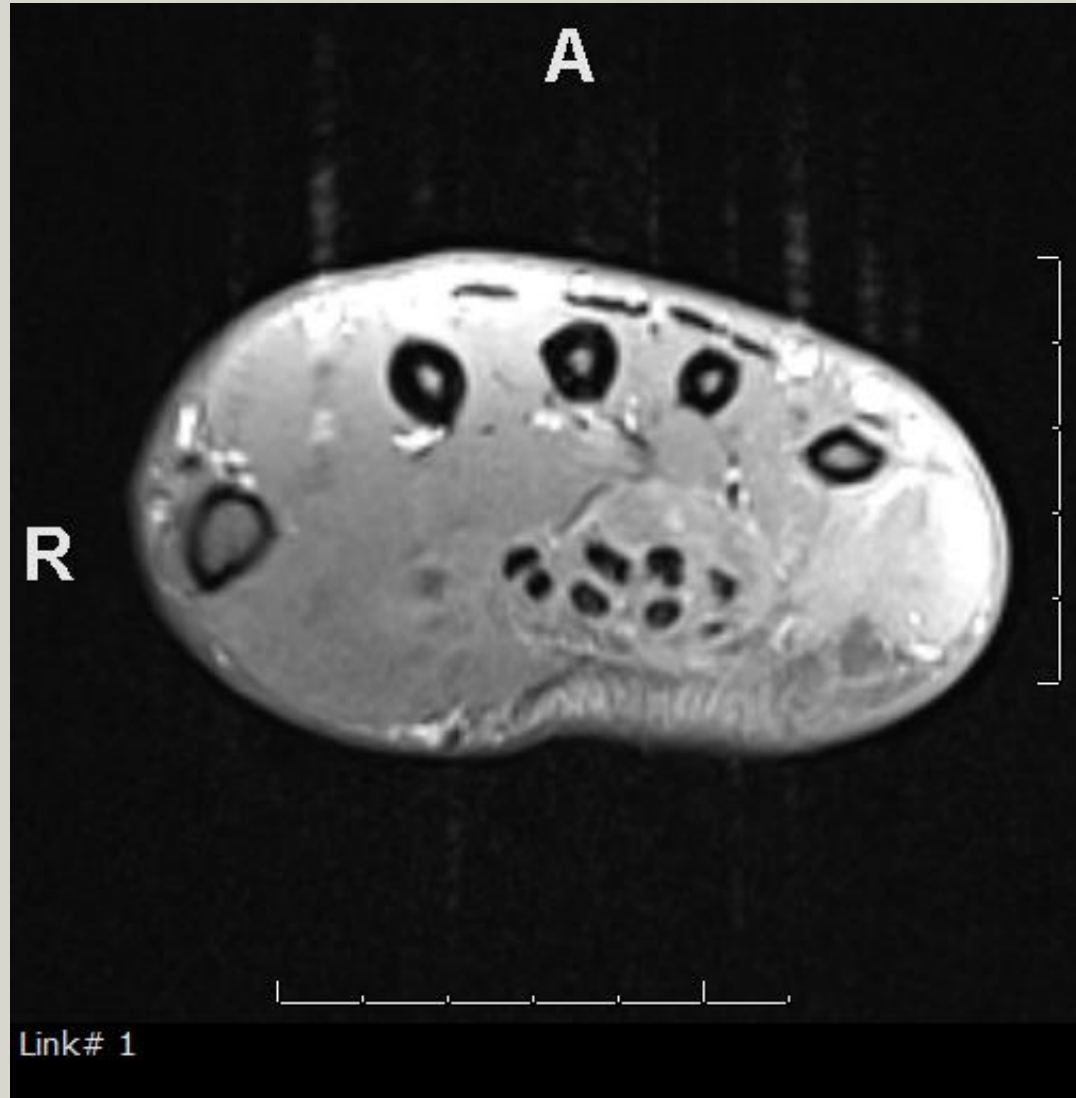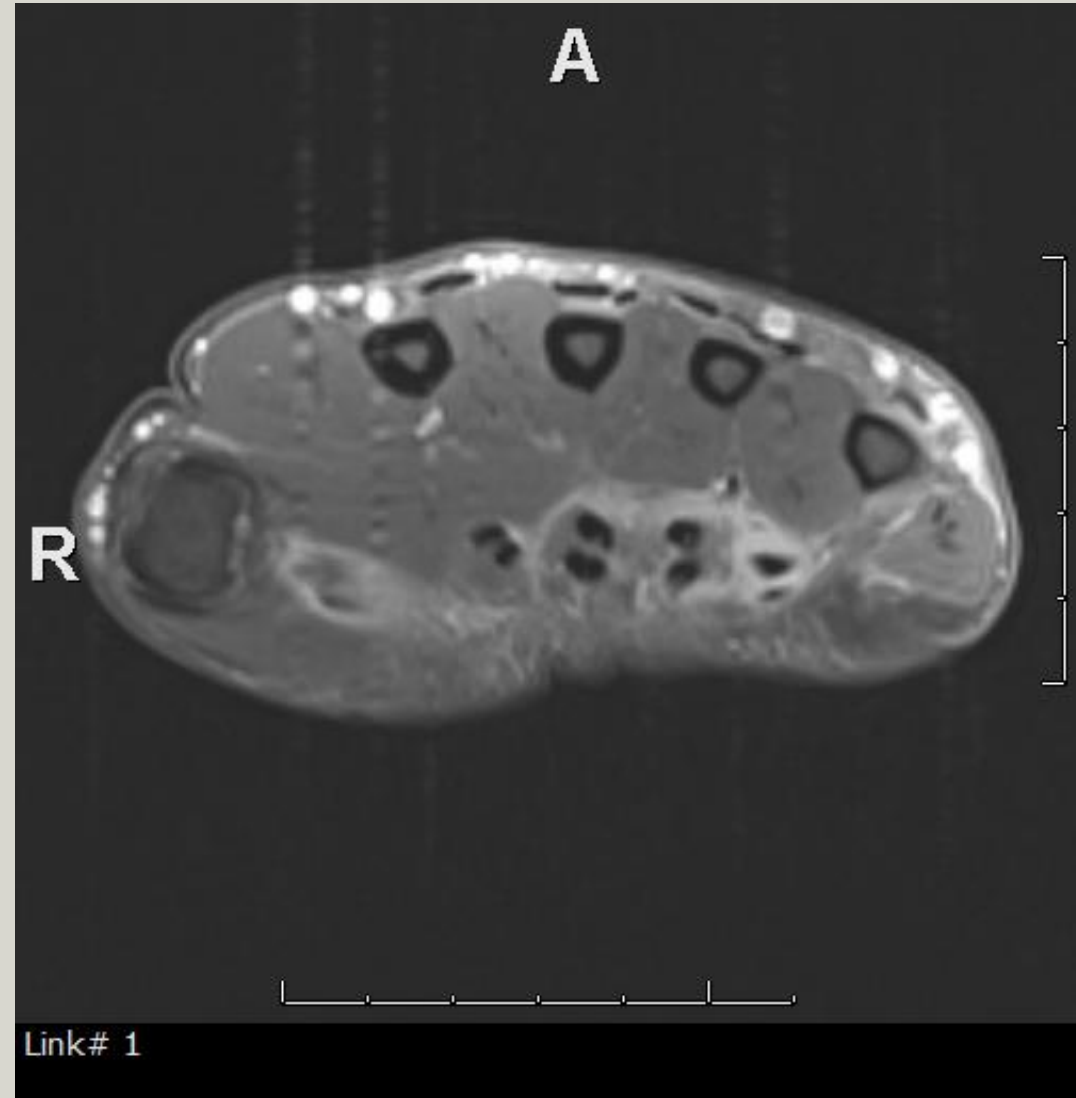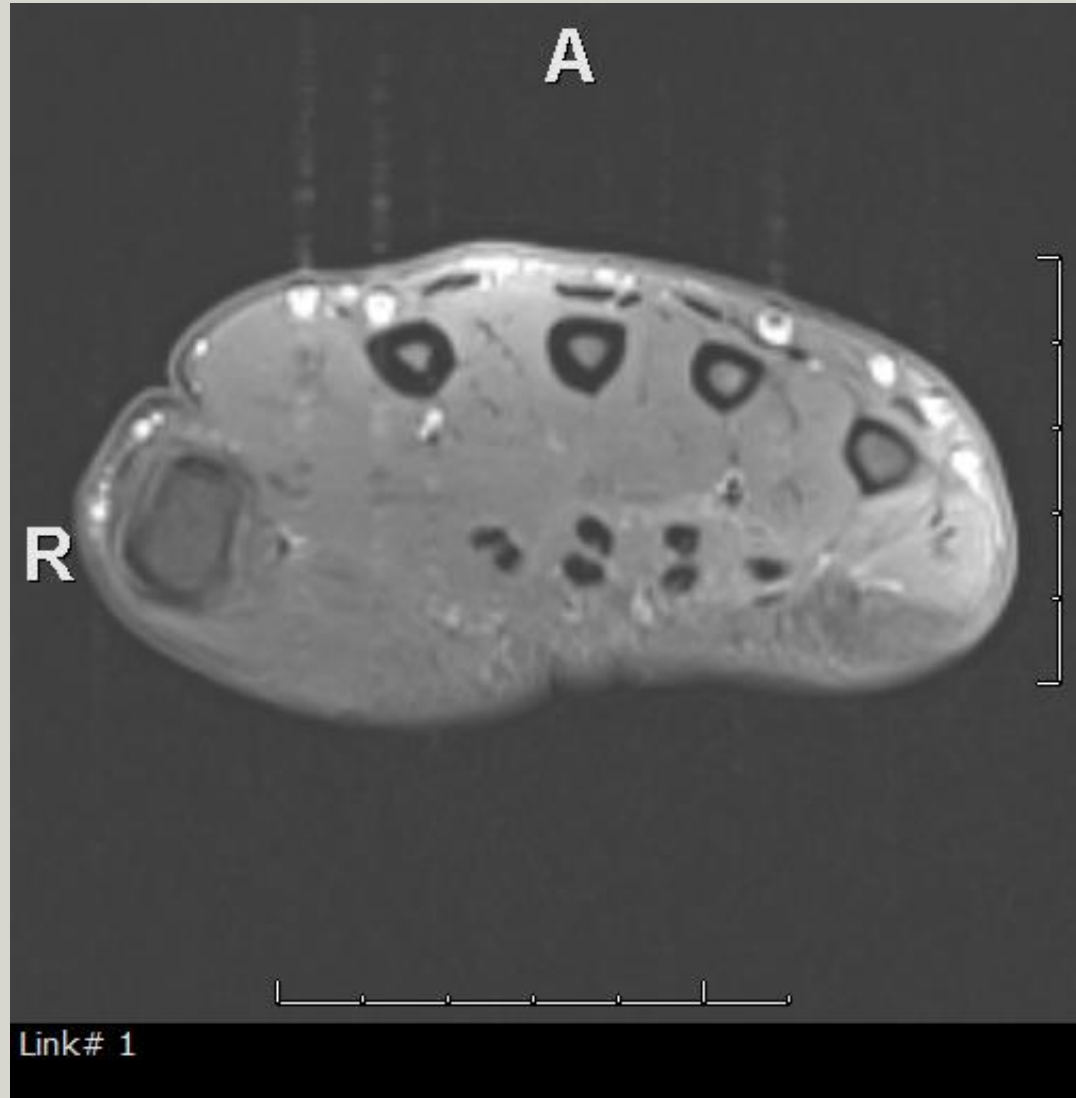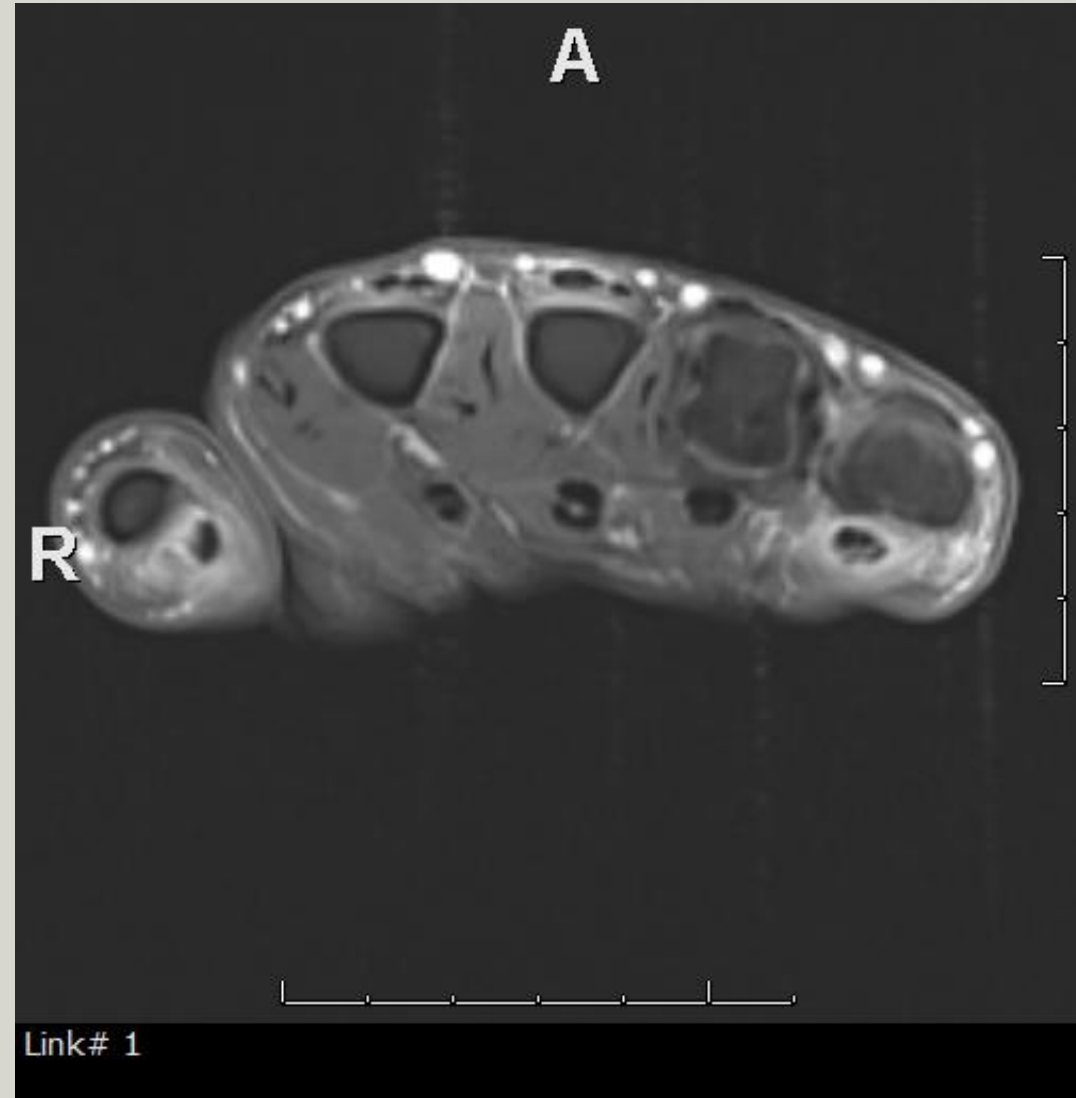


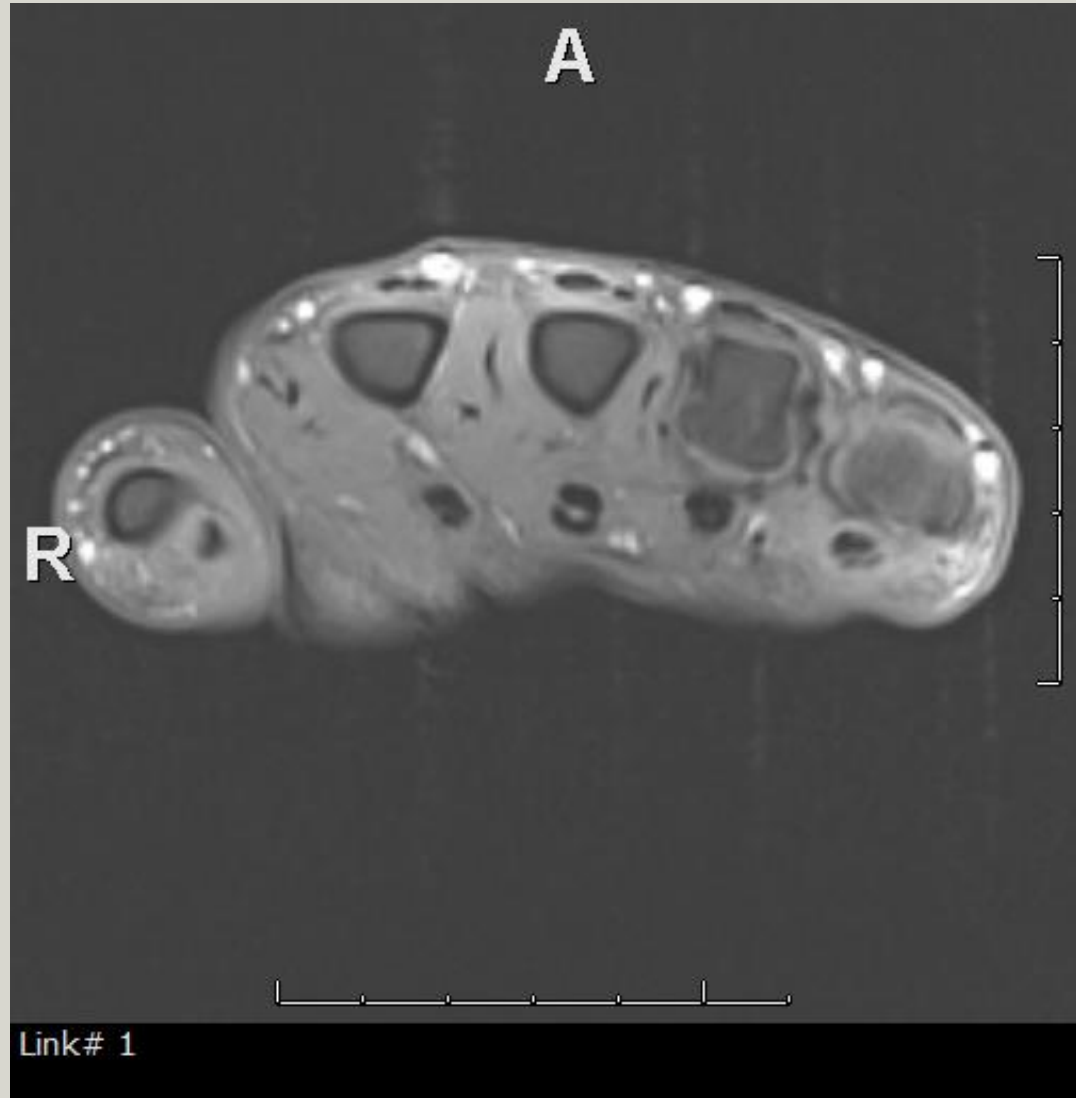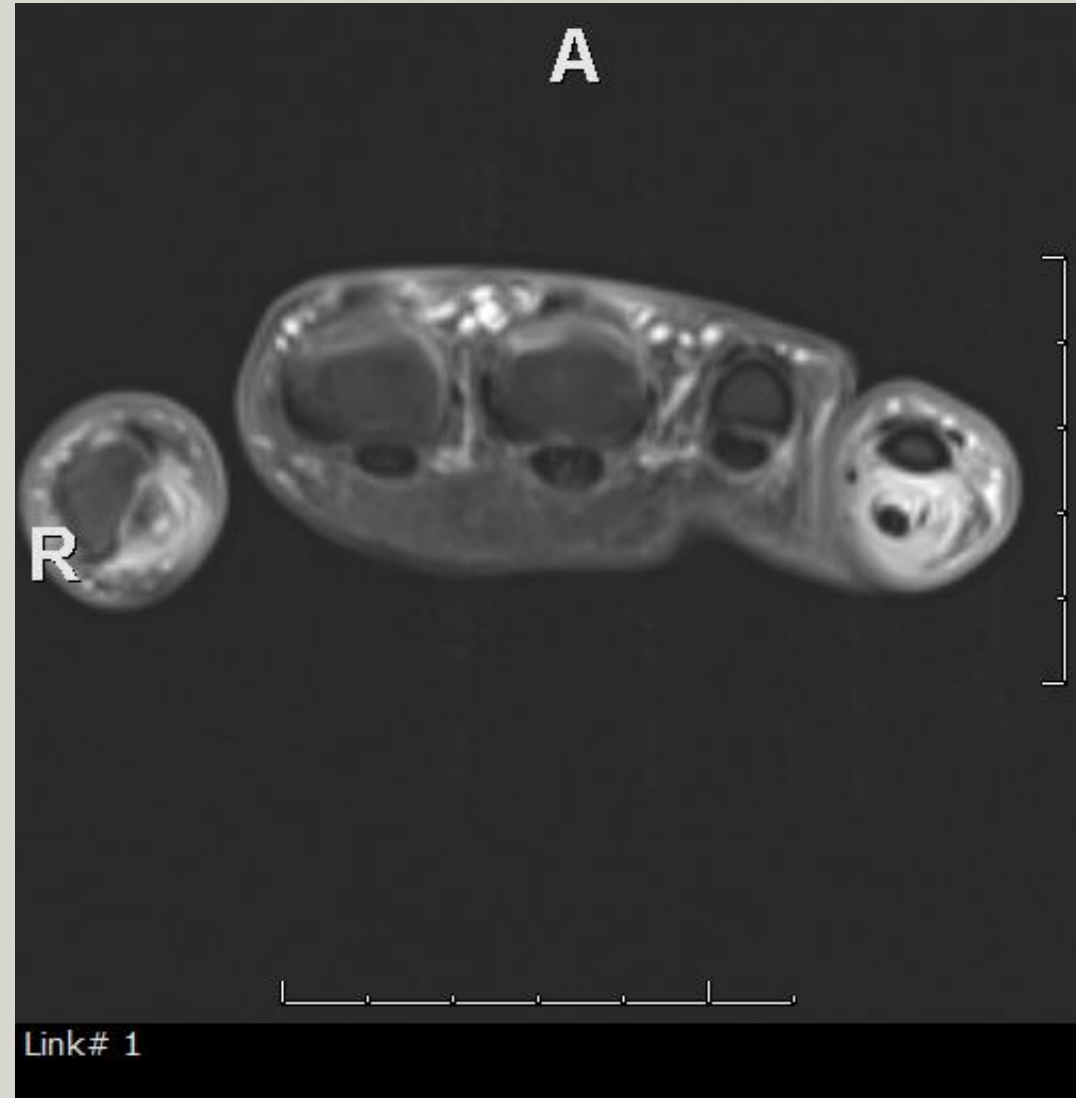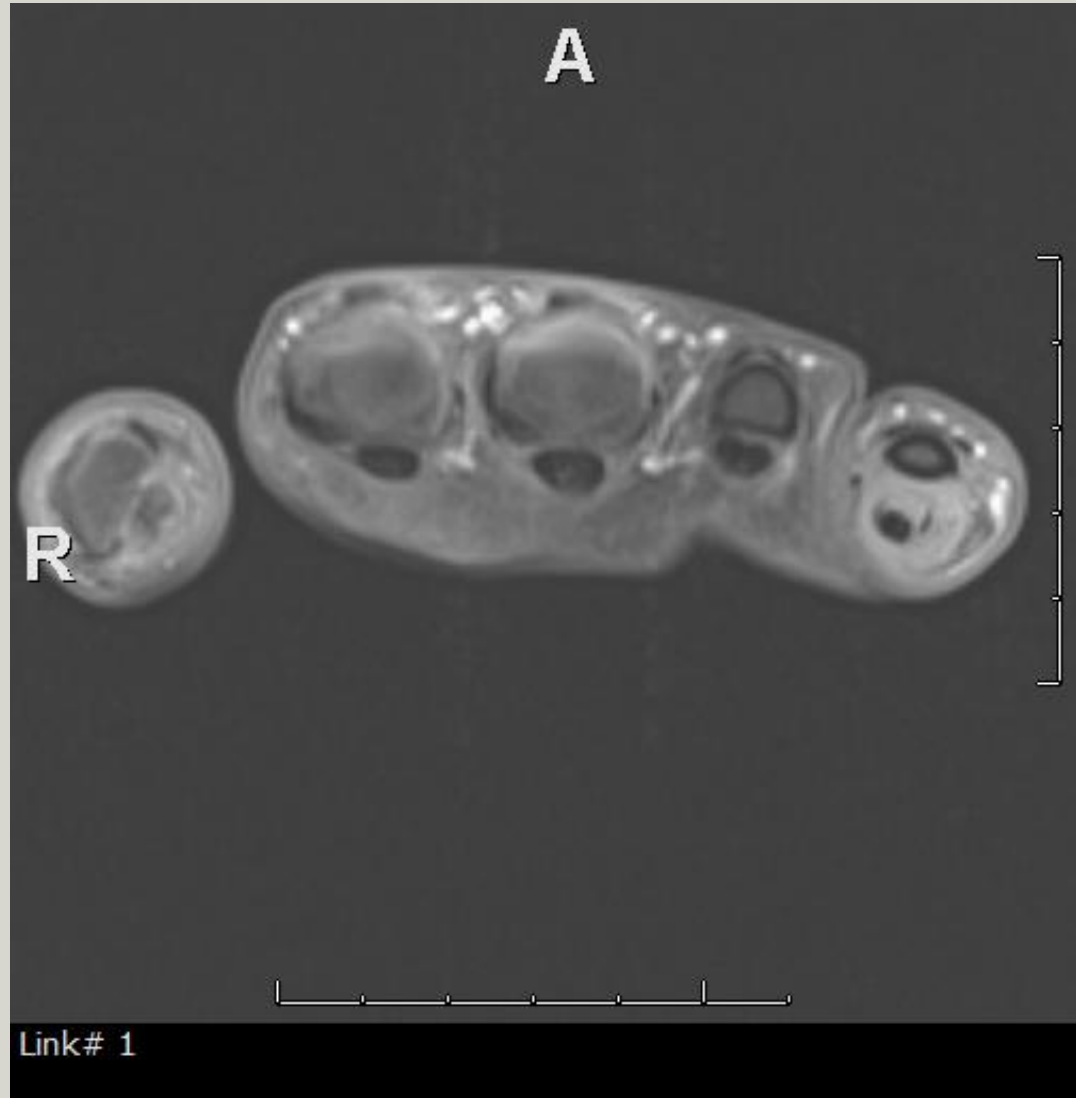Pre- and post

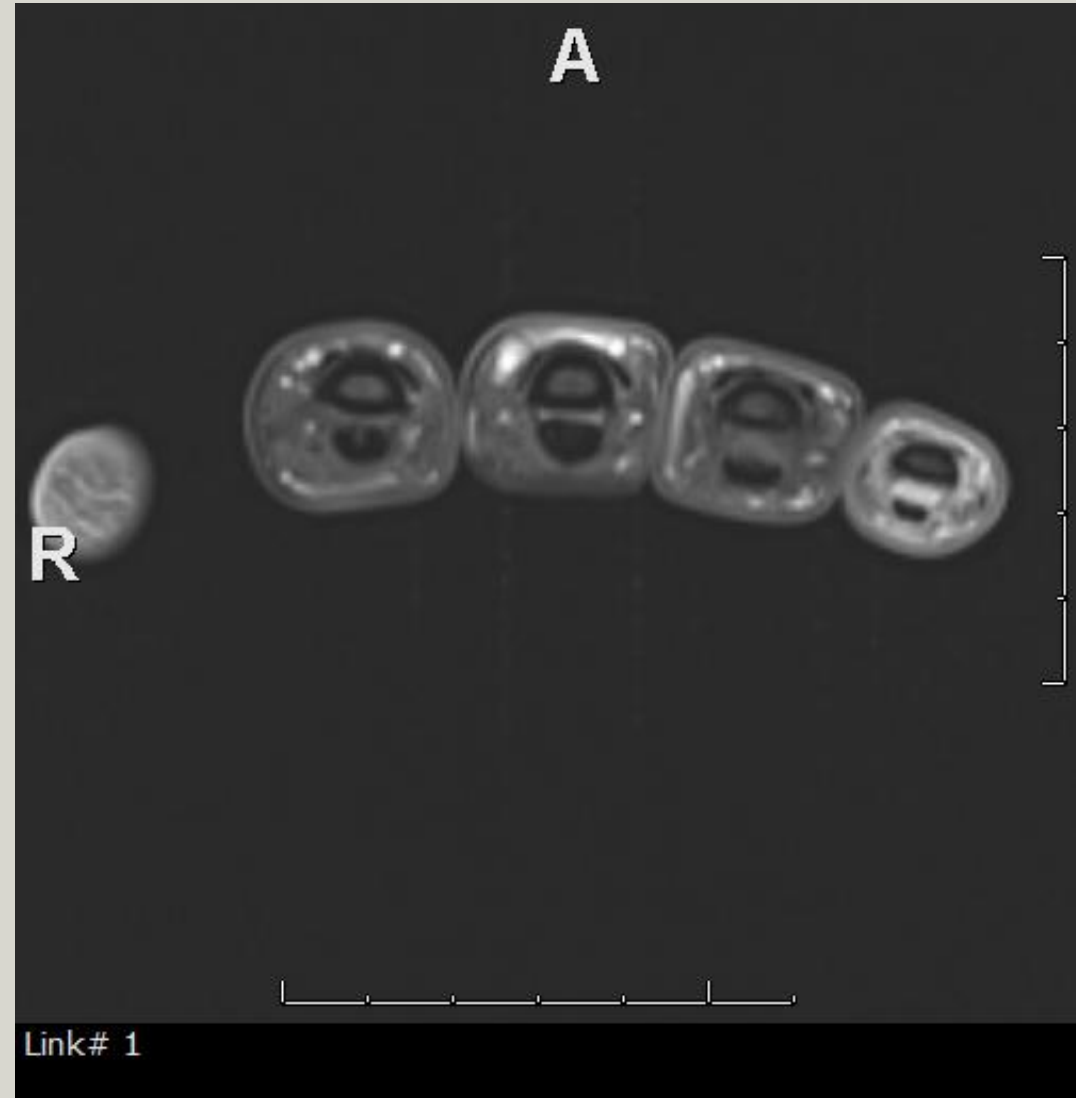
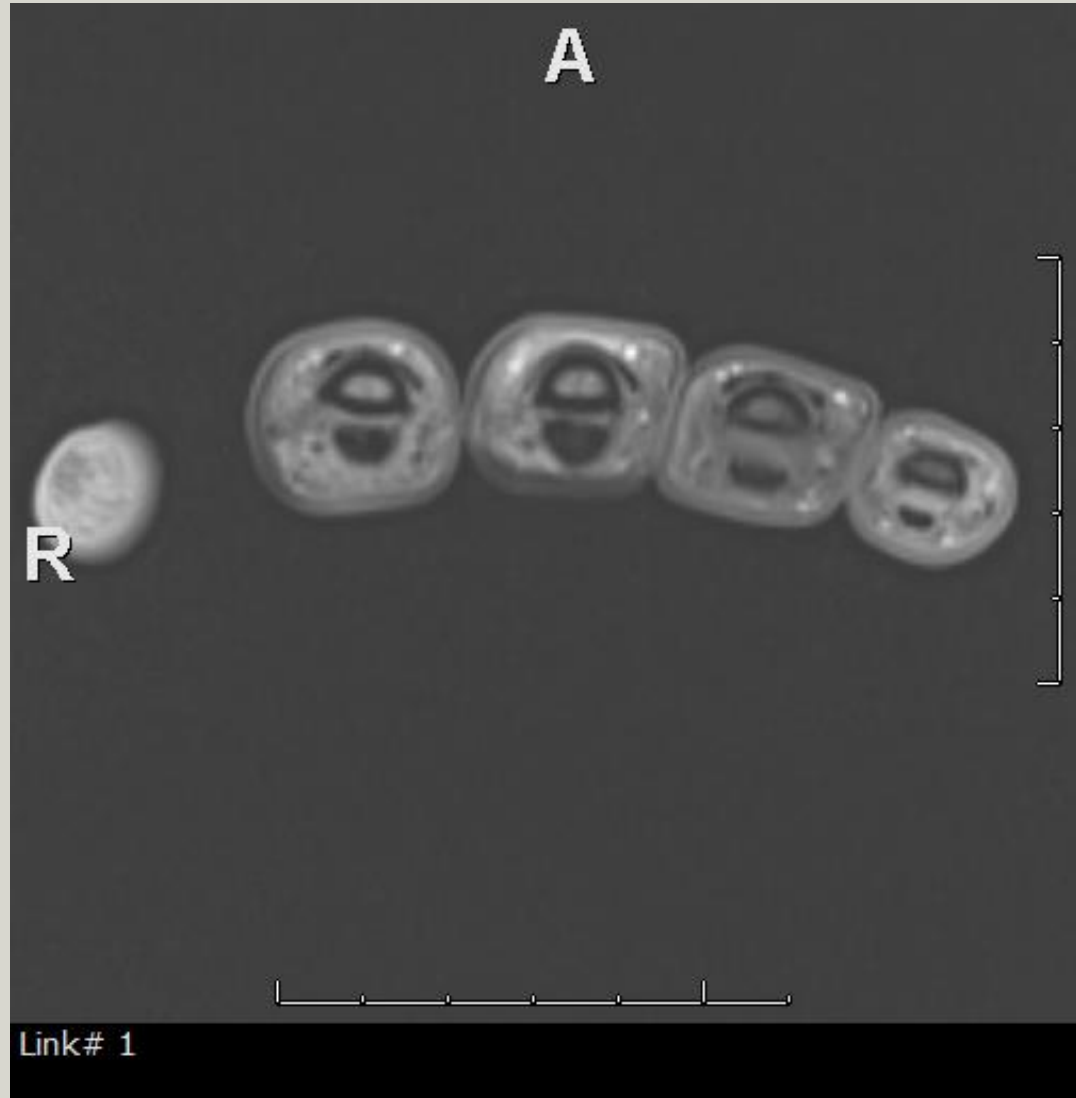

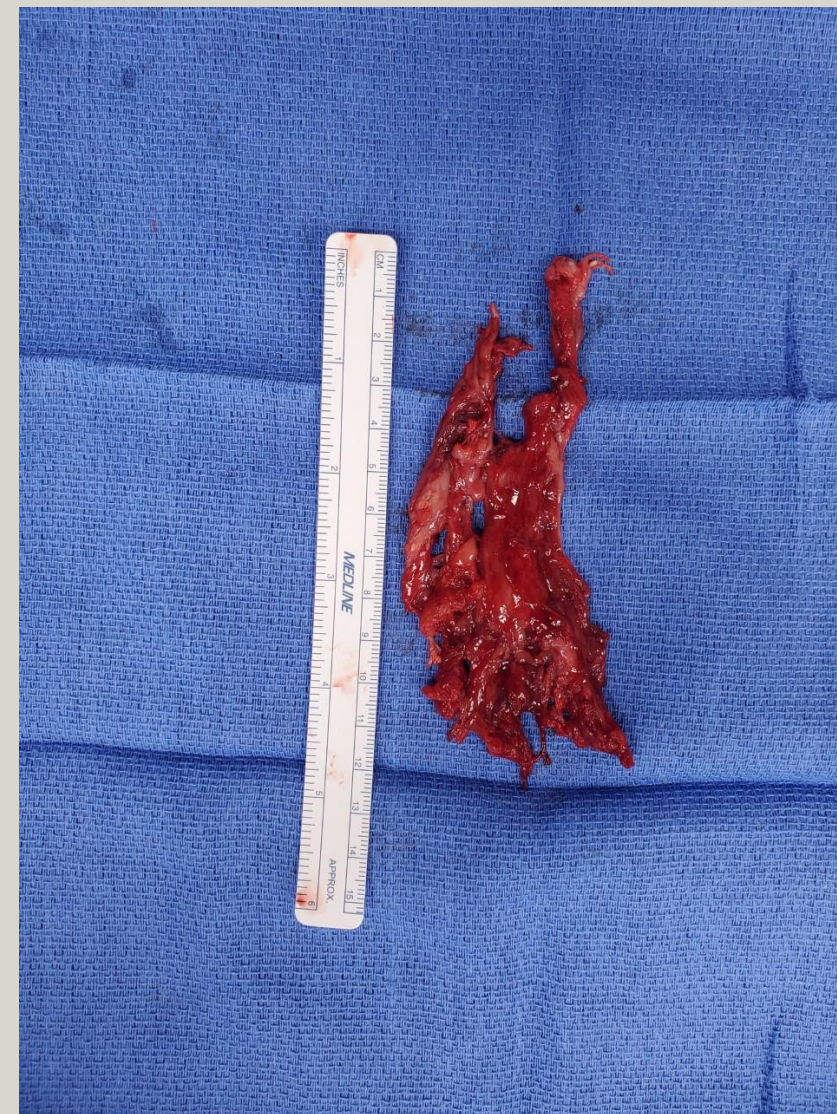
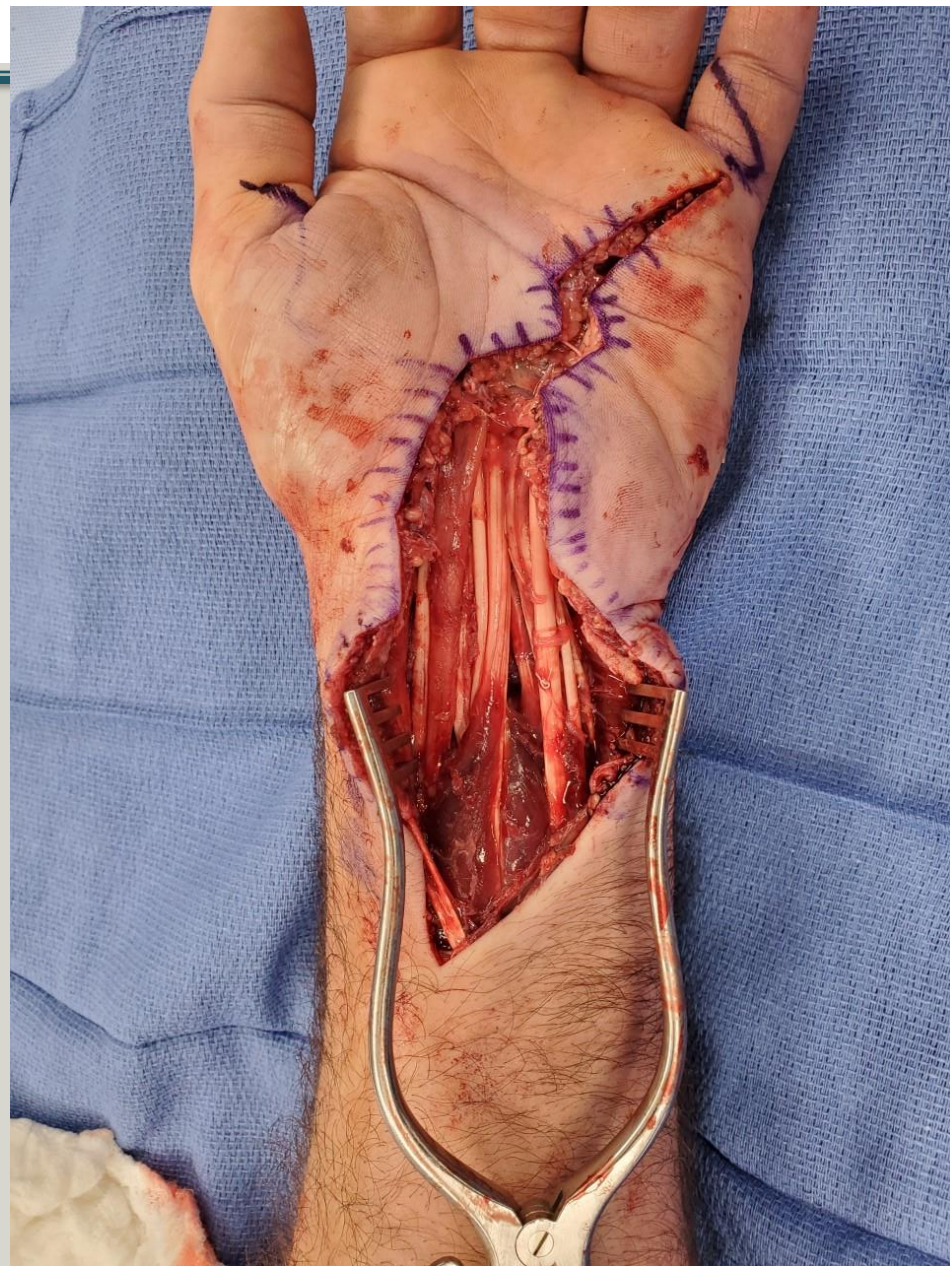

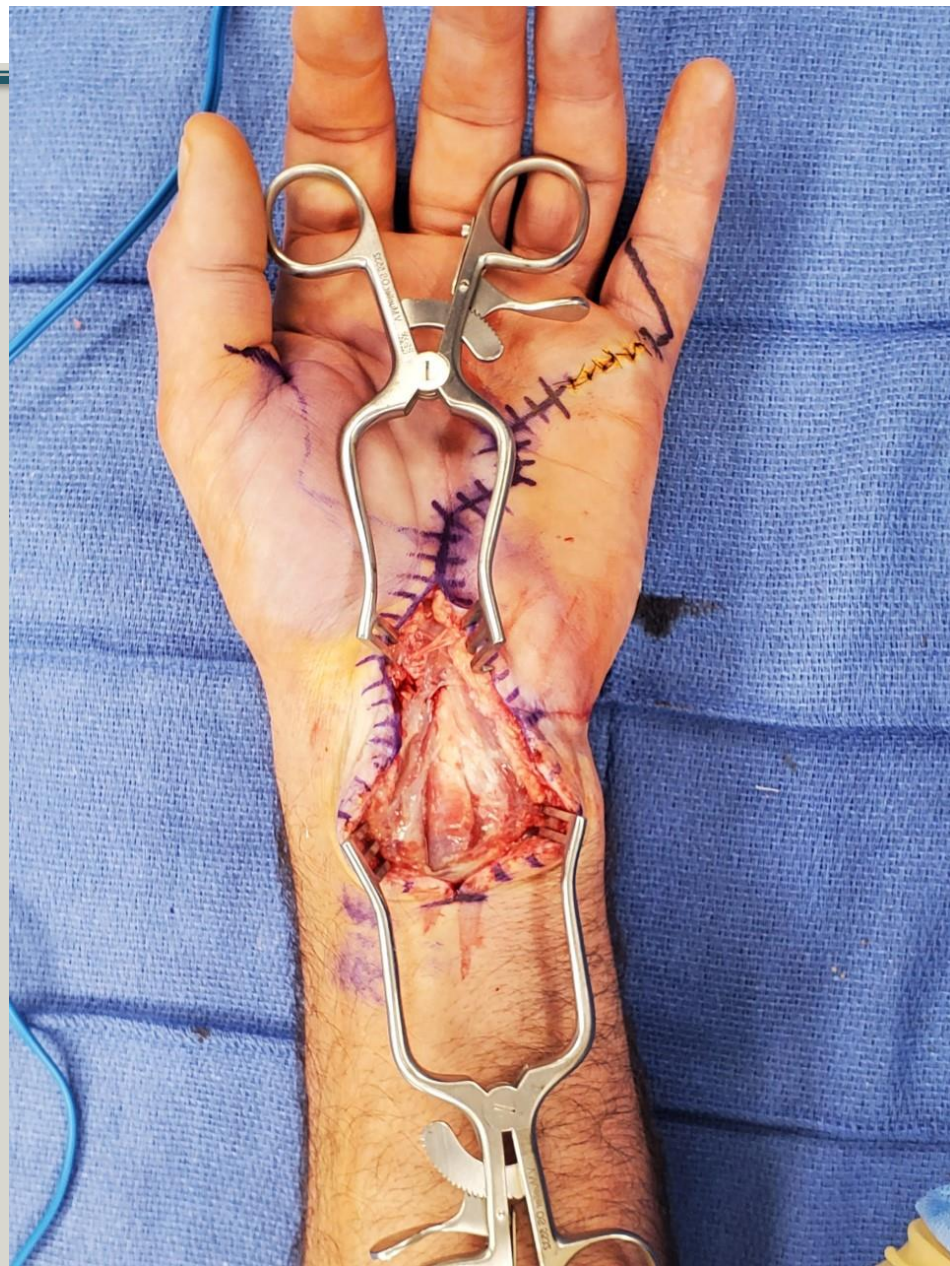












UT Southwestern
William P. Clements Jr.
University Hospital