

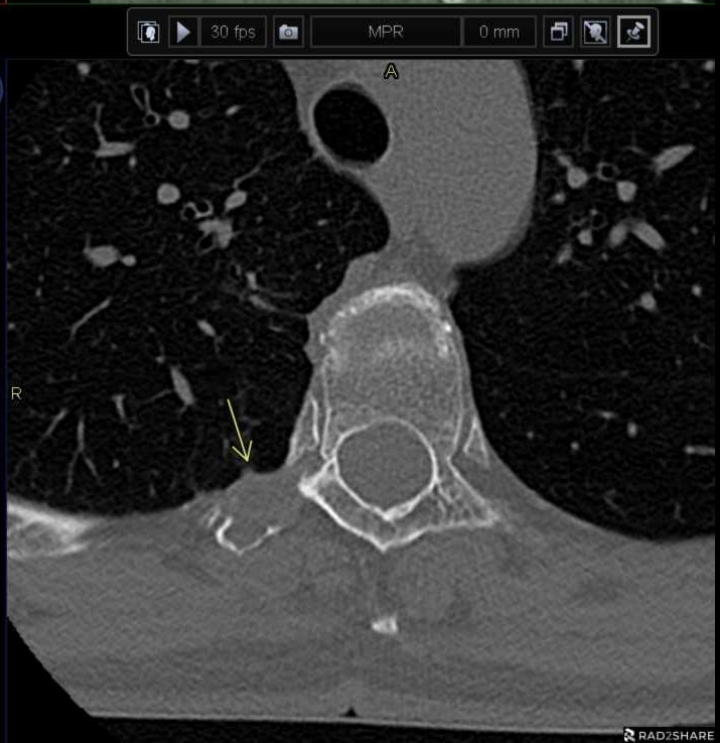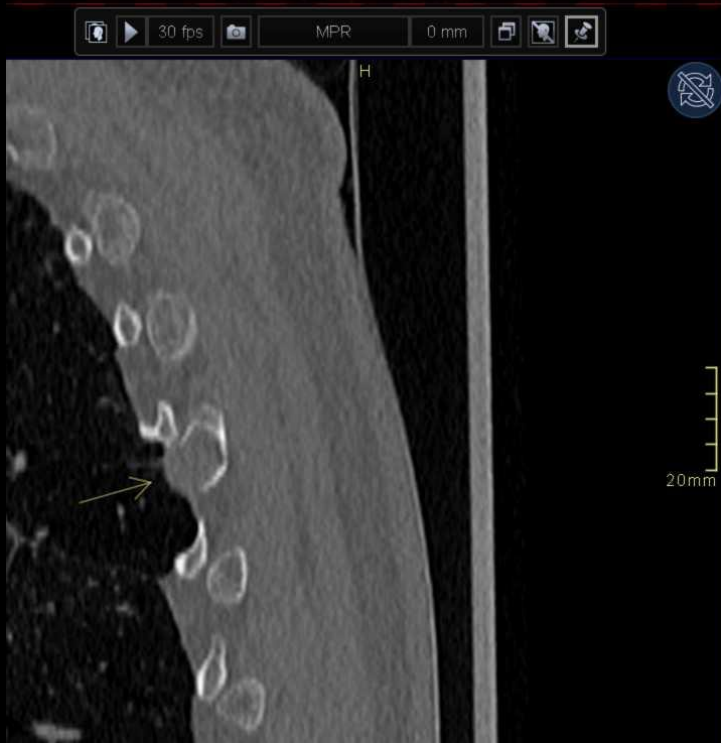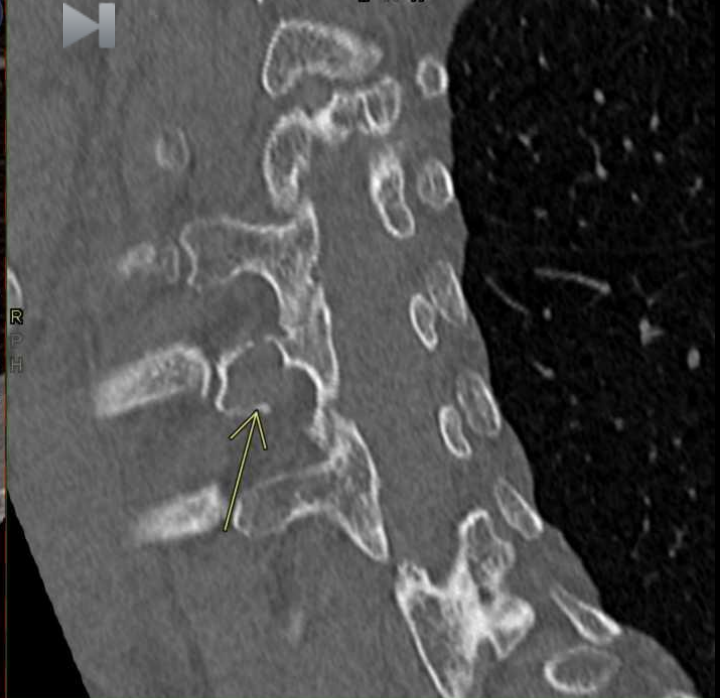
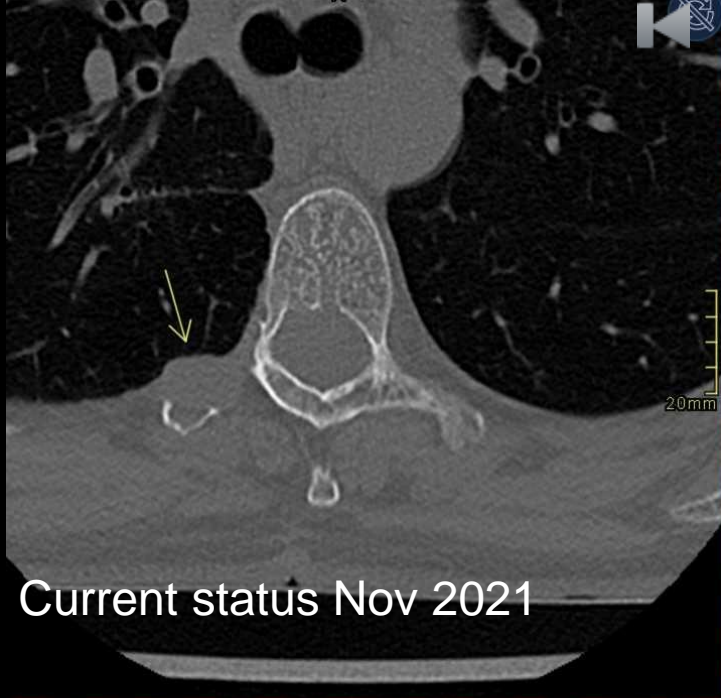58 yr lady with right sided neurofibroma
at T5 level

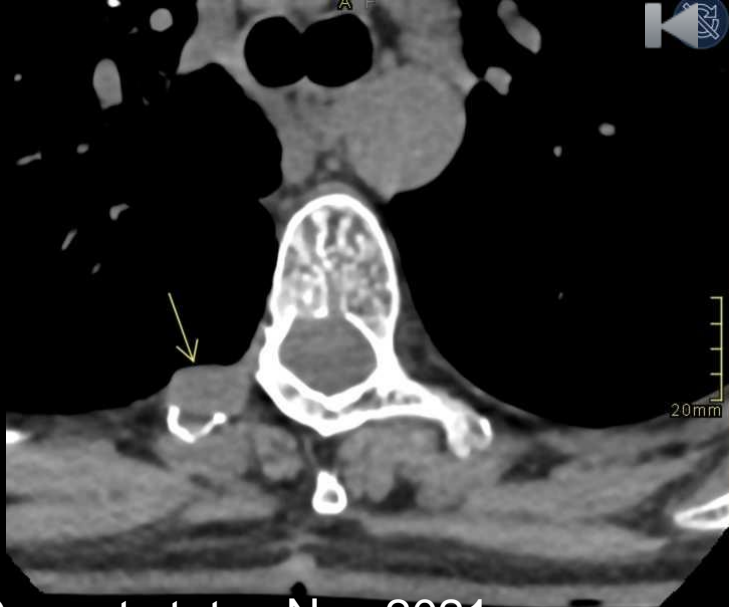Surgically excised December 2015

Small residual tumour in right T5 transverse process
that has doubled in size since previous scan
in March 2019 (2 years 8 months)

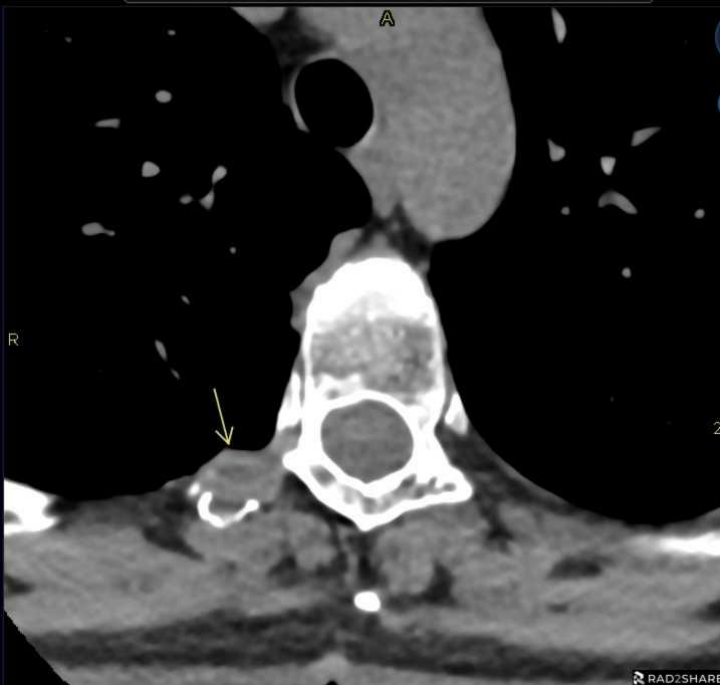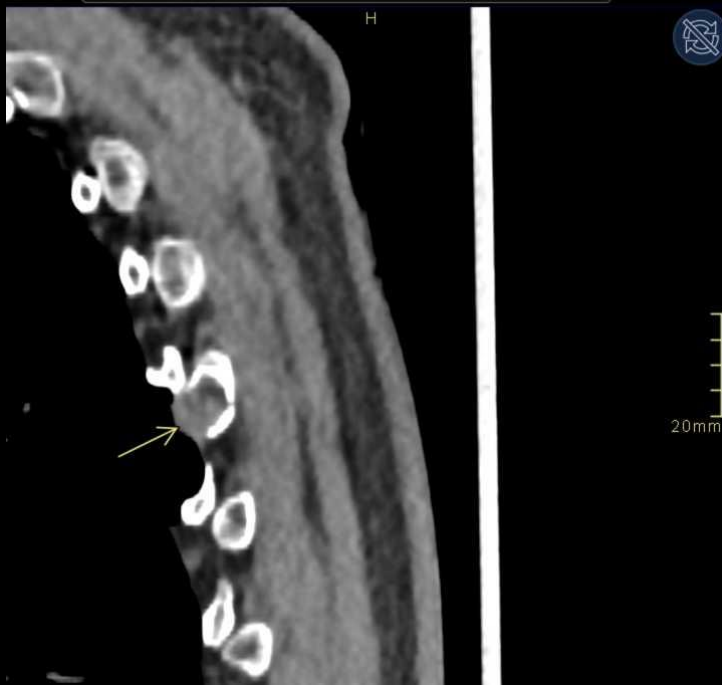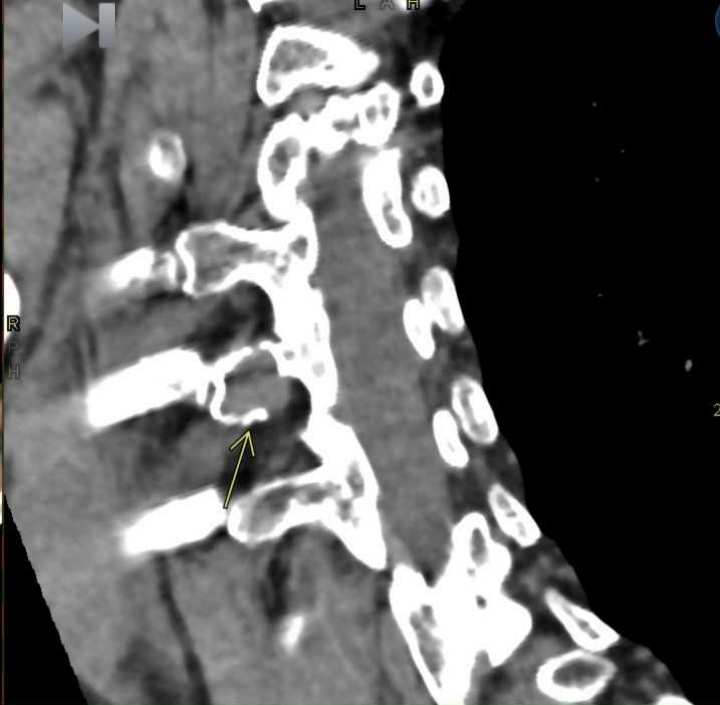
Any advice on local image guided ablation of the
residual tumour would be appreciated.

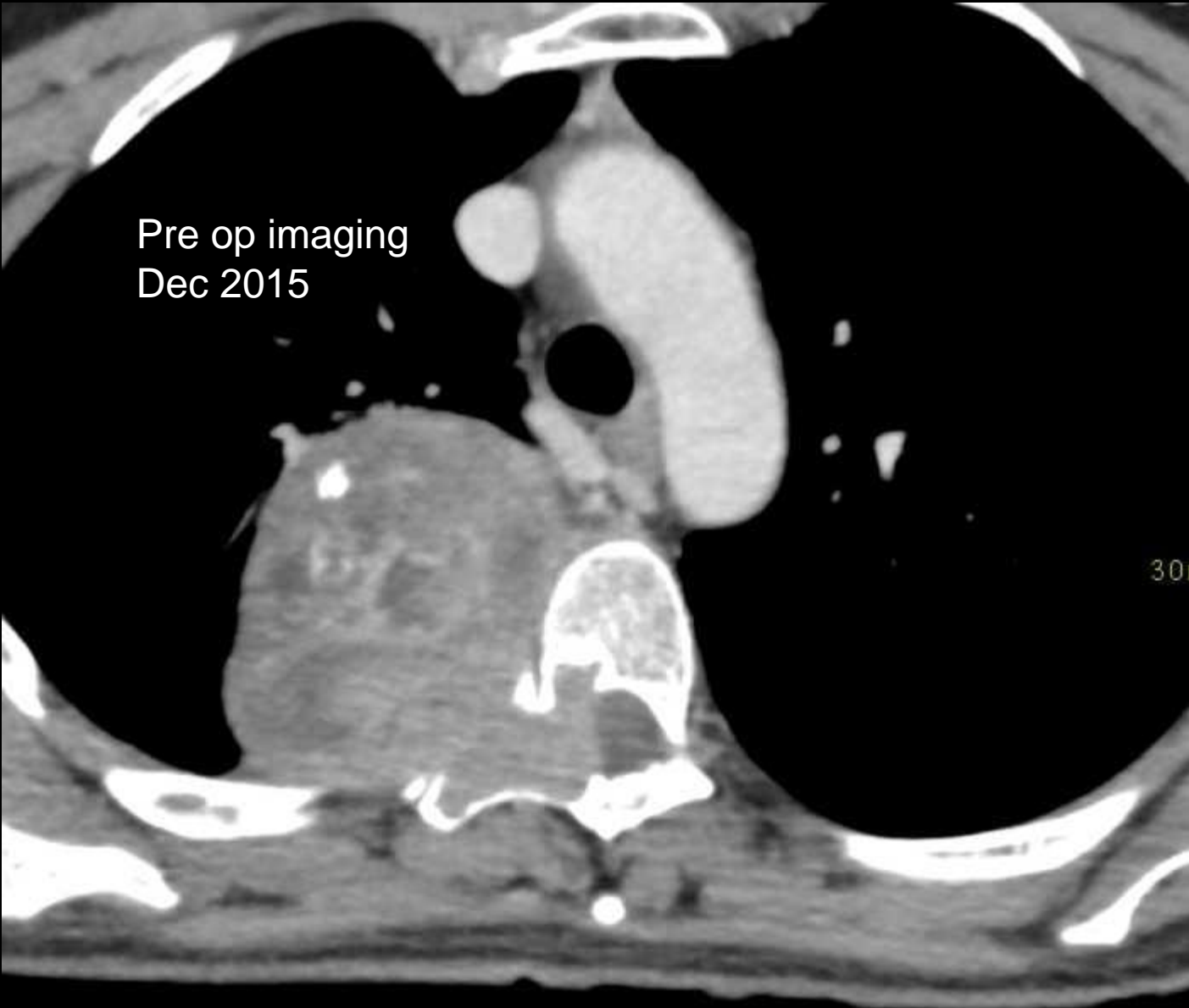

.





Current status Nov 2021





Pre op imaging
Dec 2015

301