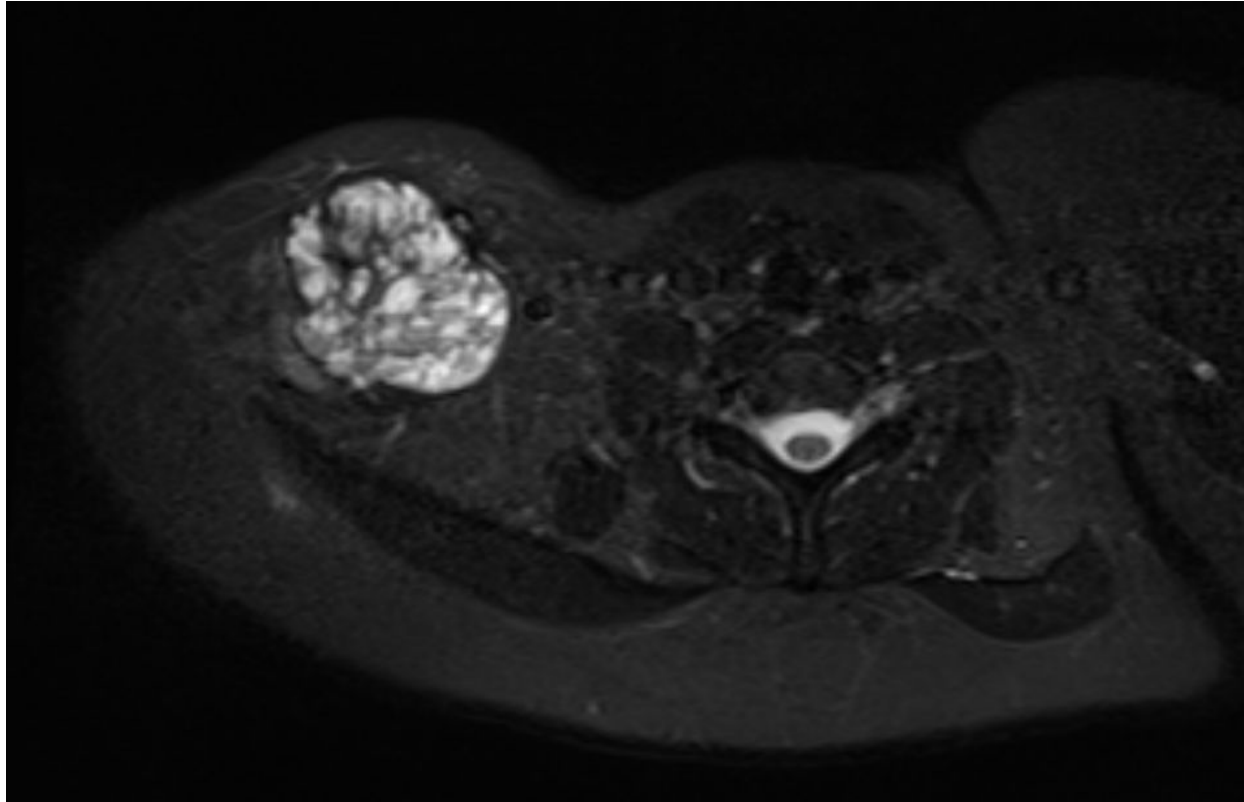
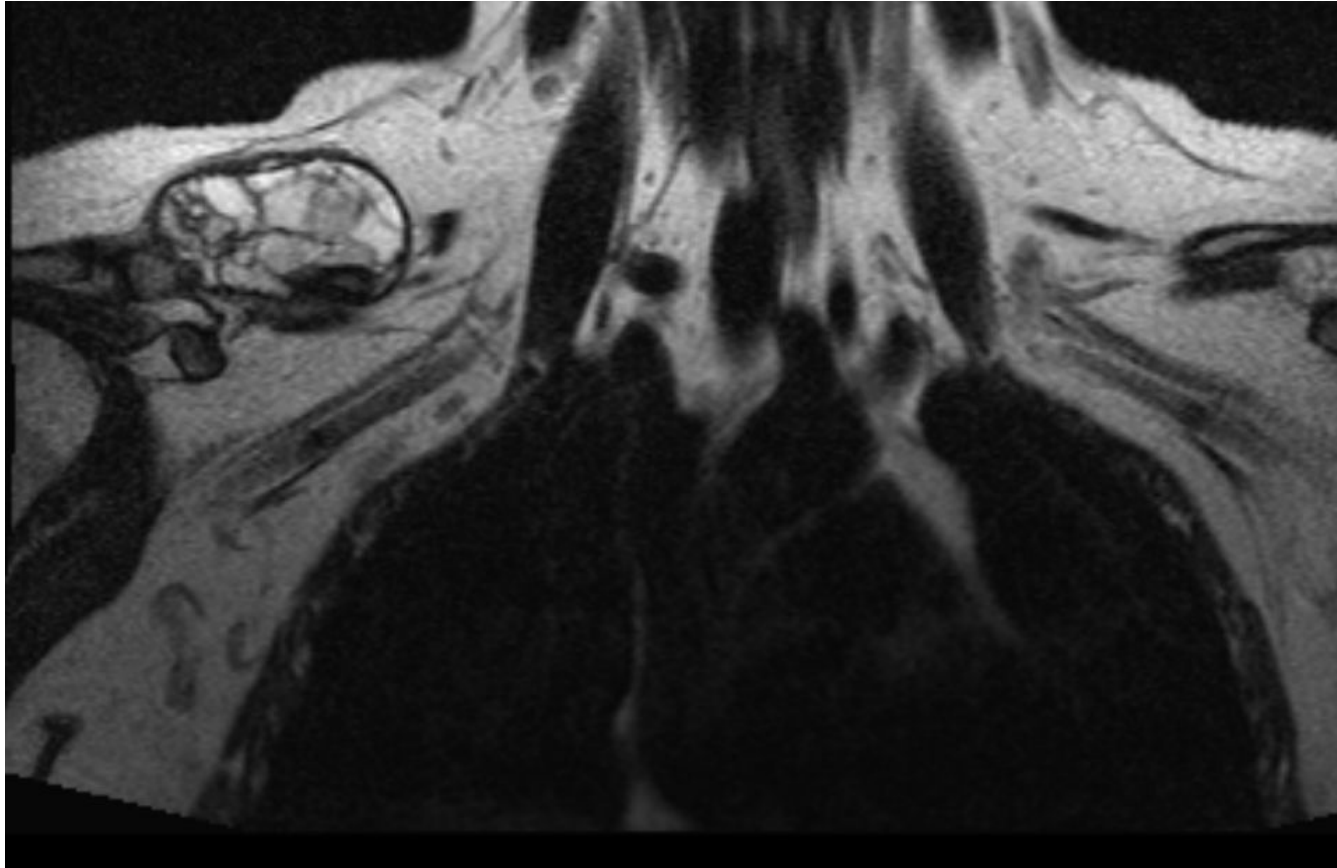


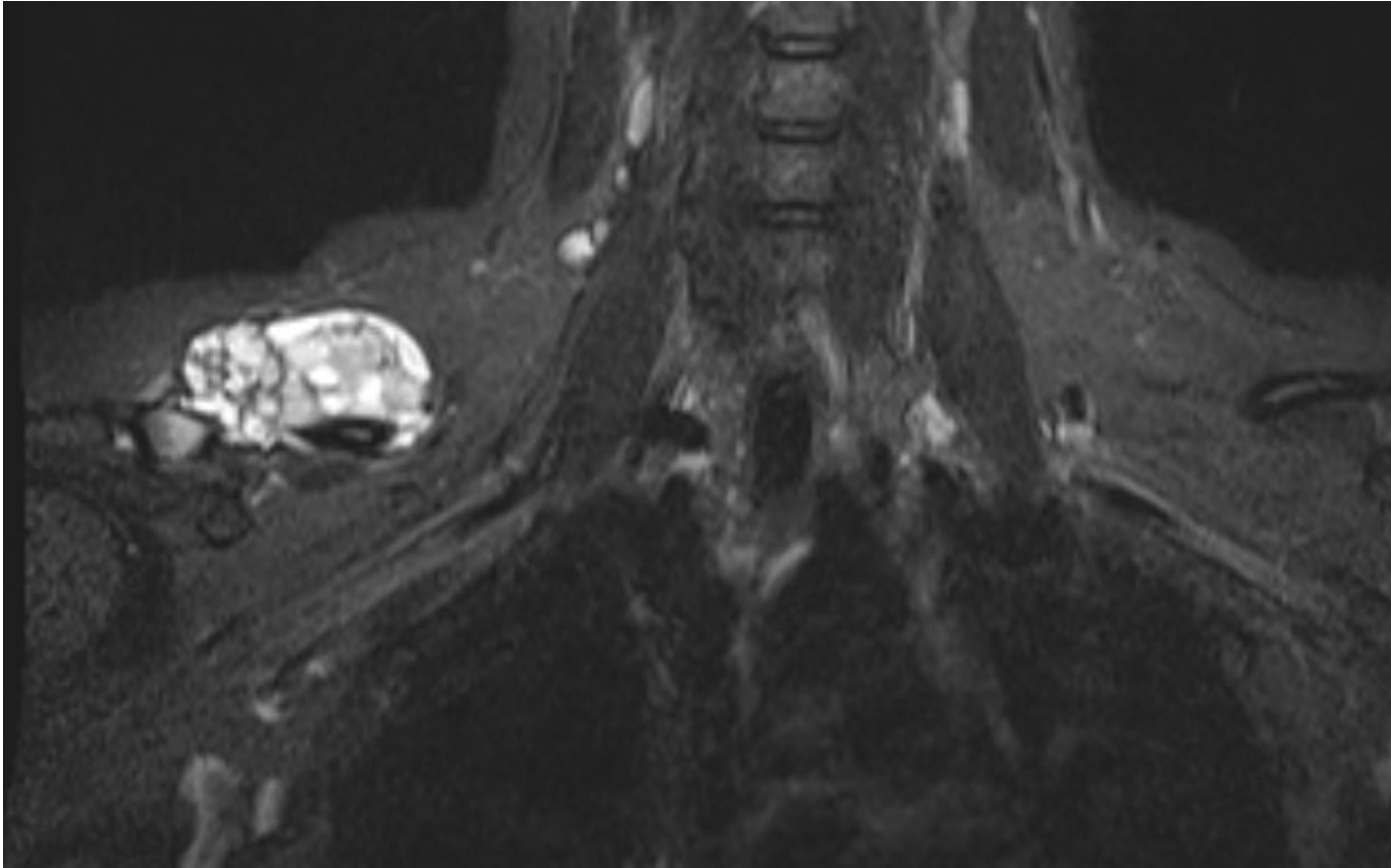
Axial STIR



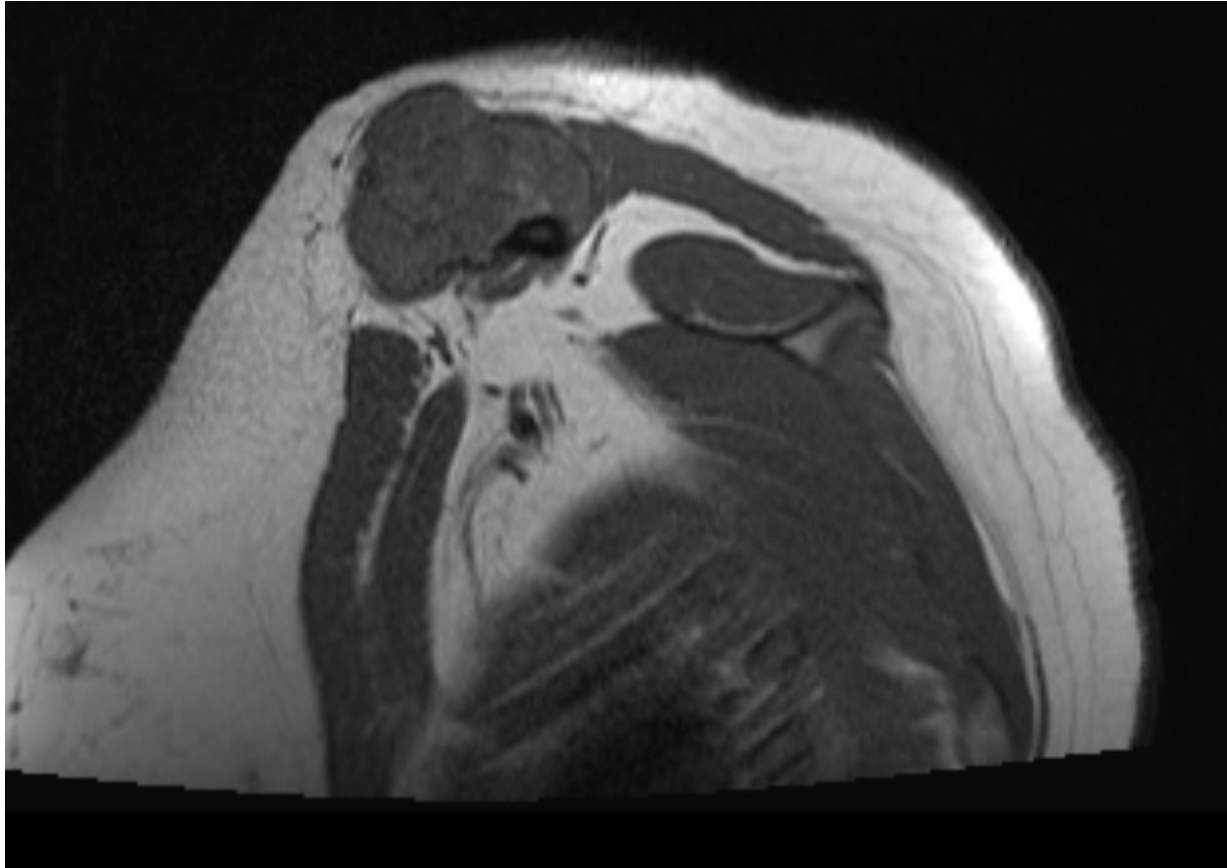
Coronal T2



Coronal T2 TIRM



Sagita T1



Post-contrast

