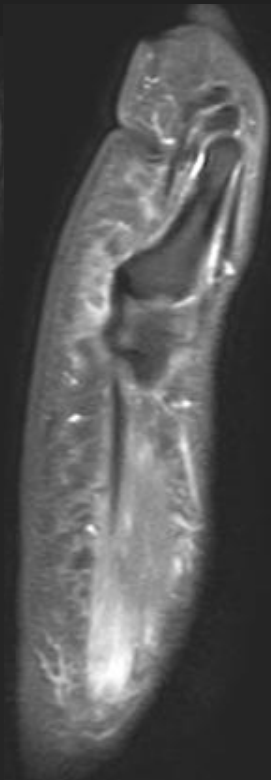
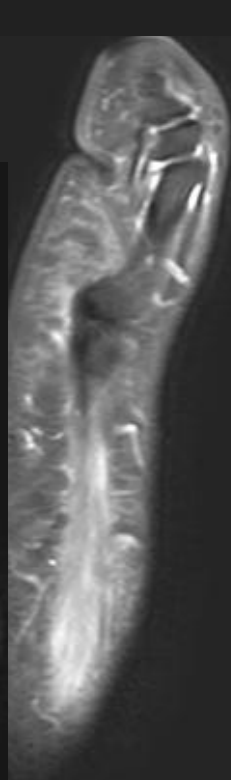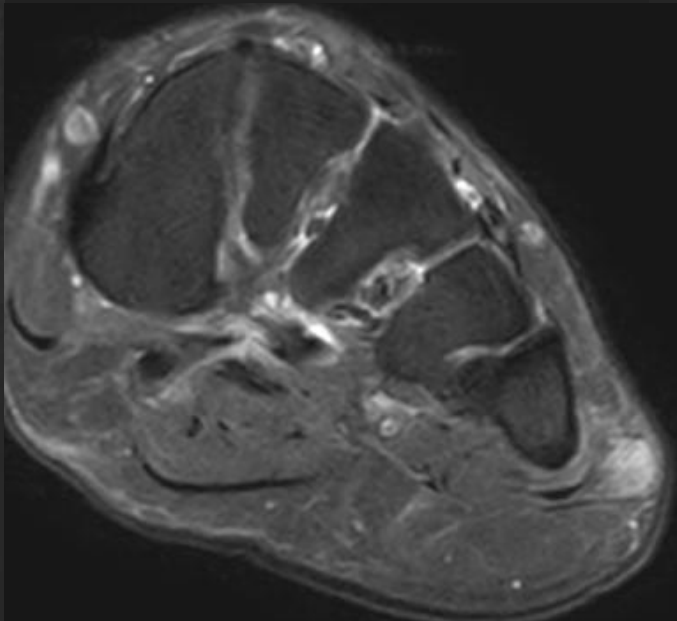
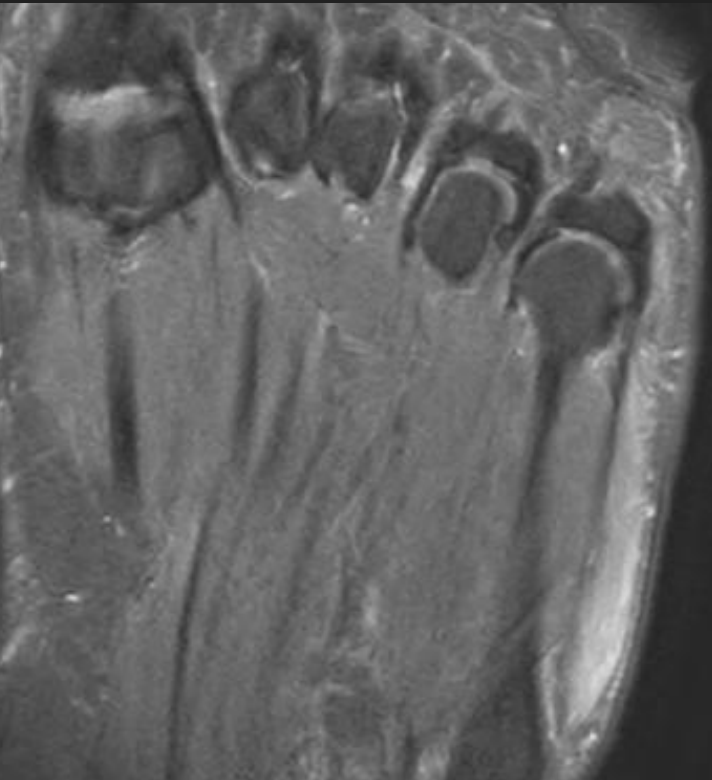
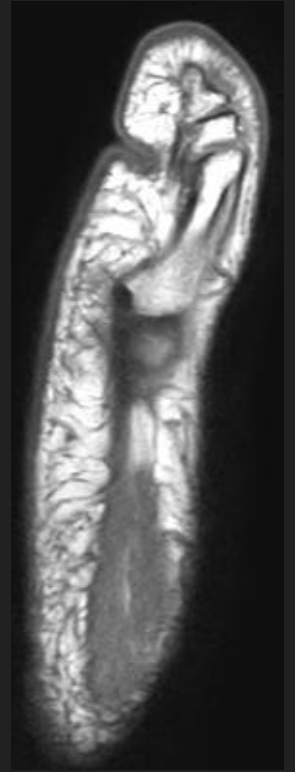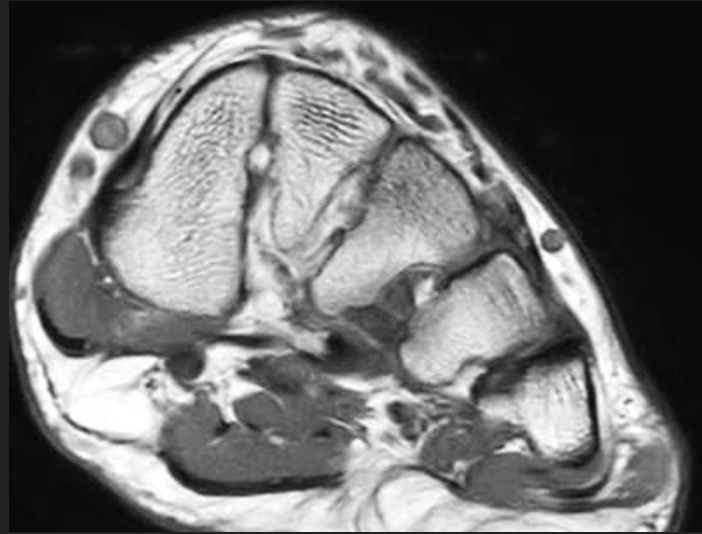


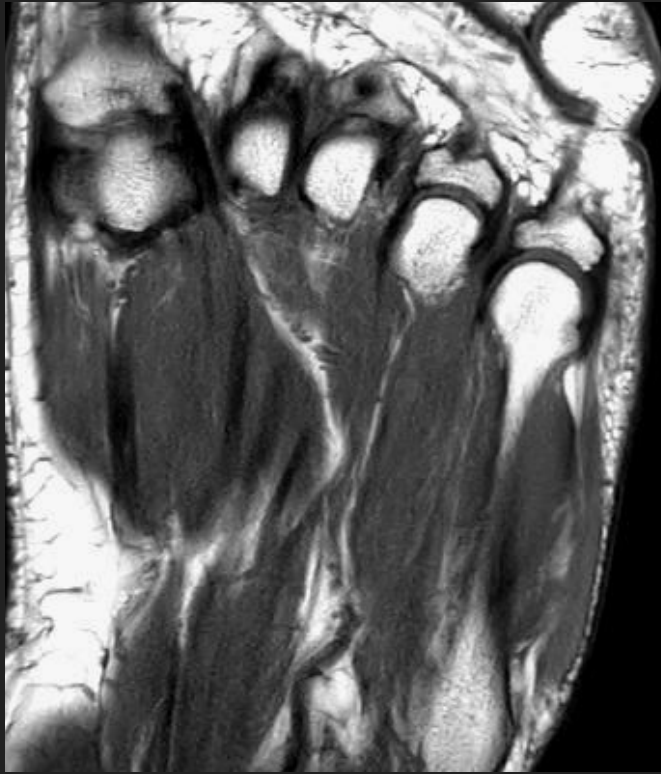Today 3 planes PDFS



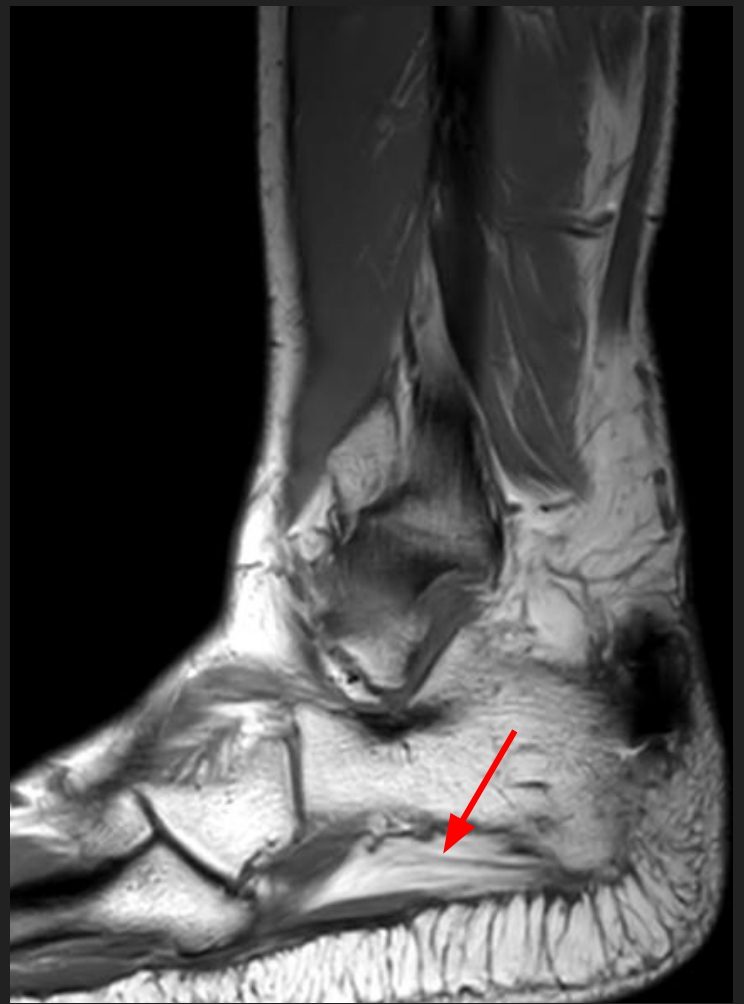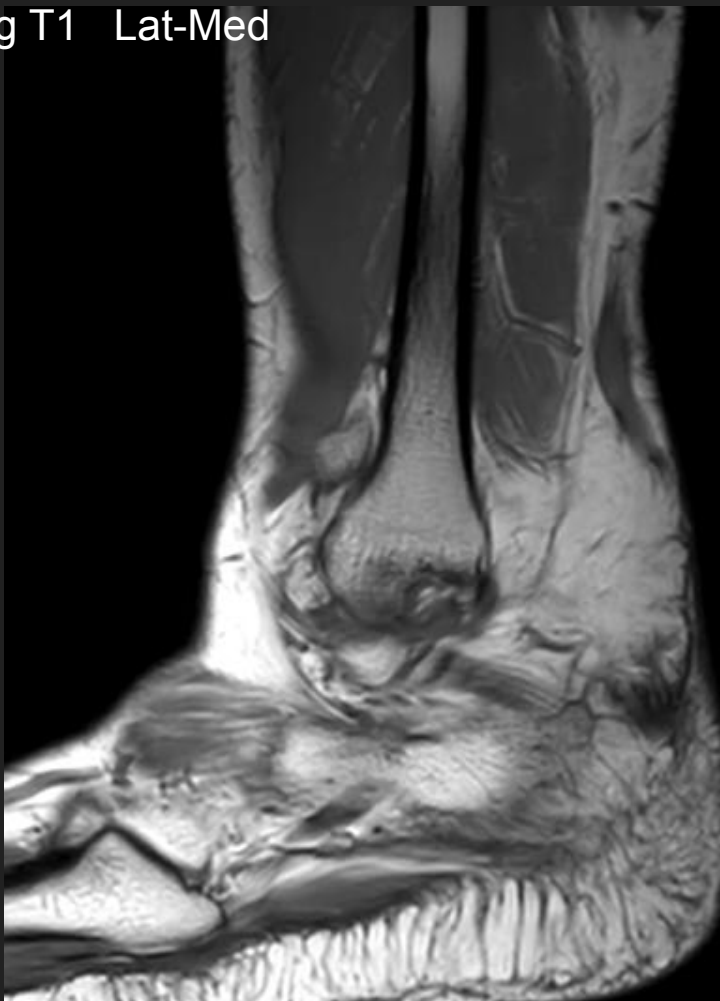ADM Edema

Today 3 planes T1

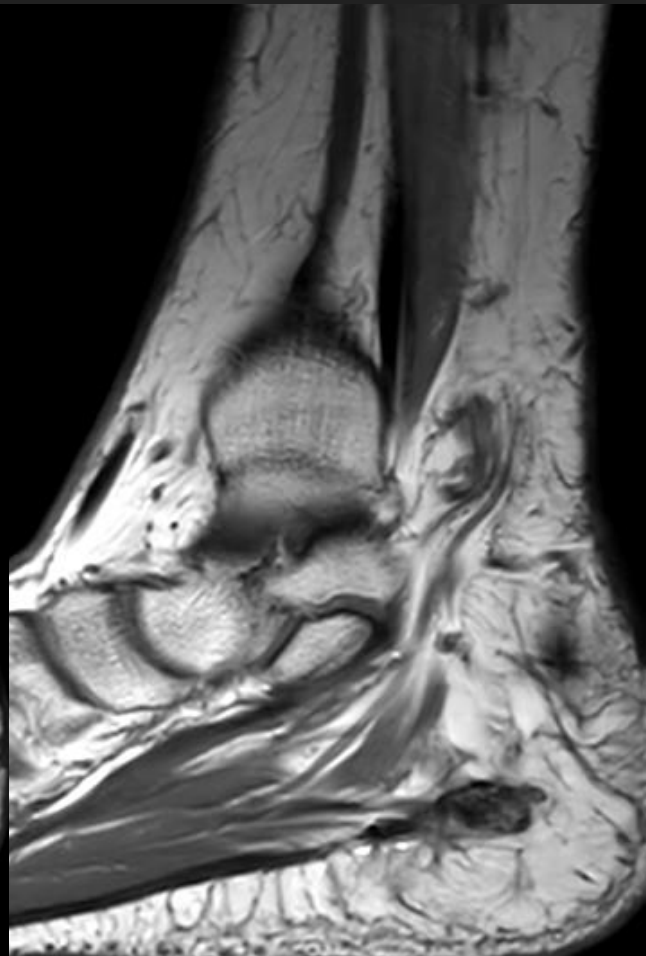
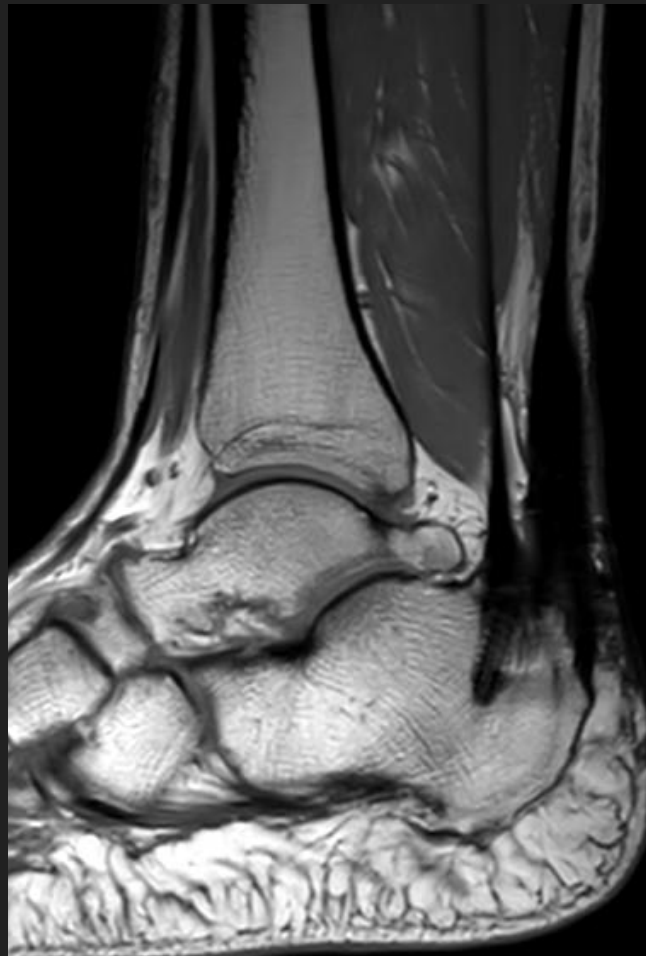
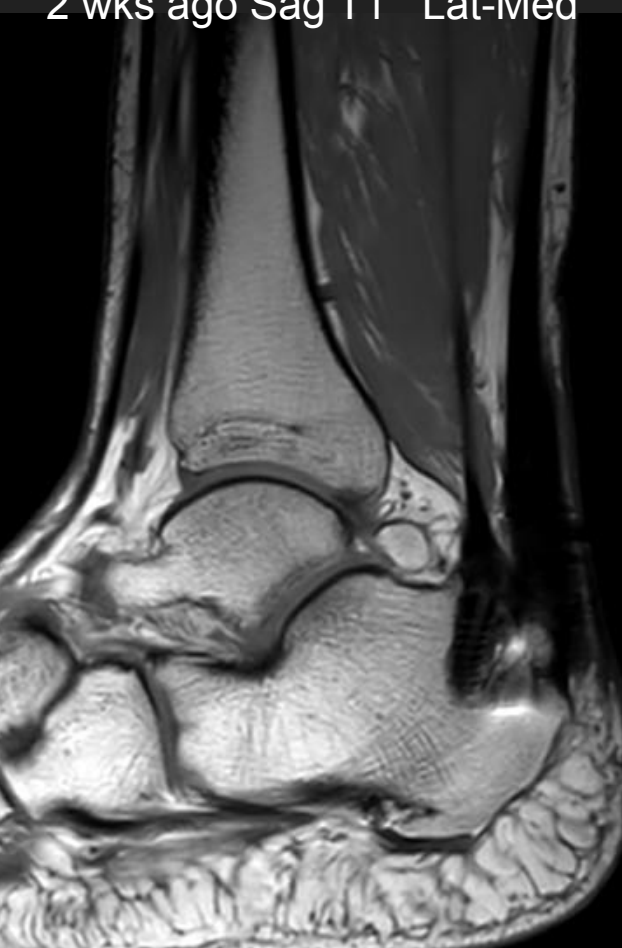No ADM atrophy

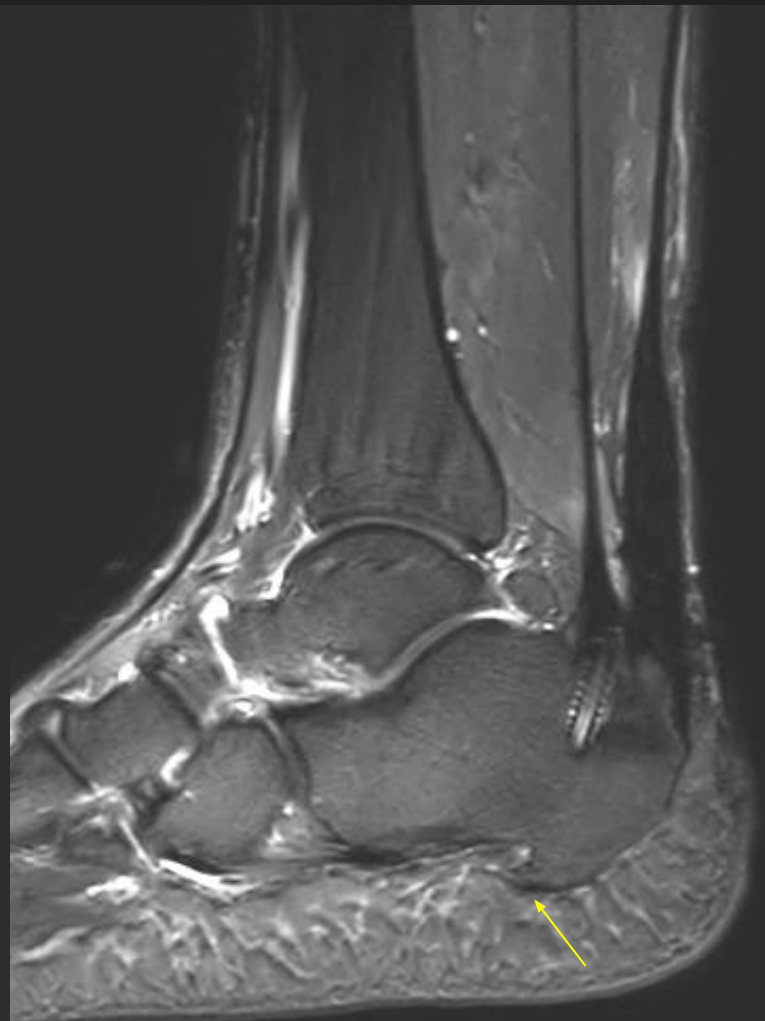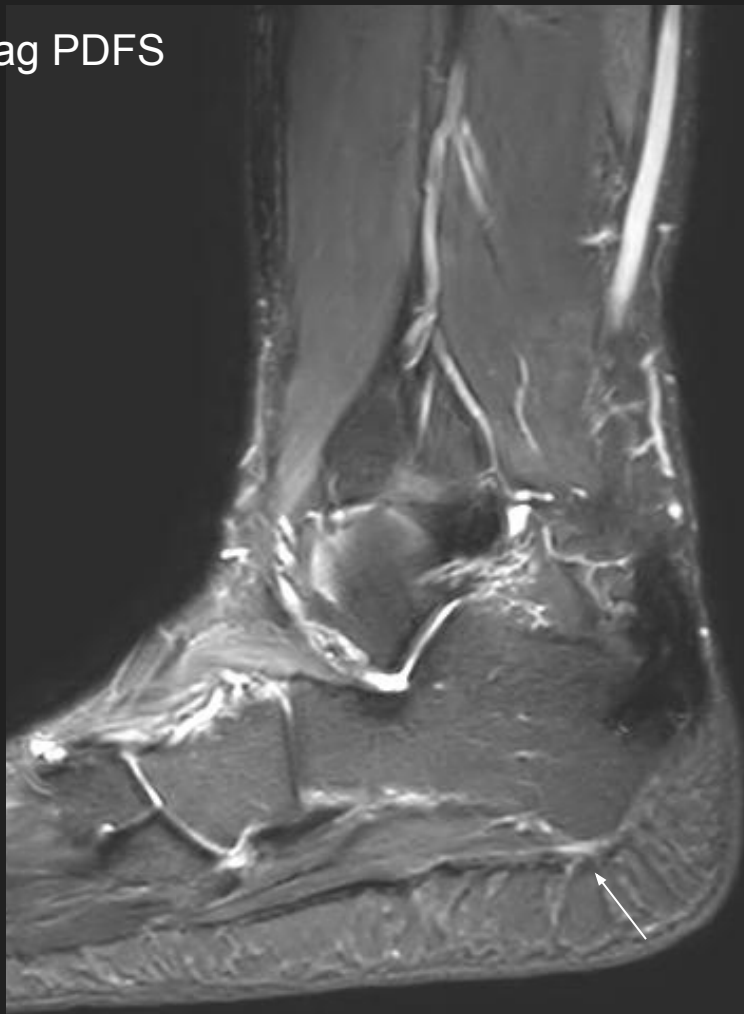2 wks ago Sag T1 Lat-Med

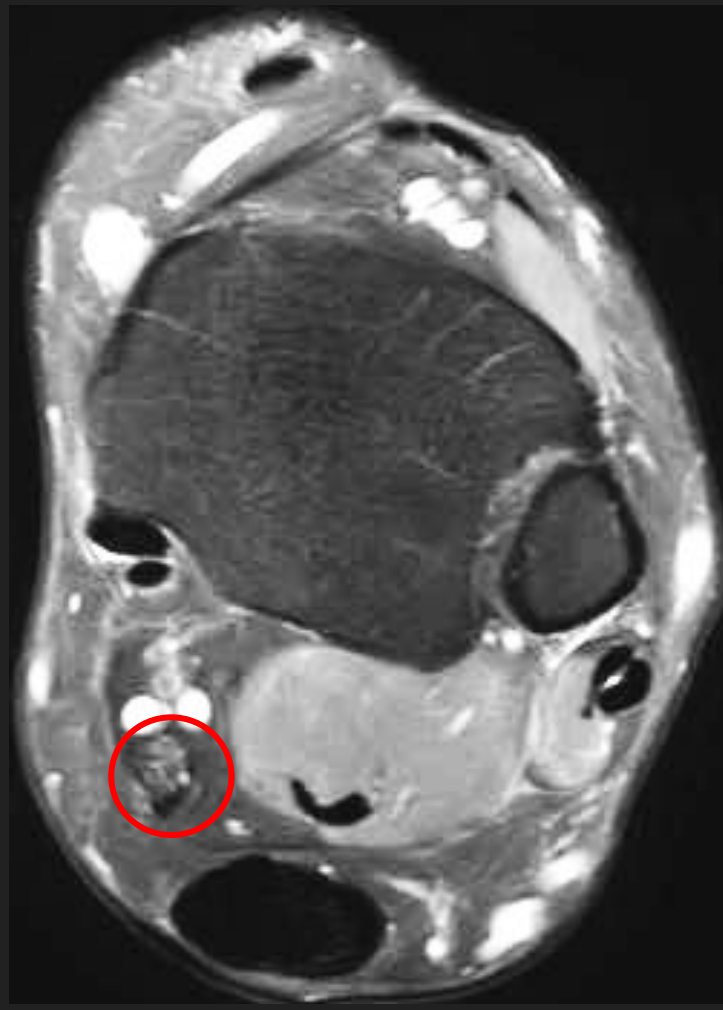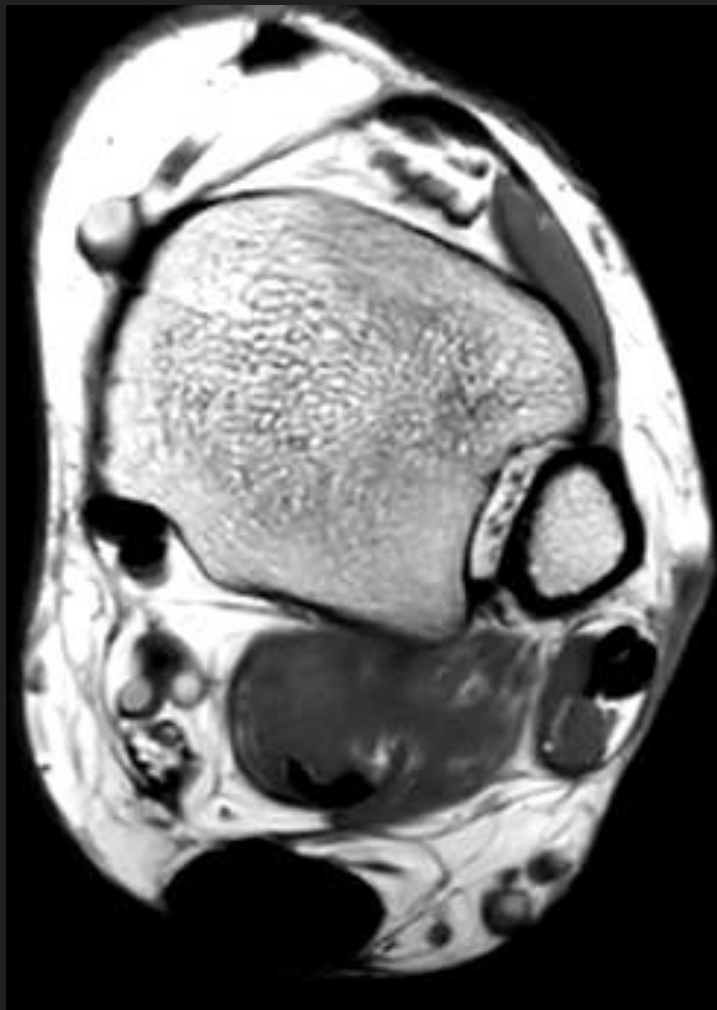


2 wks ago Sag T1 Lat-Med

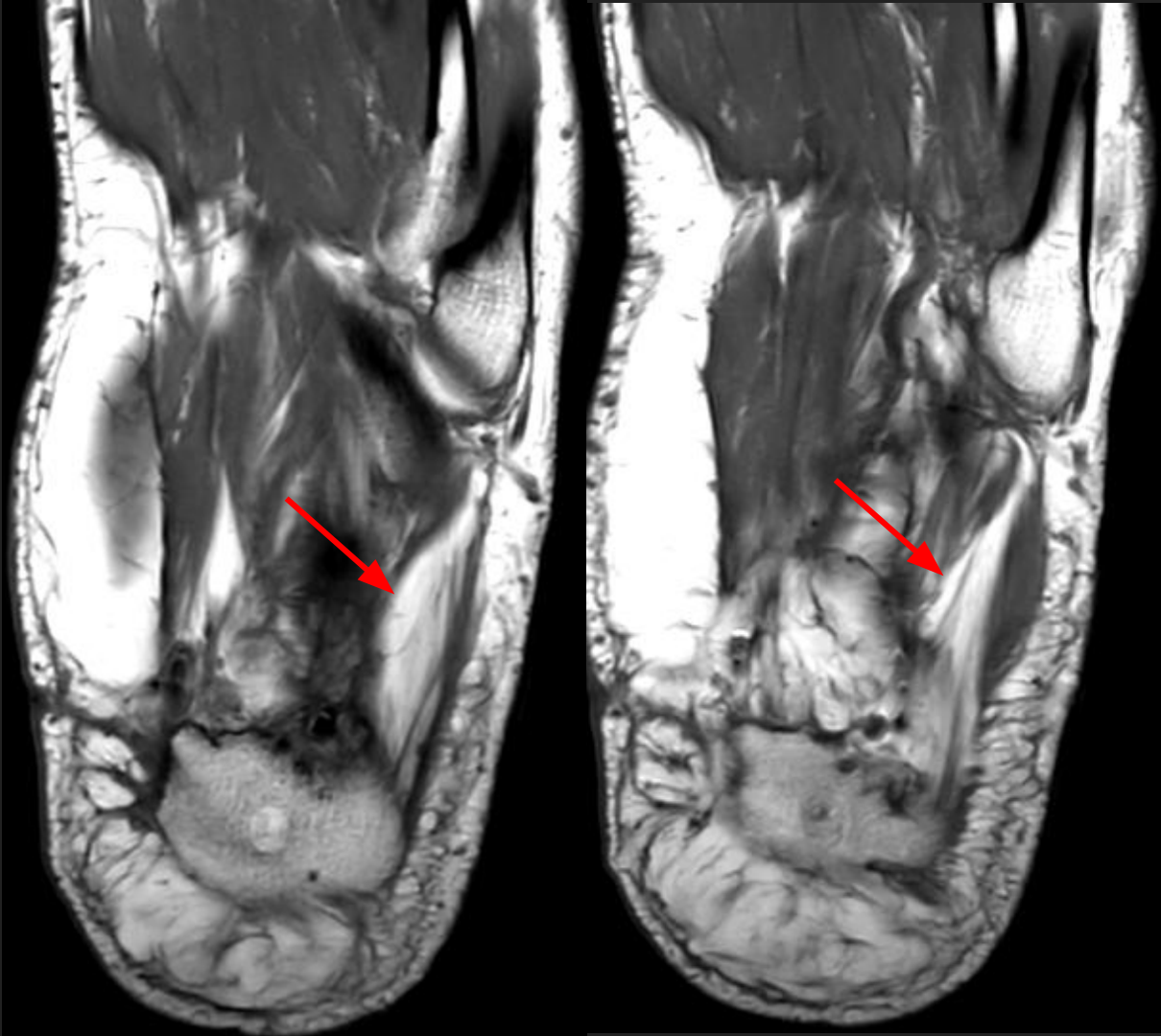


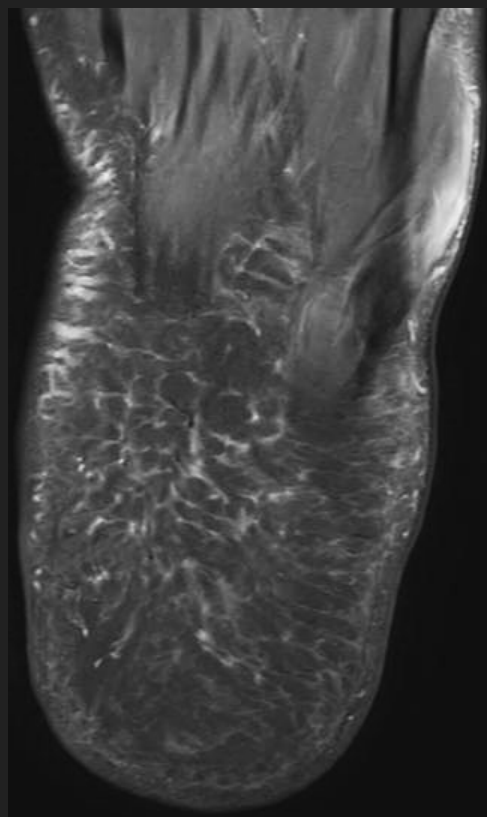
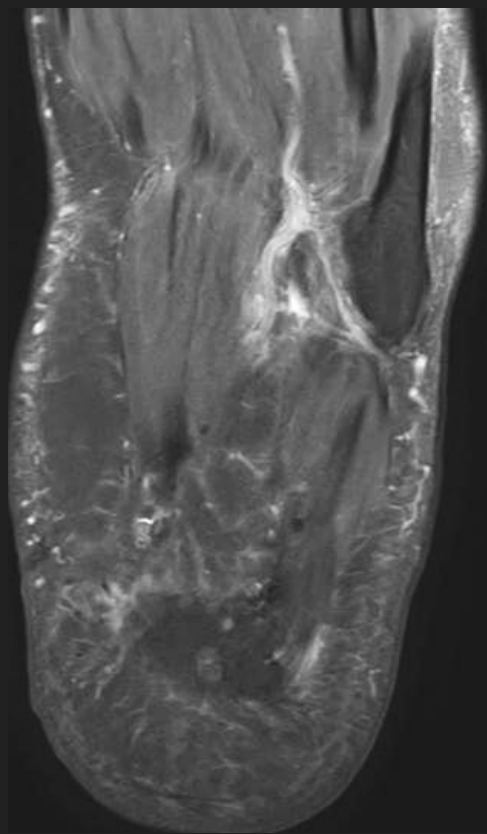
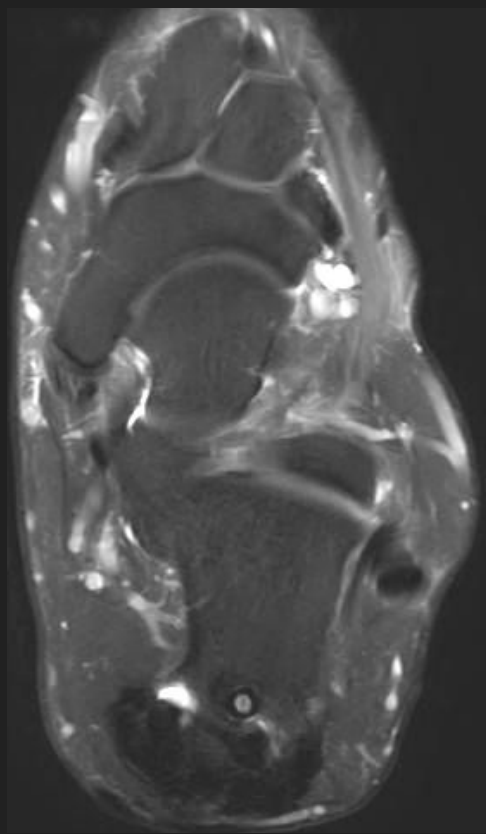
2 wks ago Sag PDFS





2 wks ago Ax T1







2 wks ago Cor PDFS

