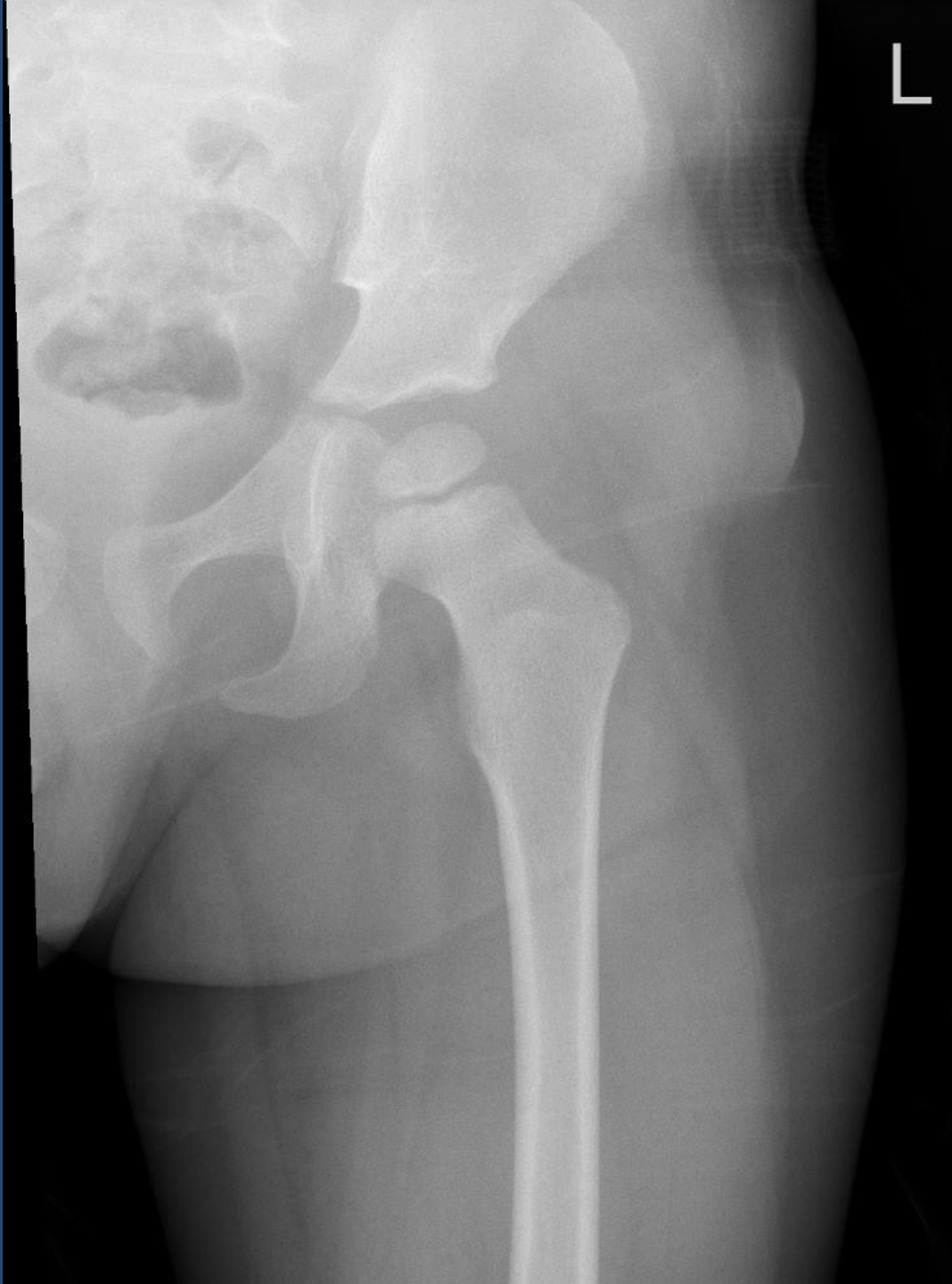
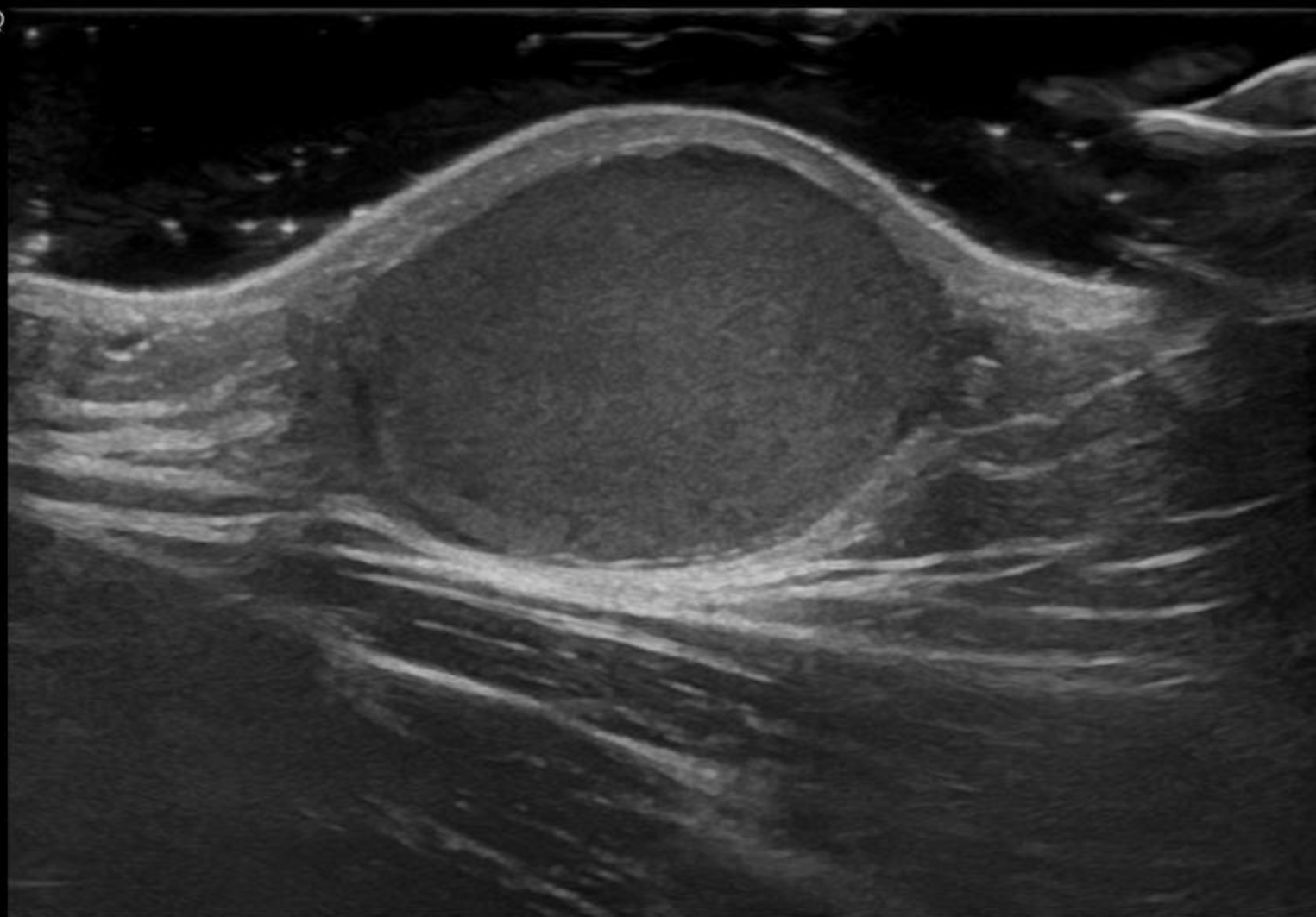


3 yo male, no known PMH, painless slightly bluish  
mass anterior left thigh x 1 month, no known  
trauma

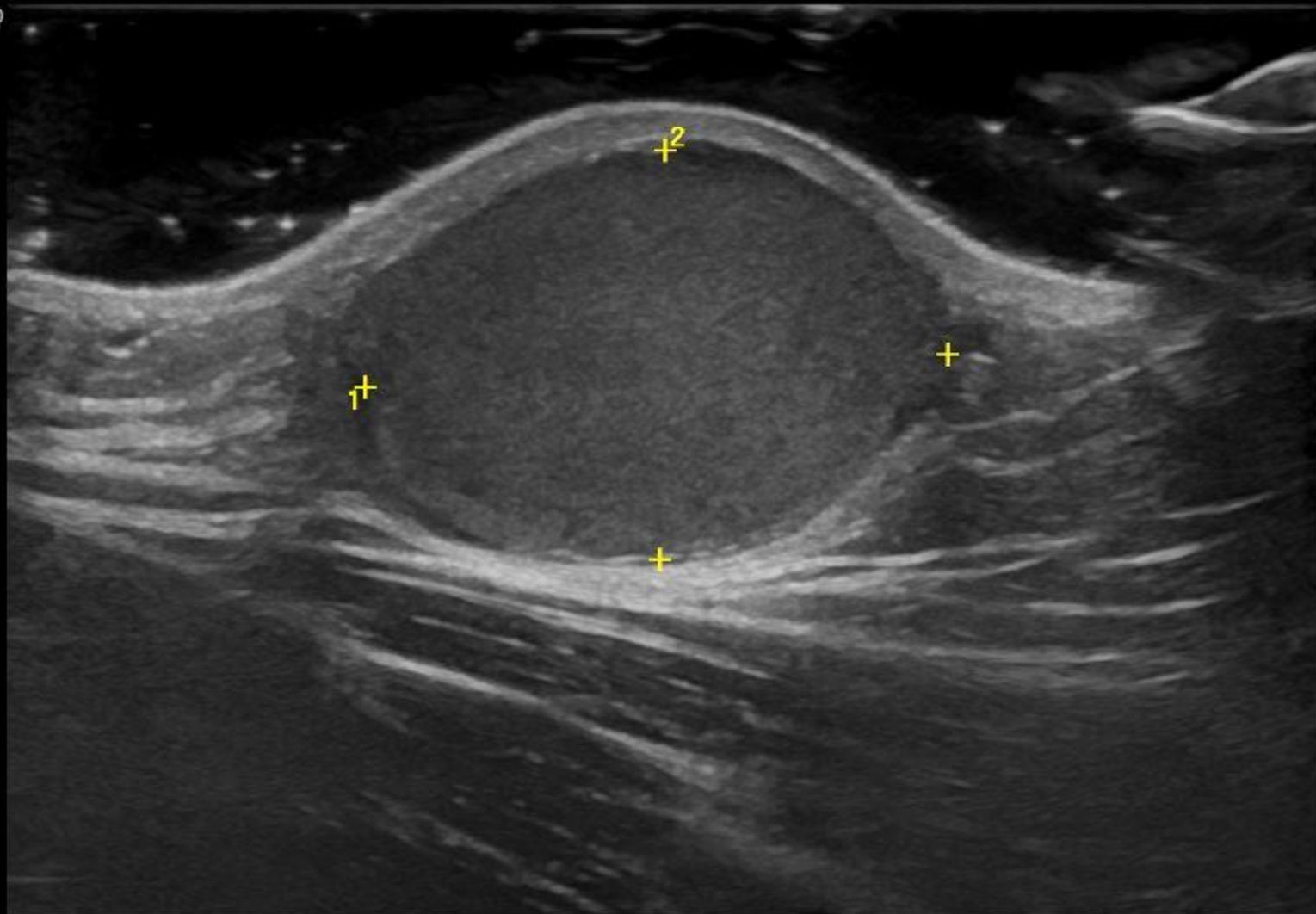


LOGIQ  
E10



LEFT ANTEROLATERAL HIP LONG

LOGIQ  
E10



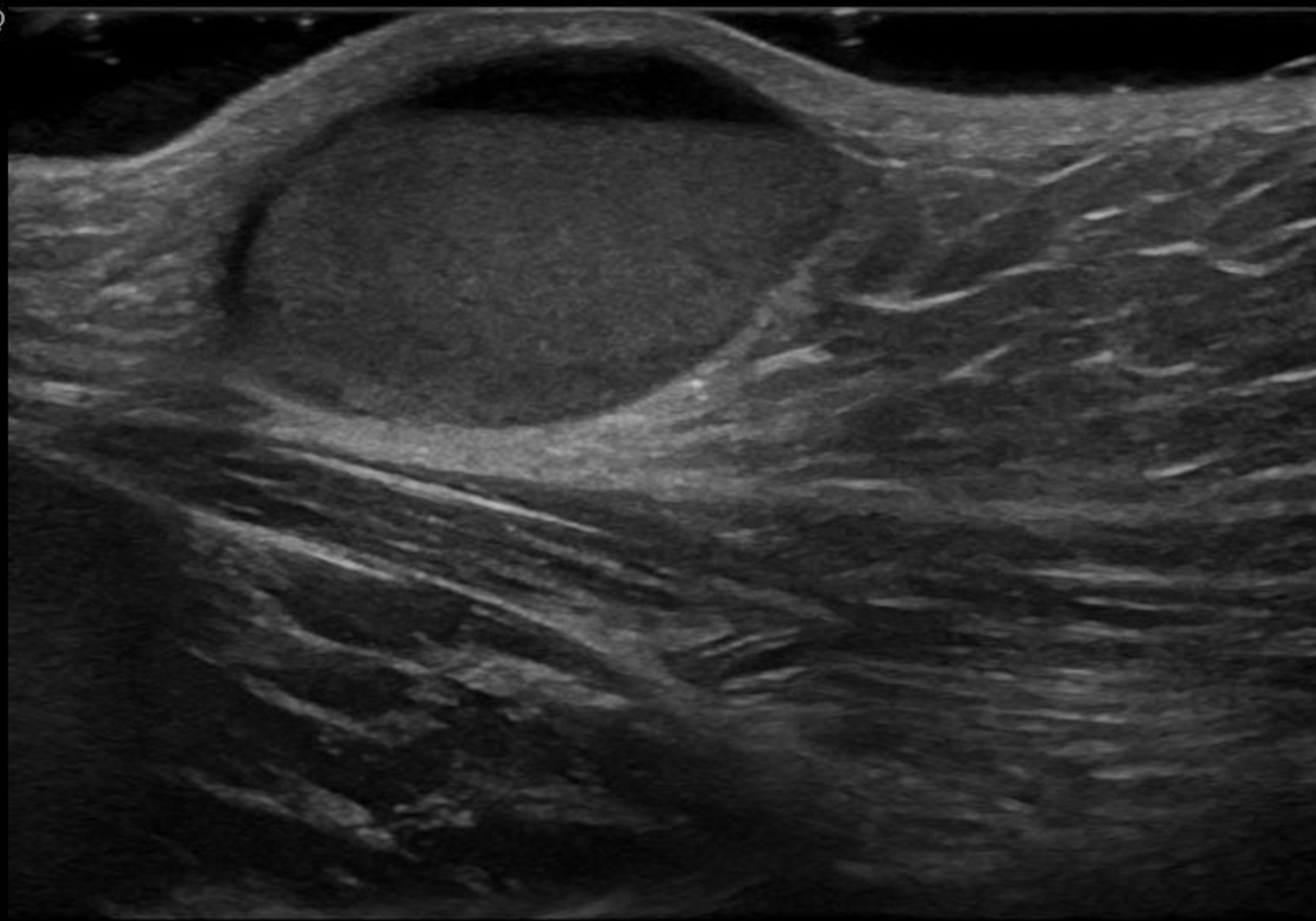
07 CH  
Fr  
- Gr  
S//  
- Ma  
D  
- DF  
AC

1  
-  
-  
-  
2  
-  
-  
-  
3  
-  
L J

●	100°
1	L 2.24 cm
2	L 1.57 cm

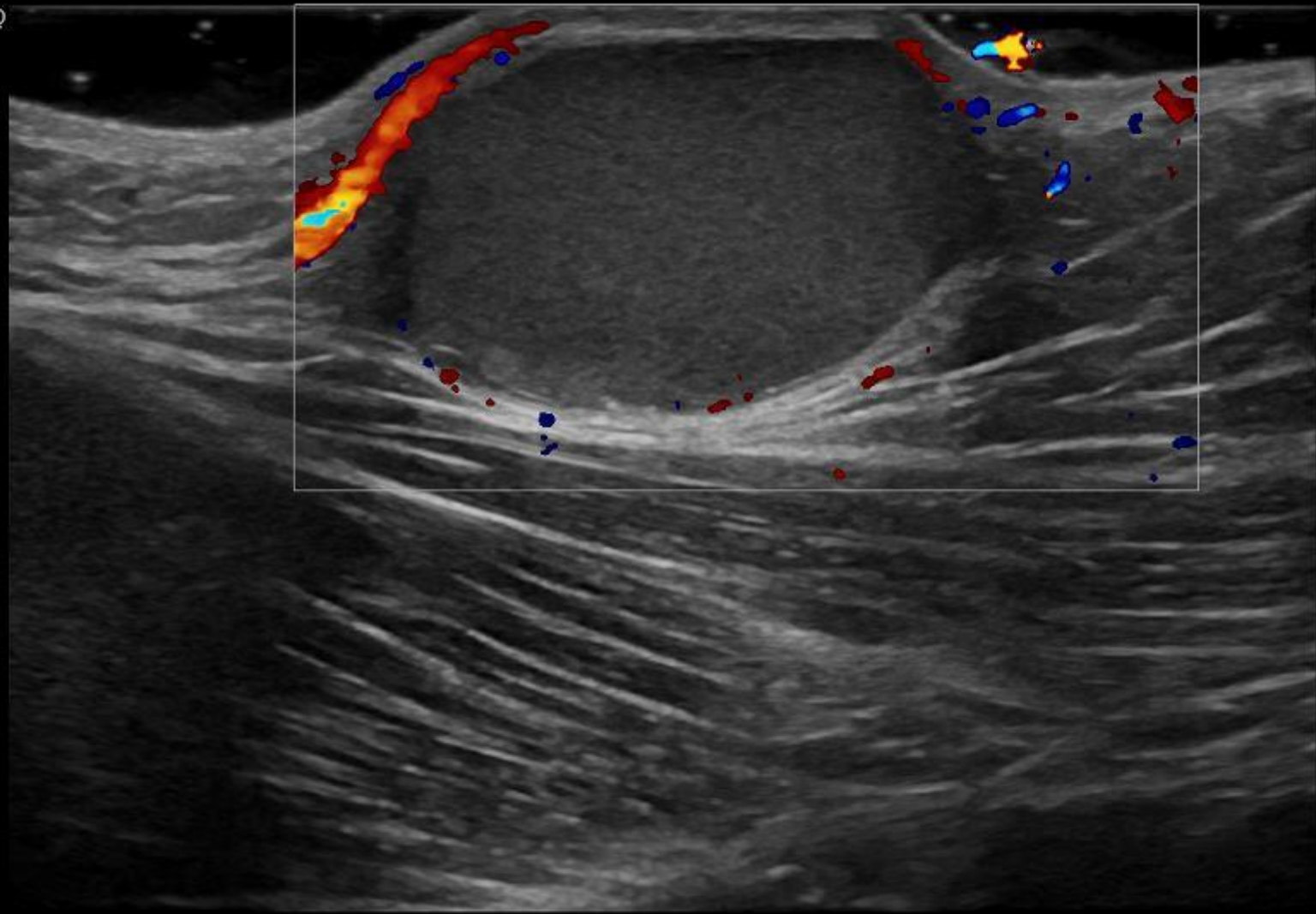
LEFT ANTEROLATERAL HIP LONG

LOGIQ  
E10



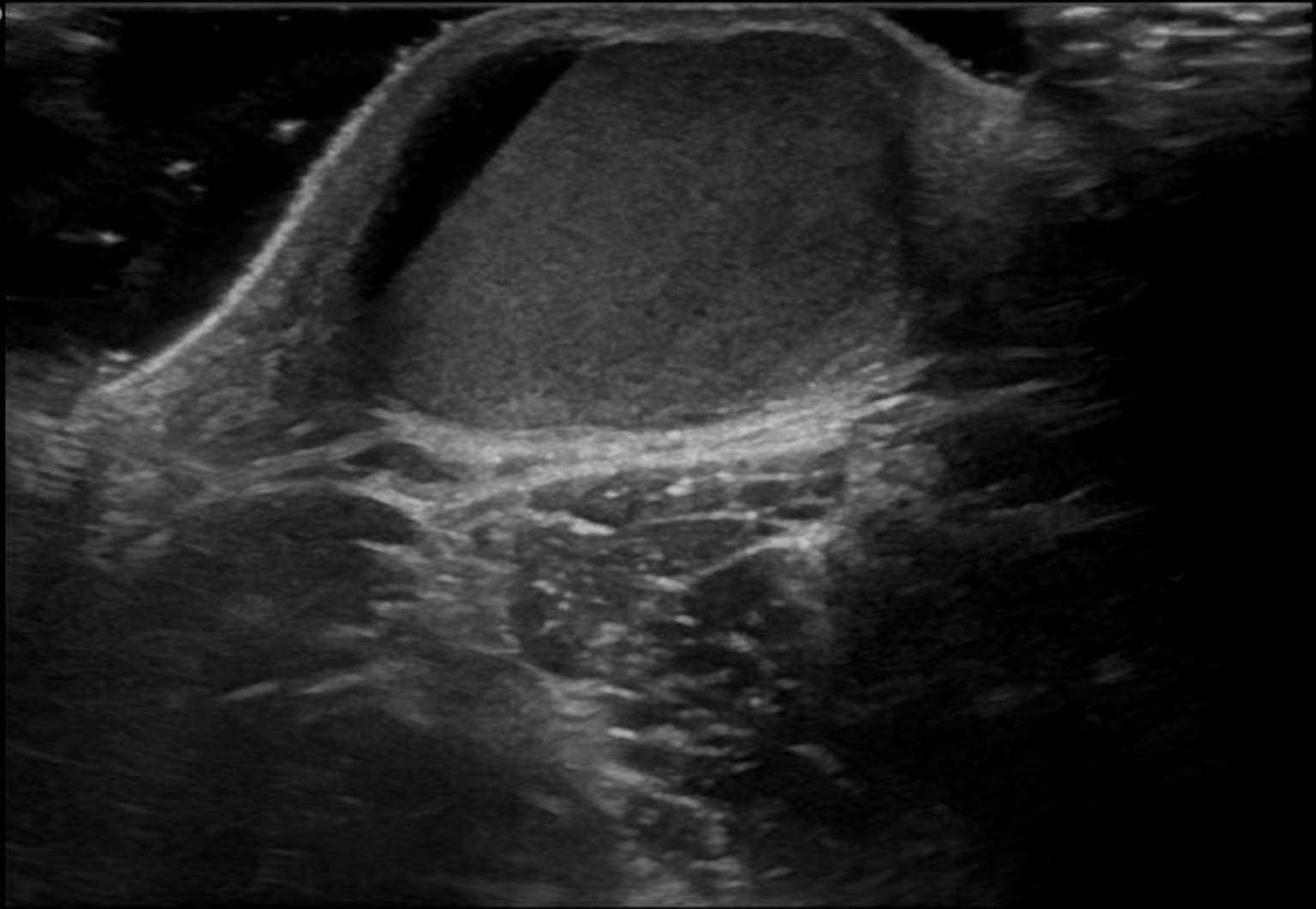
LEFT ANTEROLATERAL HIP LONG

LOGIQ  
E10



**LEFT ANTEROLATERAL HIP LONG**

LOGIQ  
E10

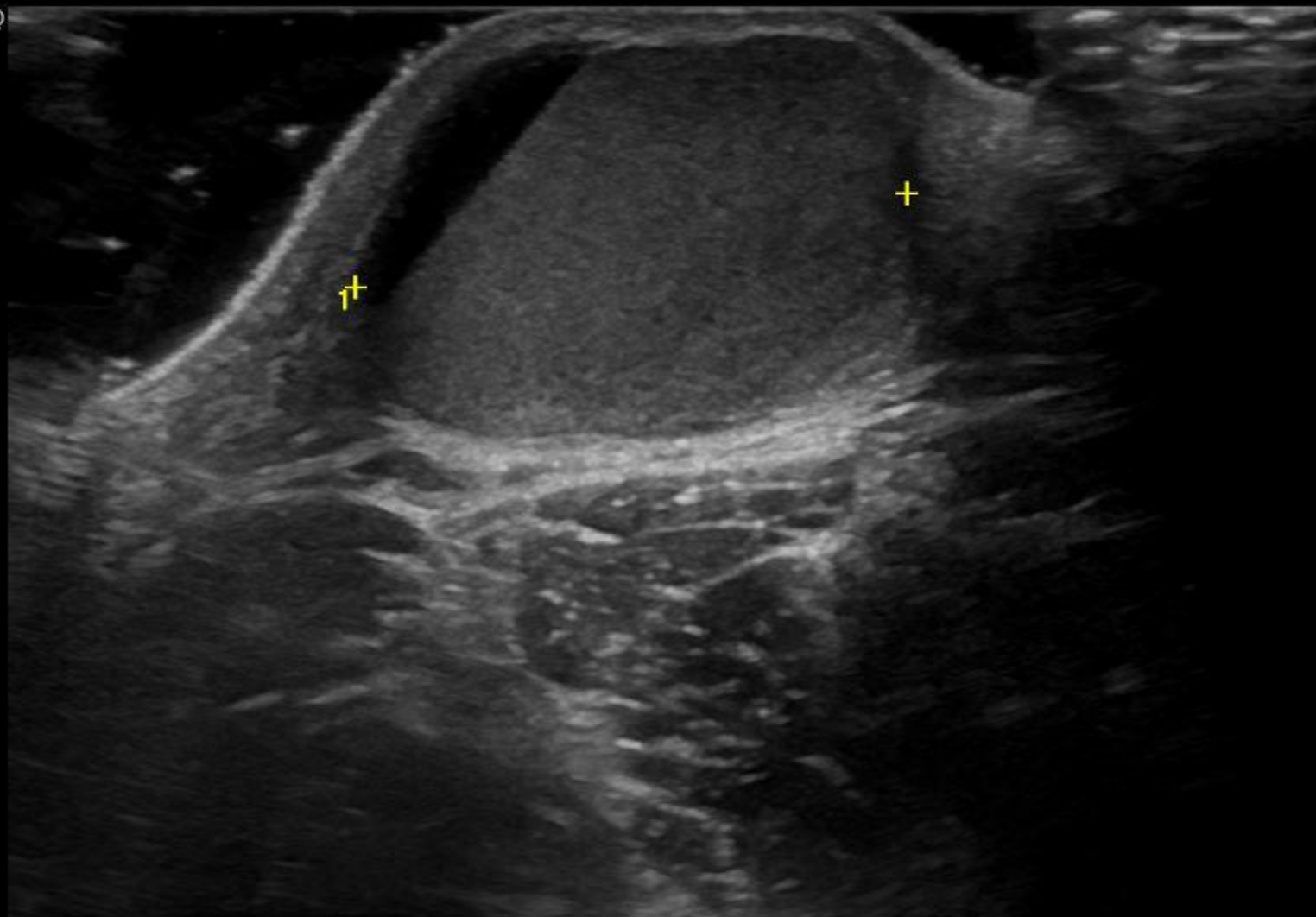

07  
Fr  
-G  
-S  
-M  
D  
-D  
A

1  
-  
-  
-  
-  
-  
3  
-  
L

LEFT ANTEROLATERAL HIP TRANS

LOGIQ  
E10



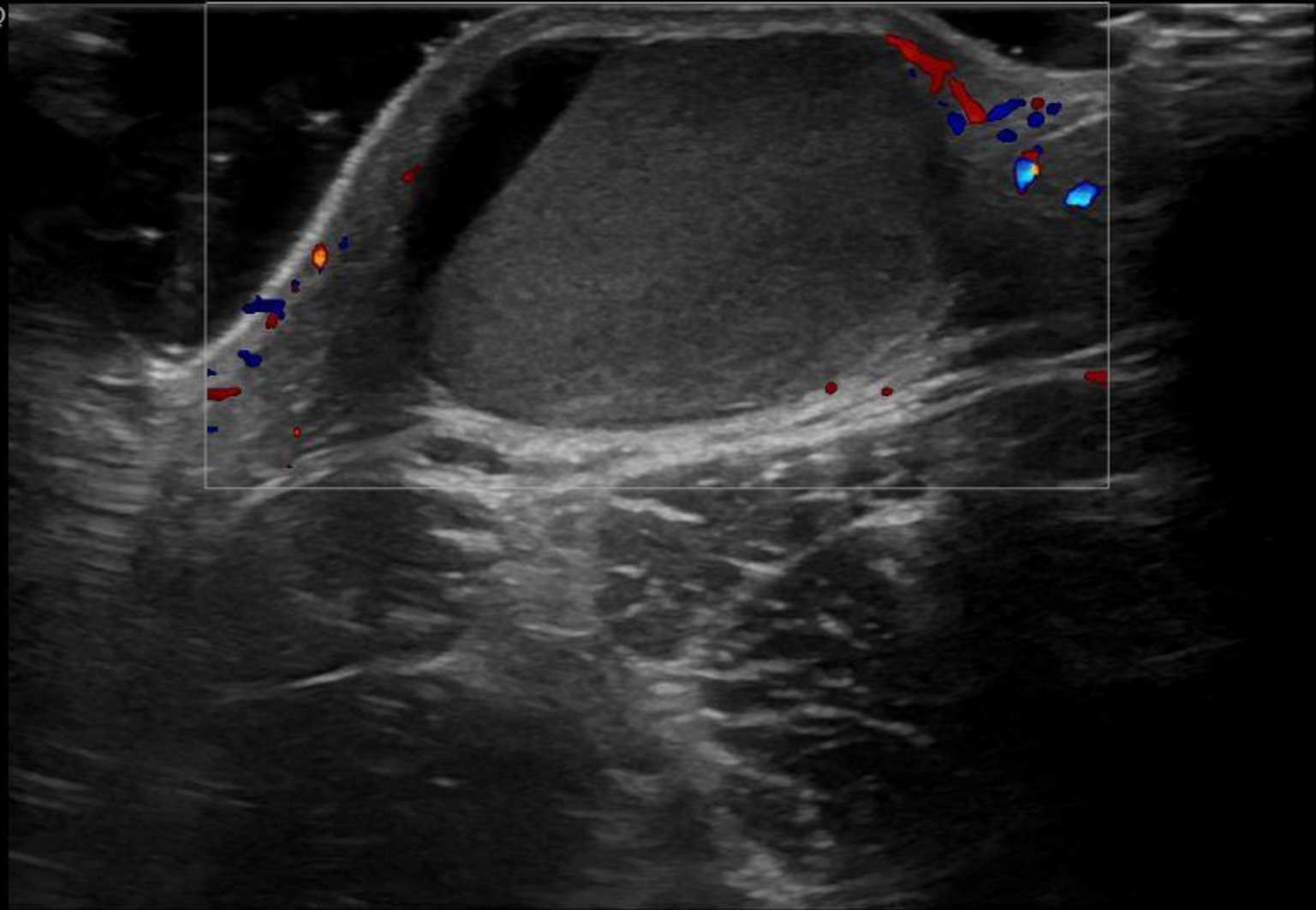
07  
Fr  
- G  
- S  
- M  
- D  
- D  
A  
1  
-  
-  
-  
2  
-  
-  
3  
-  
L J

LEFT ANTEROLATERAL HIP TRANS

1 L 2.14 cm

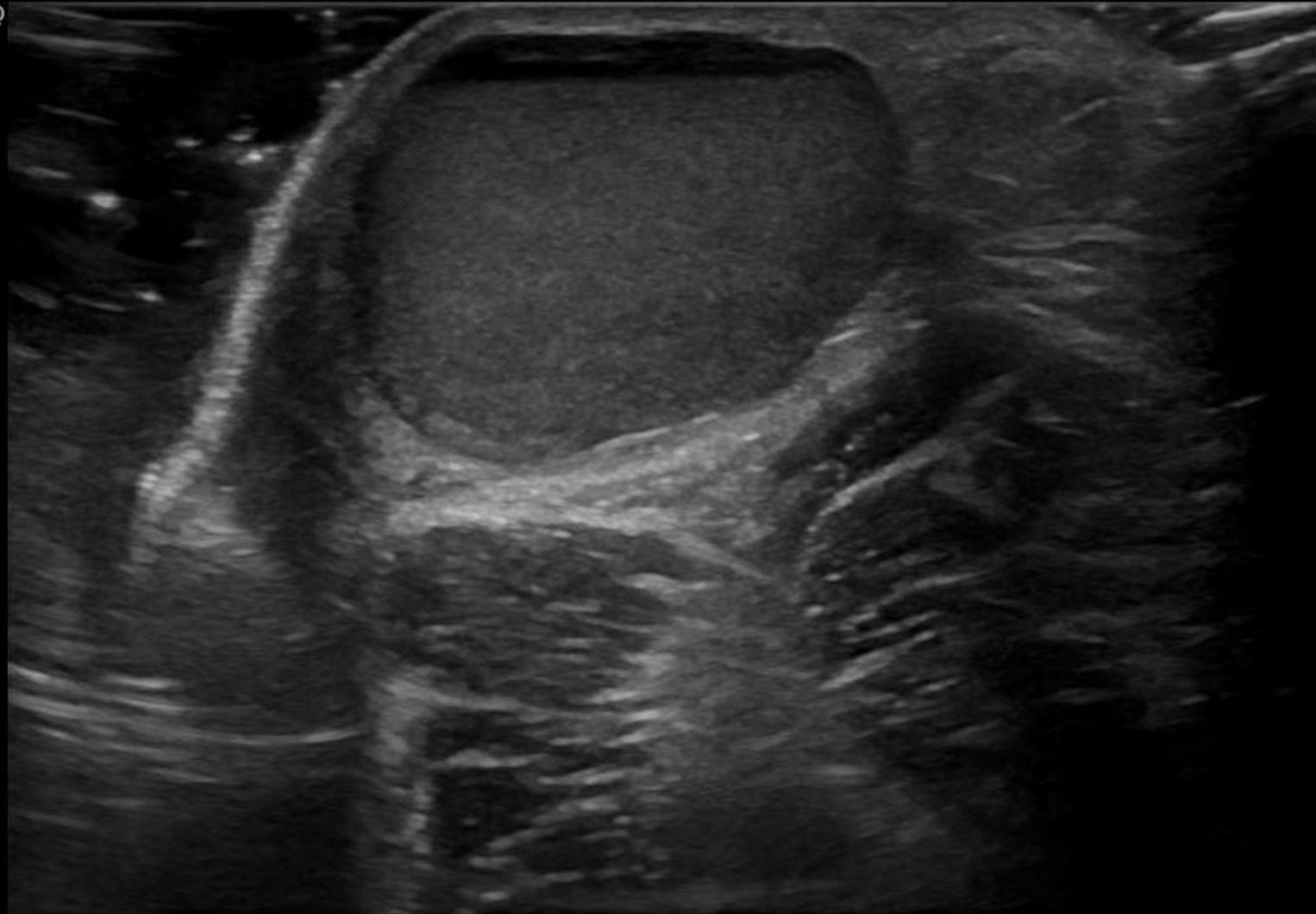


LOGIQ  
E10



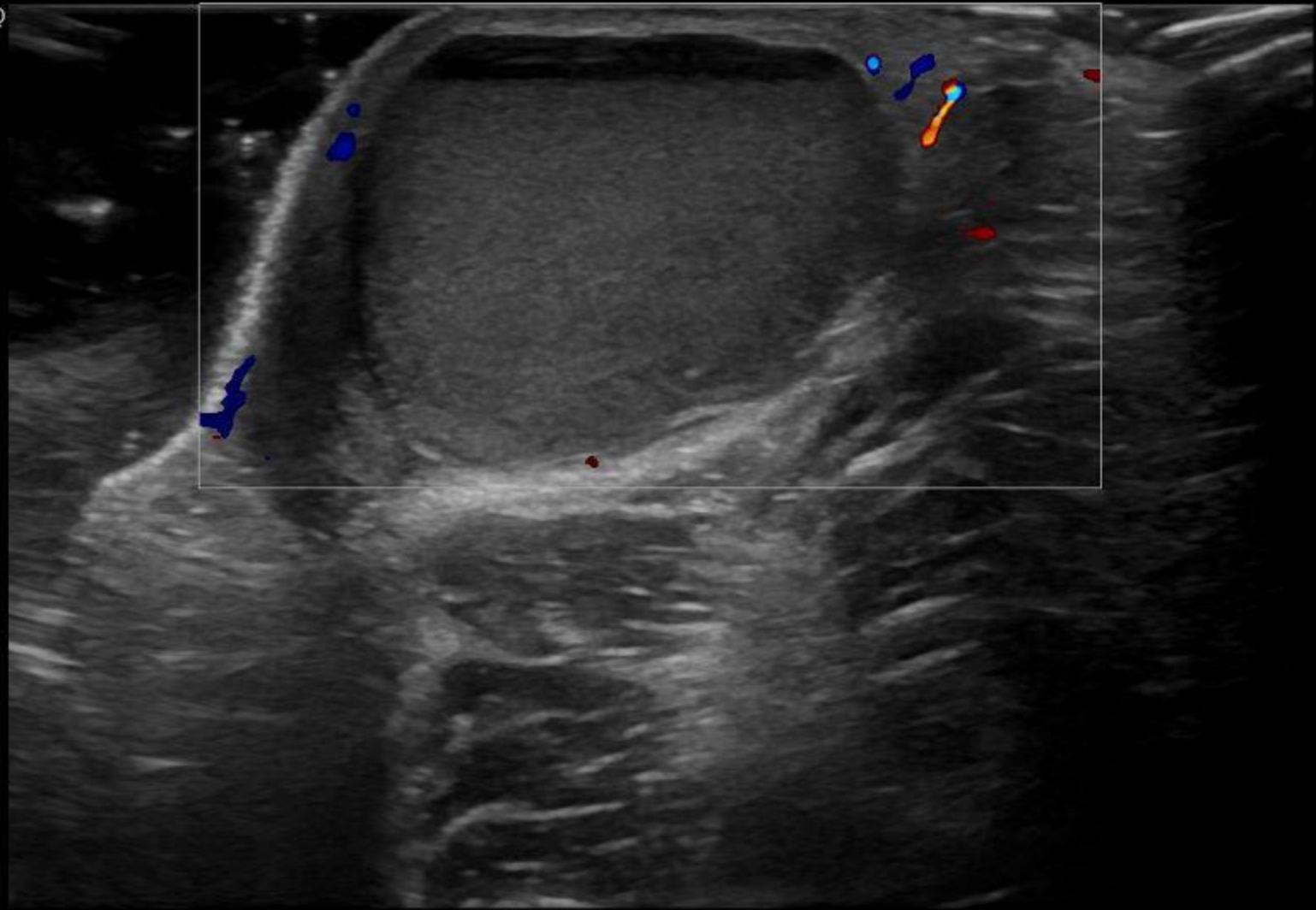
**LEFT ANTEROLATERAL HIP TRANS**

LOGIQ  
E10



**LEFT ANTEROLATERAL HIP TRANS CHANGE IN POSITION**

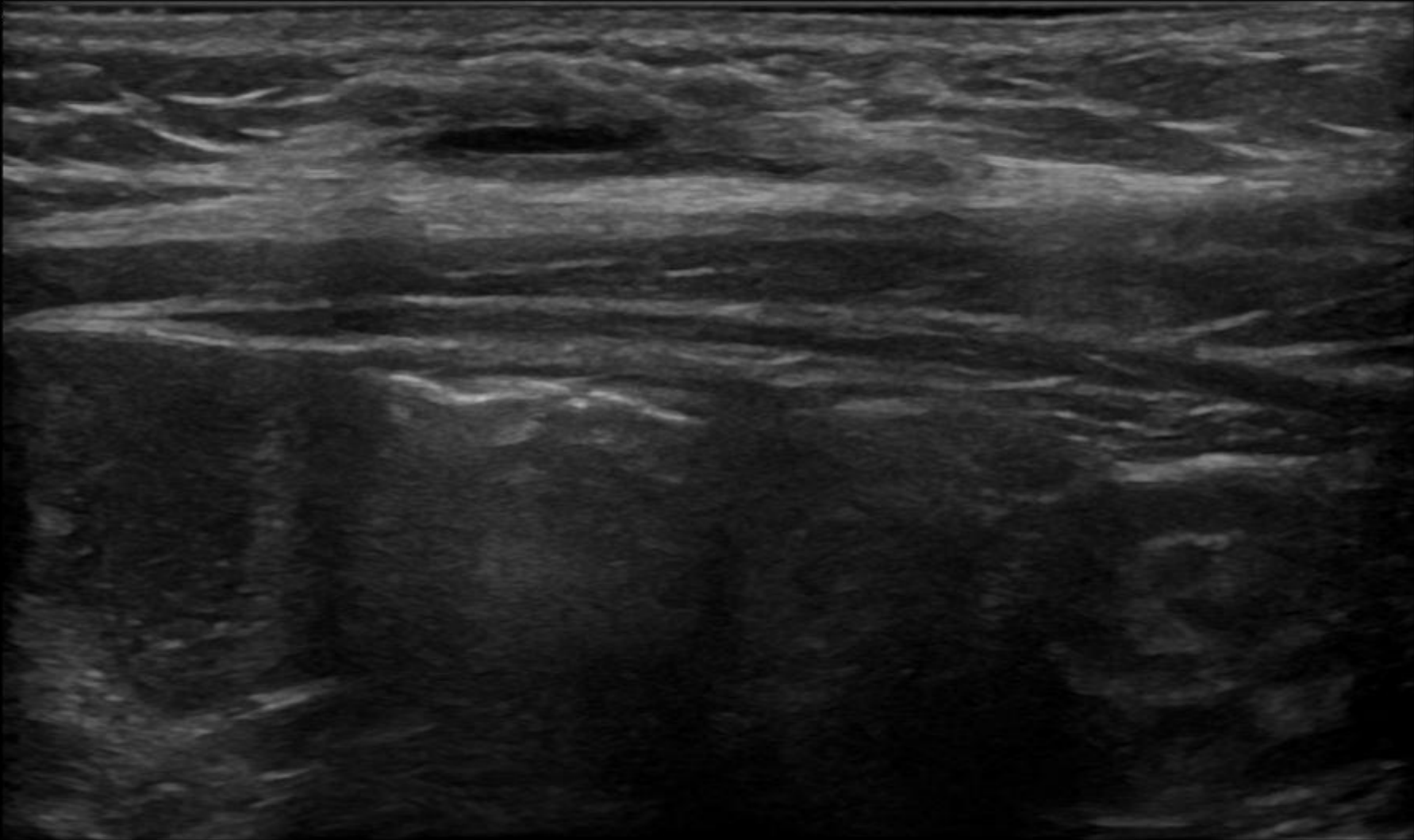
LOGIQ  
E10



**LEFT ANTEROLATERAL HIP TRANS CHANGE IN POSITION**

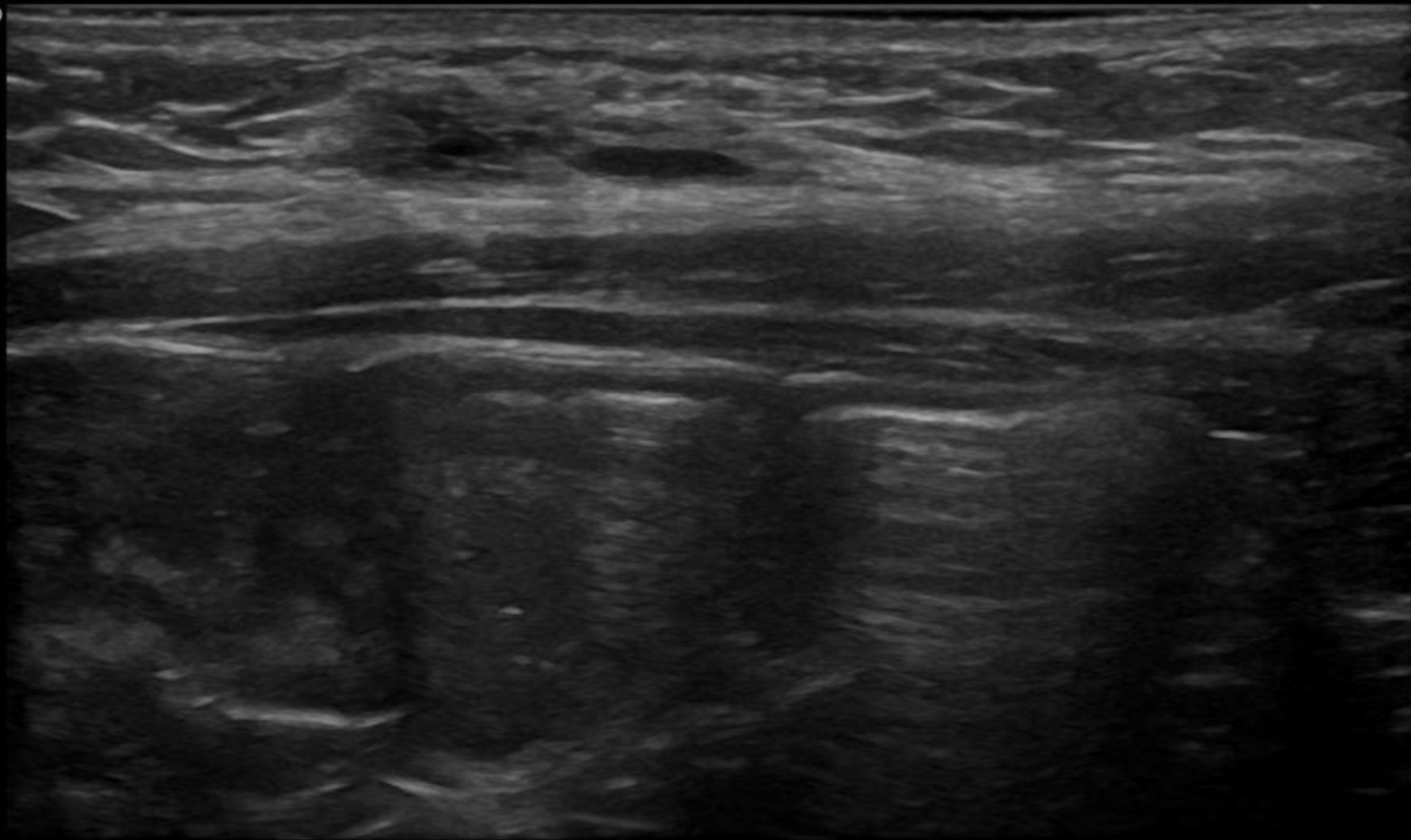
Abdominal wall palpable abnormality, ~2 cm  
superior to hip mass

LOGIQ  
E10



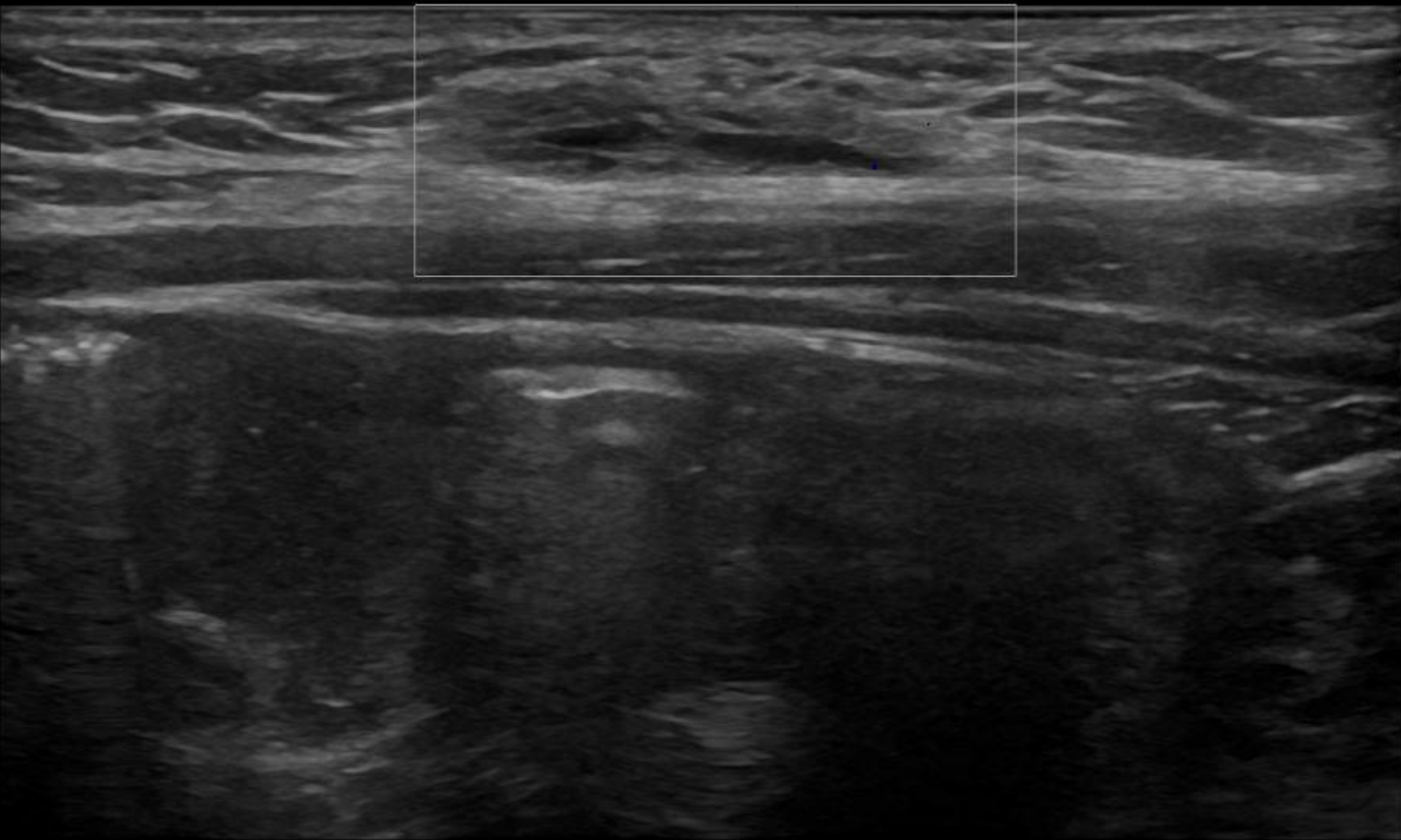

LEFT ANT ABDOMINAL WALL TRANS

LOGIQ  
E10



LEFT ANT ABDOMINAL WALL TRANS

LOGIQ  
E10



07  
Fr  
G  
D  
A  
-  
C  
-Fr  
G  
1 L  
P  
W  
-S  
A  
-  
-  
-  
-  
-  
L 3J

LEFT ANT ABDOMINAL WALL TRANS