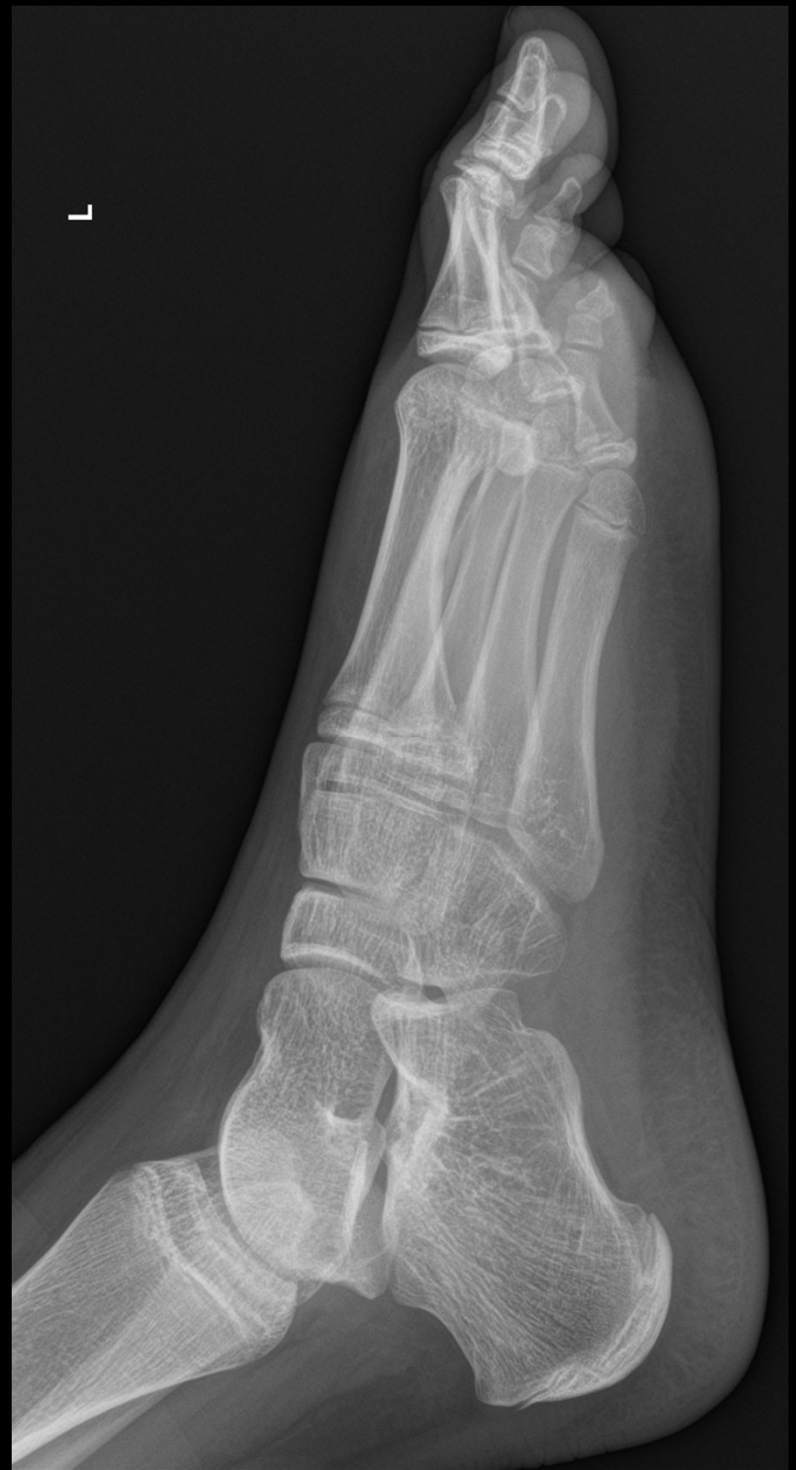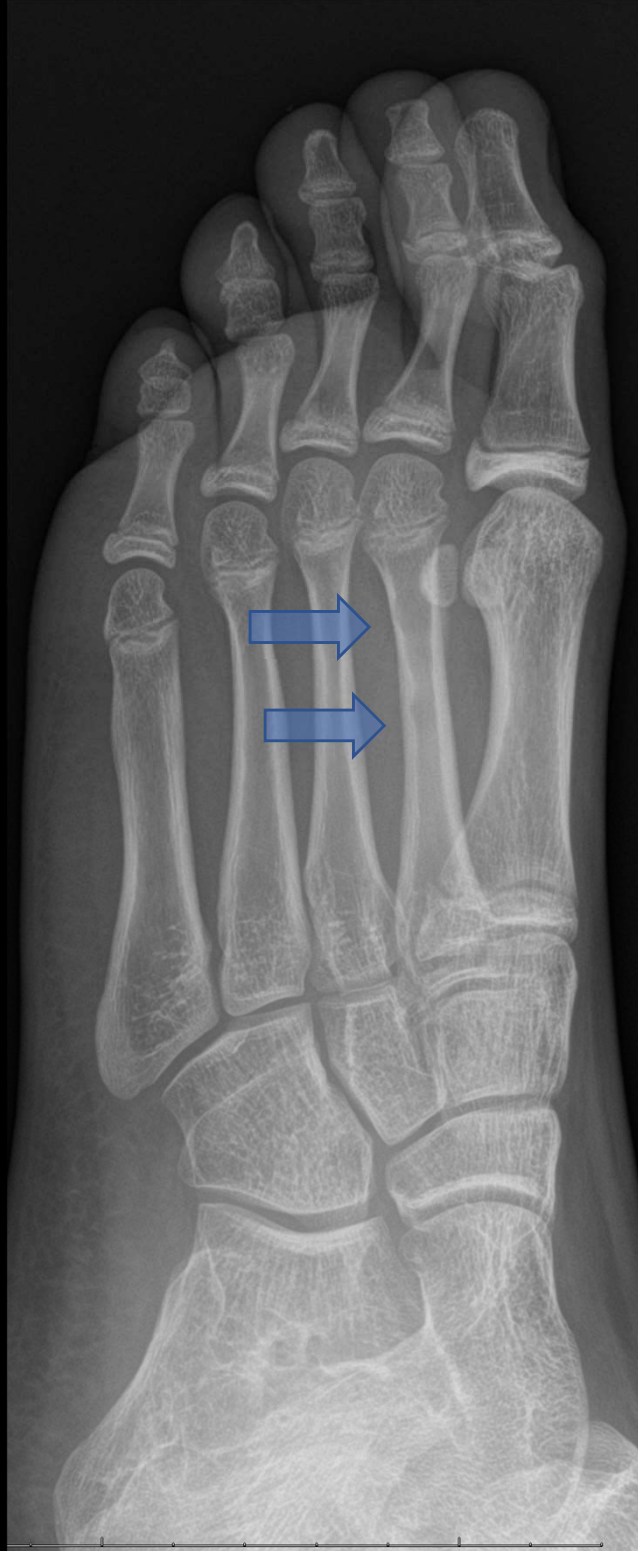
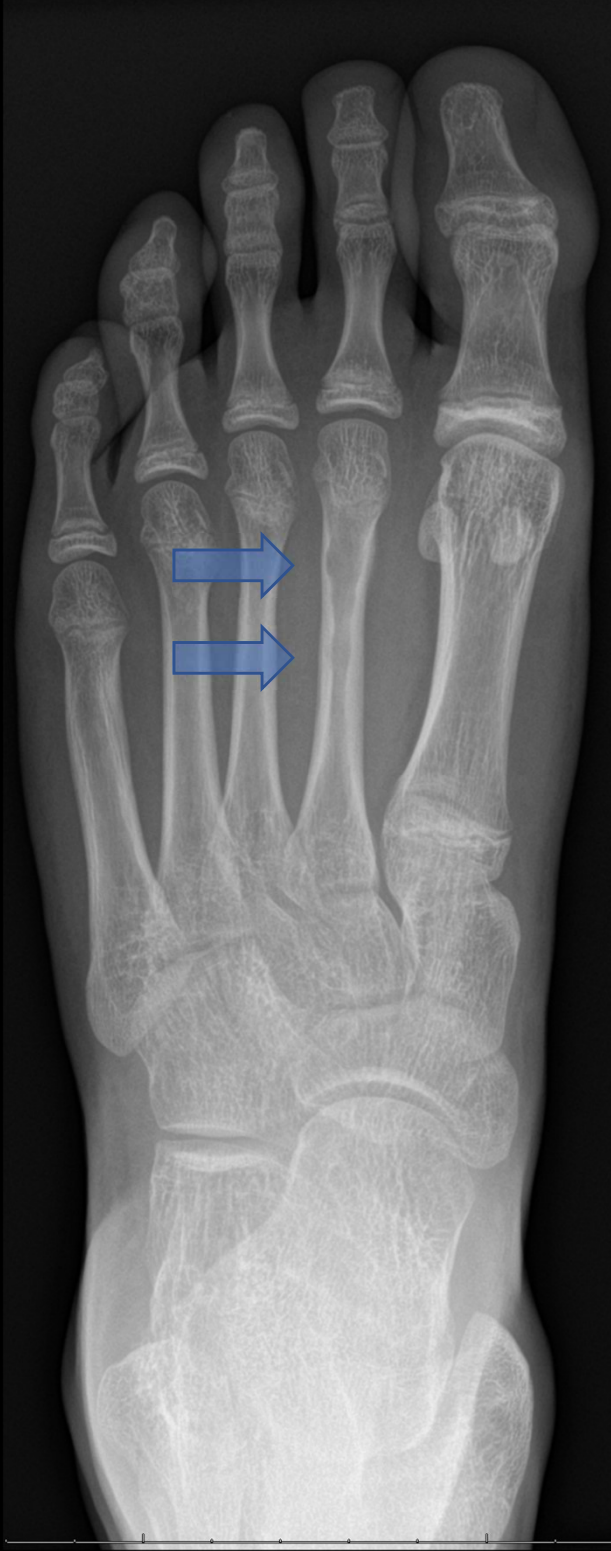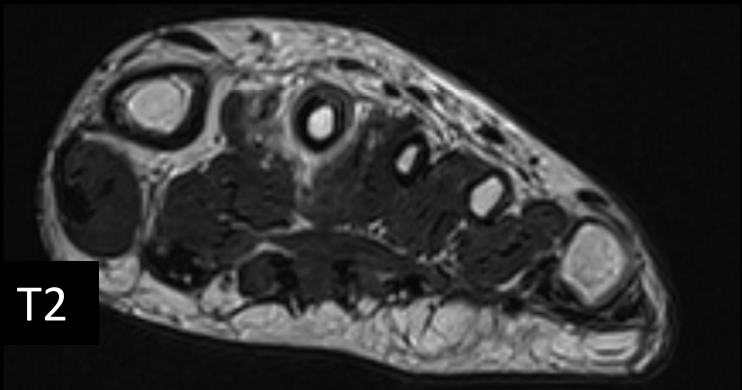
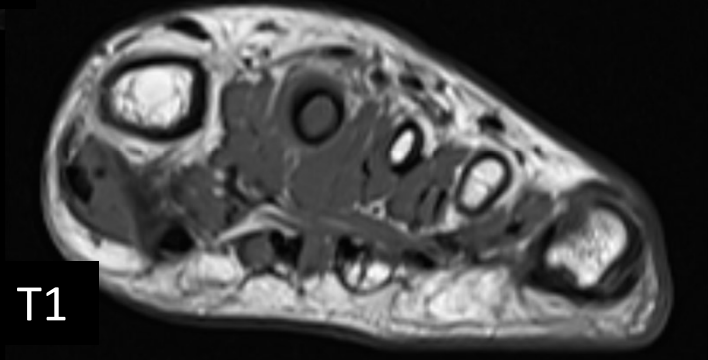
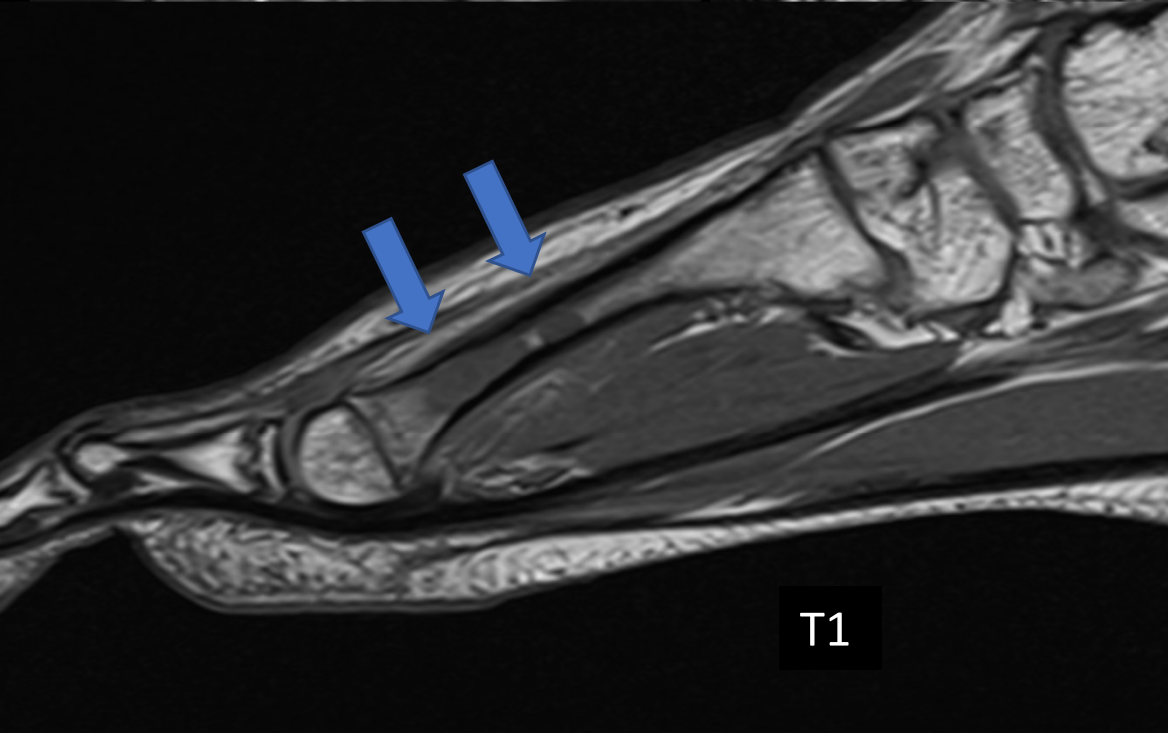
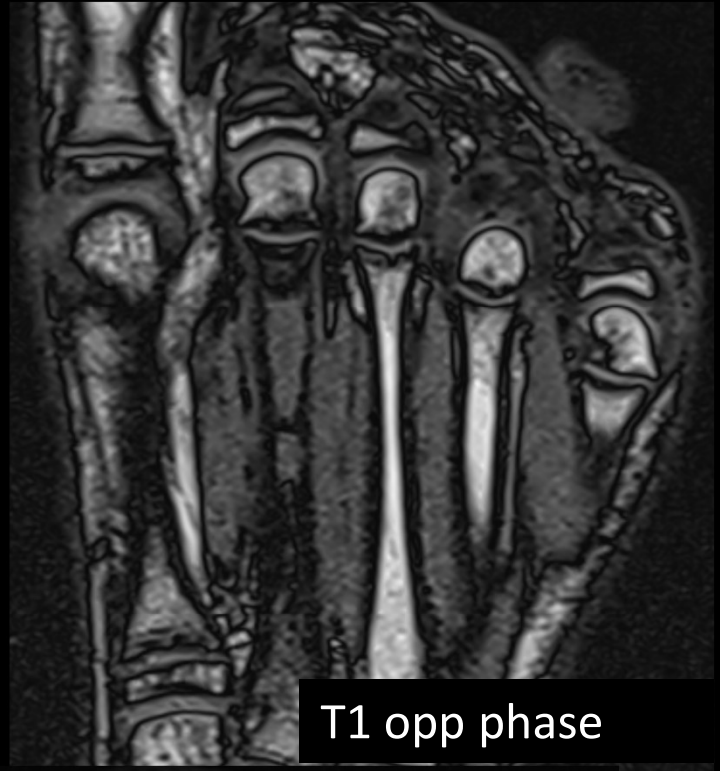


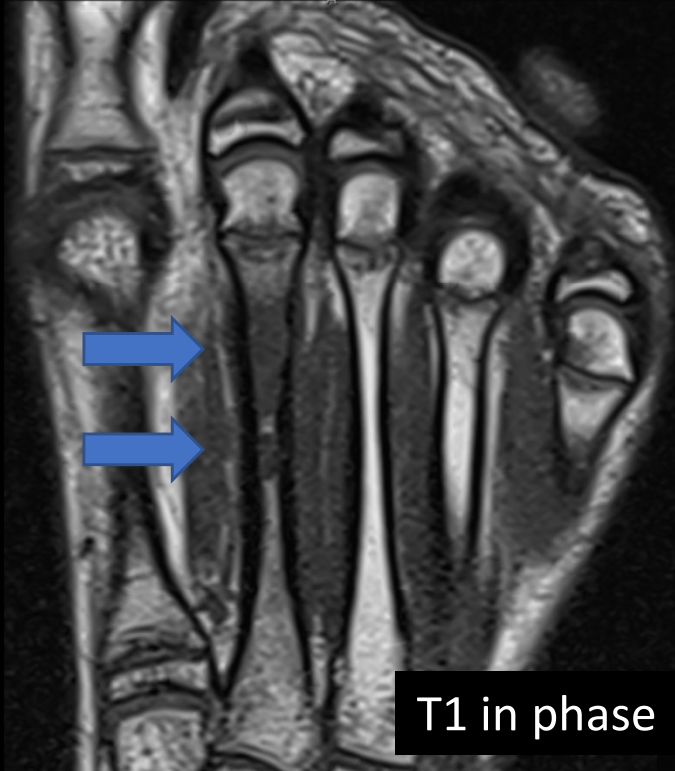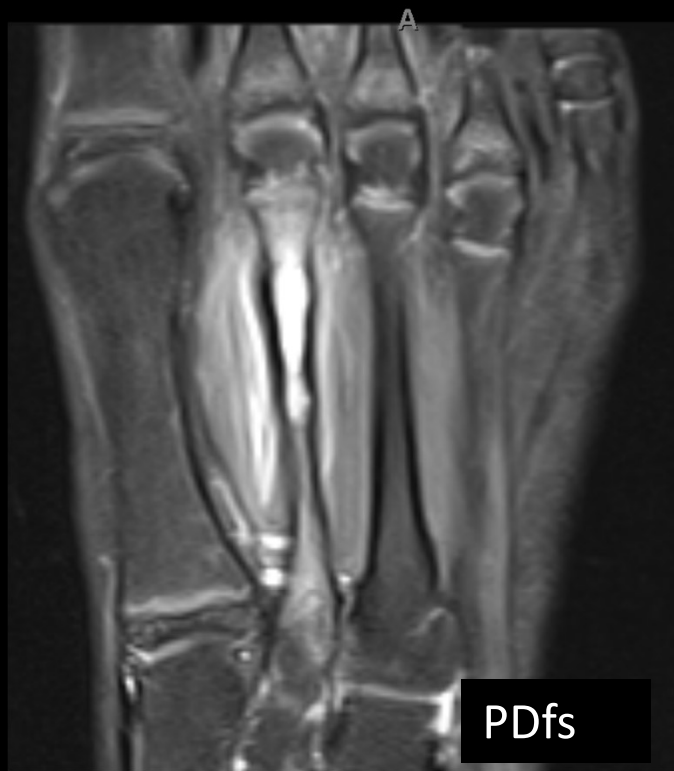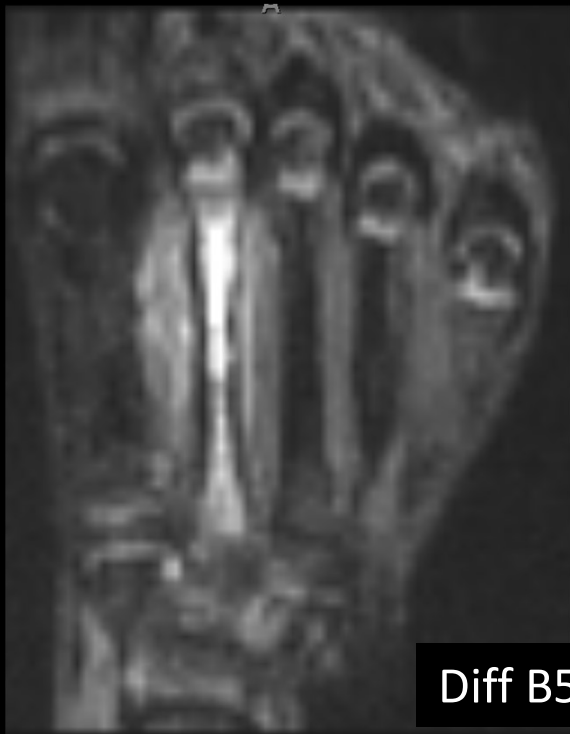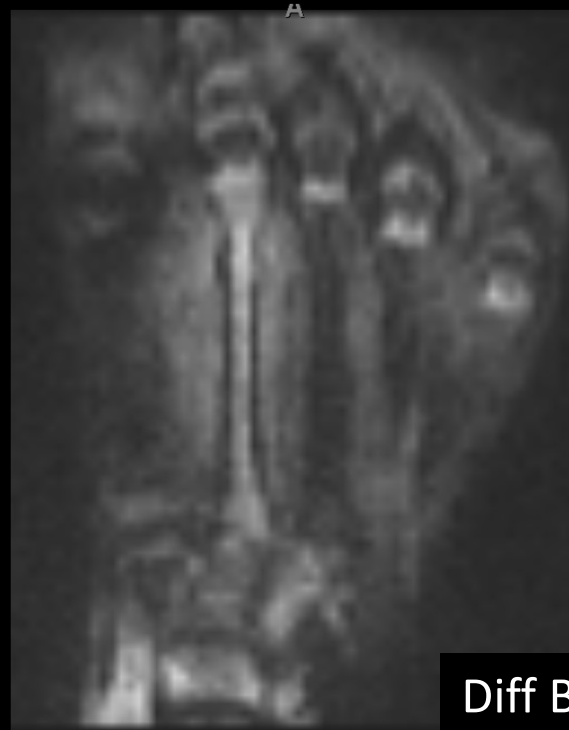- 13 year old girl
- atraumatic pain in the midfoot
- Ballet dancer, rule out fatigue fracture
- Xray: endosteal scalloping
- MRI:
  - Bone marrow replacement with skip lesion
  - No fracture line
  - Periosteal reaction with soft tissue edema
  - No signs of high cellularity in T2 and diffusion
  - No contrast enhanced acquisition available
- Question:
  - What is the most likely diagnosis?
  - CRMO? Langerhans? Ewing?







Diff B50



Diff B600



Diff B1200 (calc)



ADC