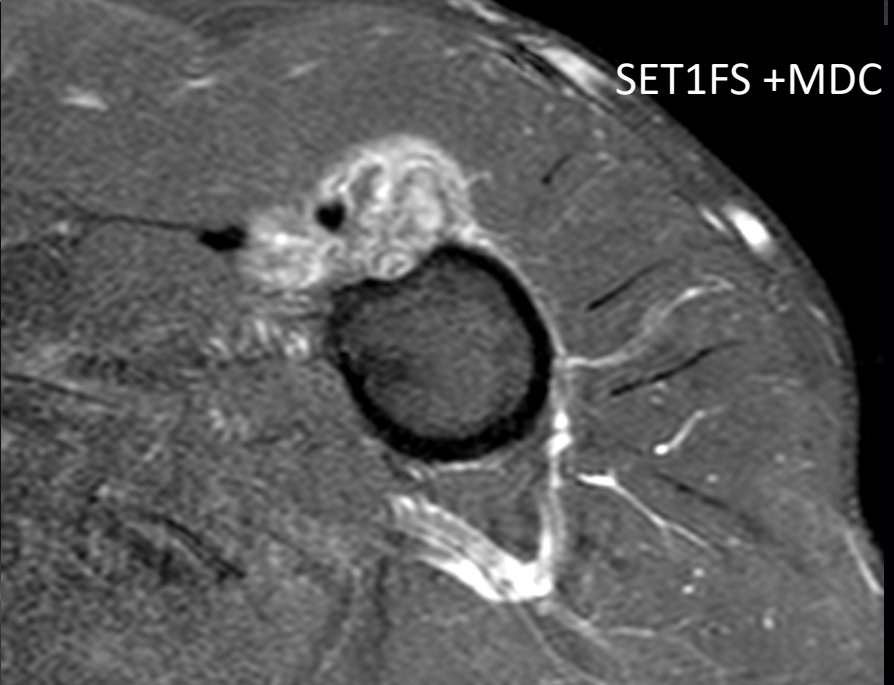
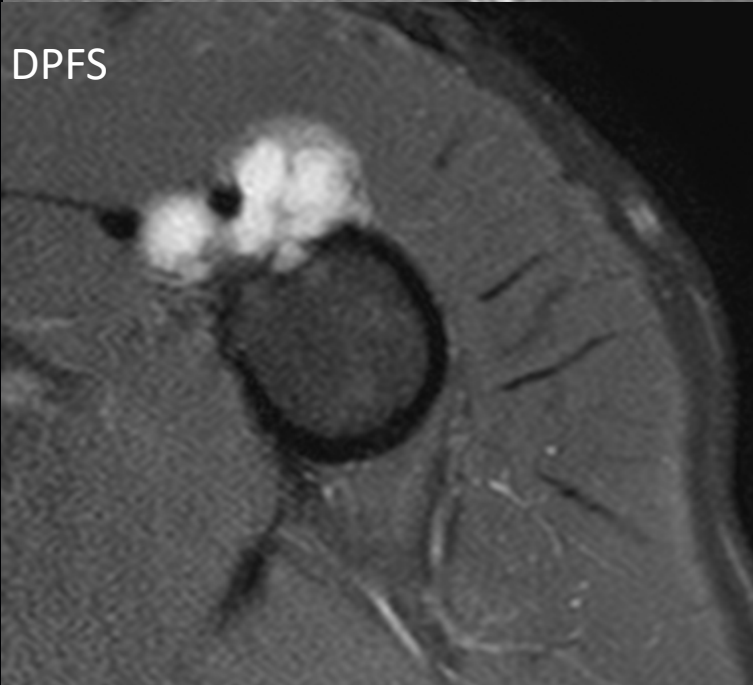
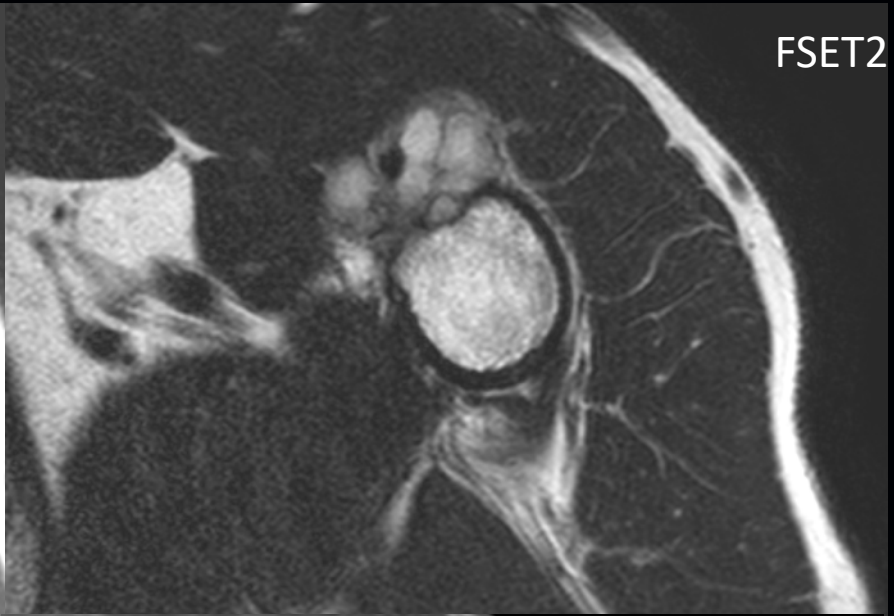
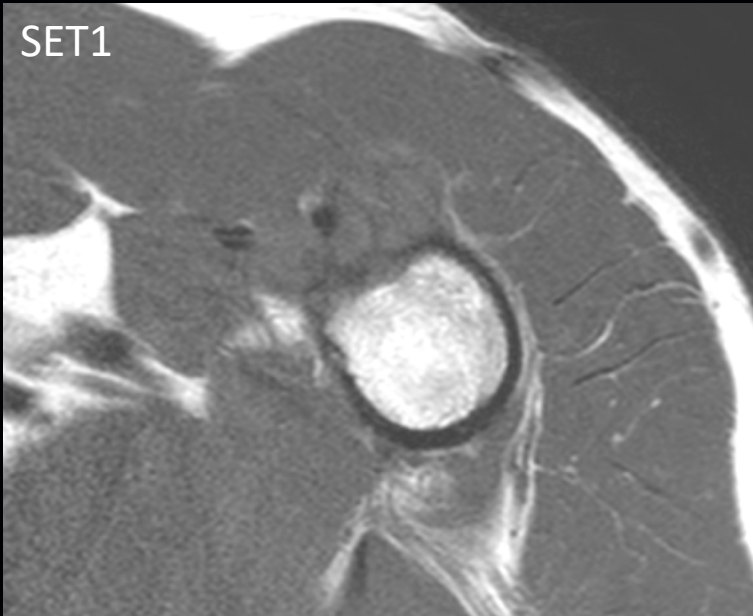


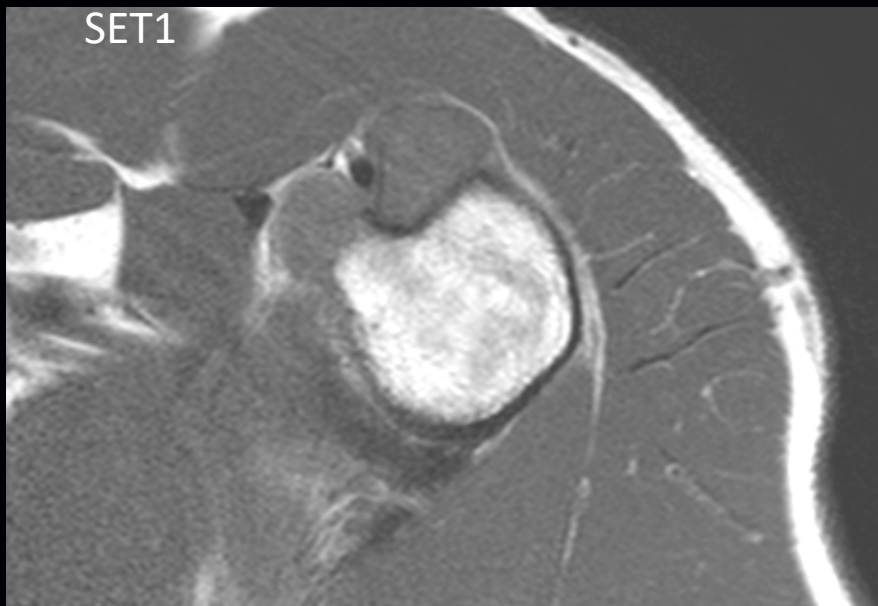
35 year old men with painless swelling of the shoulder (LHB area) for about 7 months.

The orthopedist asked for a rotator cuff tear.

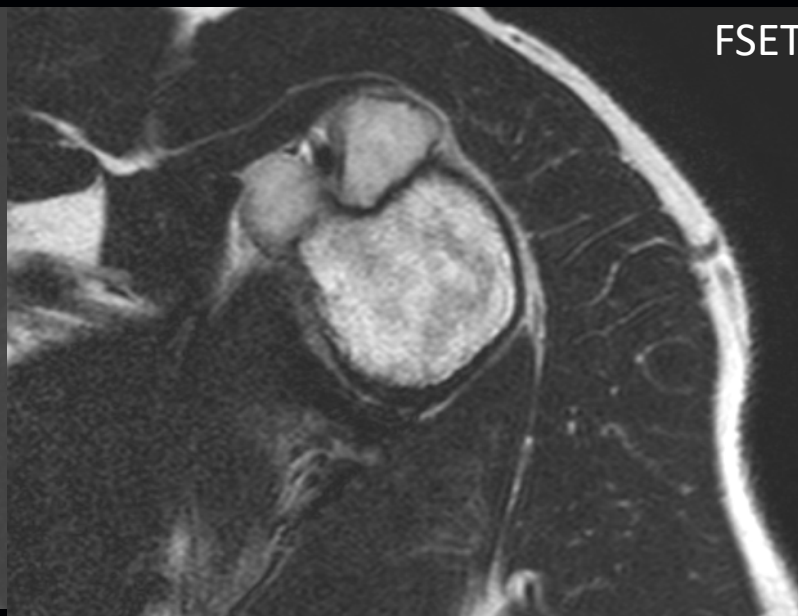
The patient had a shoulder ultrasound 2 years ago (...I do not have the images or the report !!!) of which he tells a modest and unspecified inflammation of the biceps and rotator cuff.



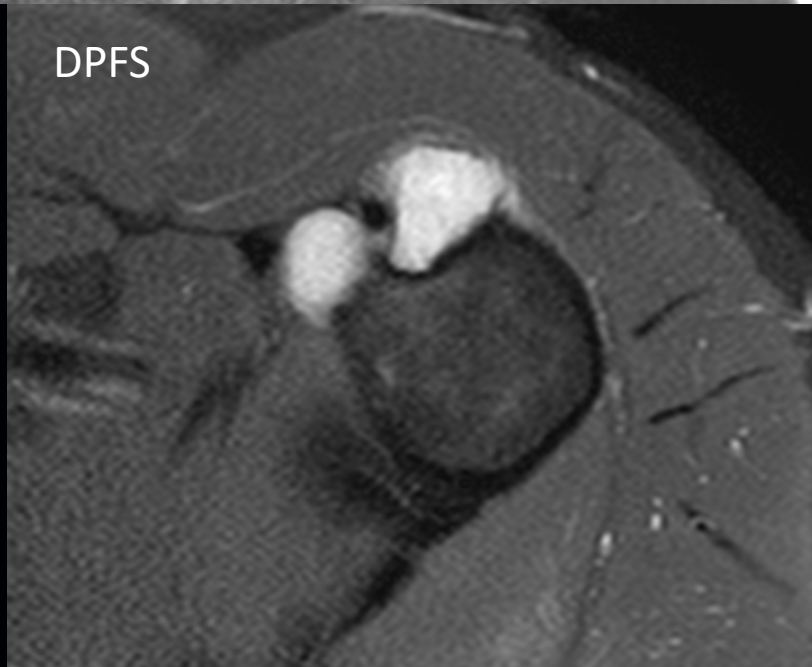
SET1



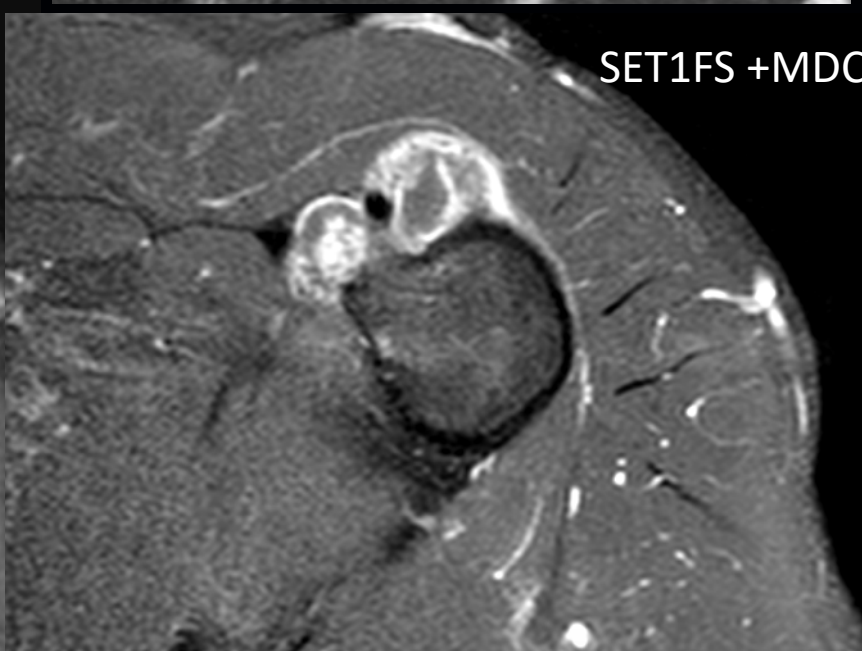FSET2



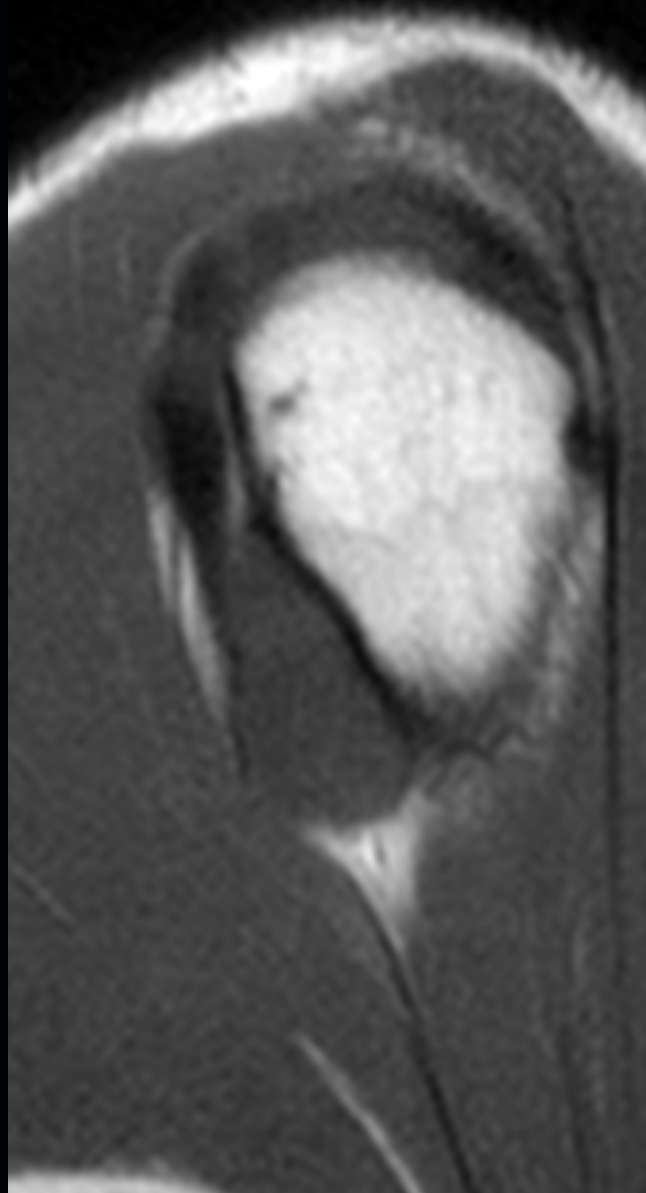
DPFS



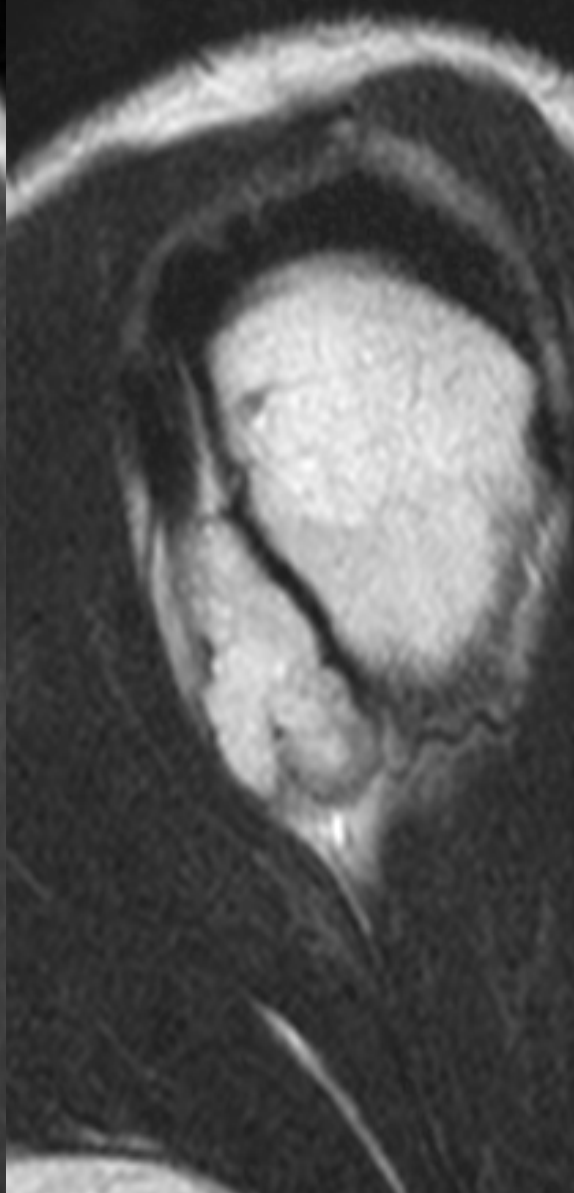
SET1FS +MDC



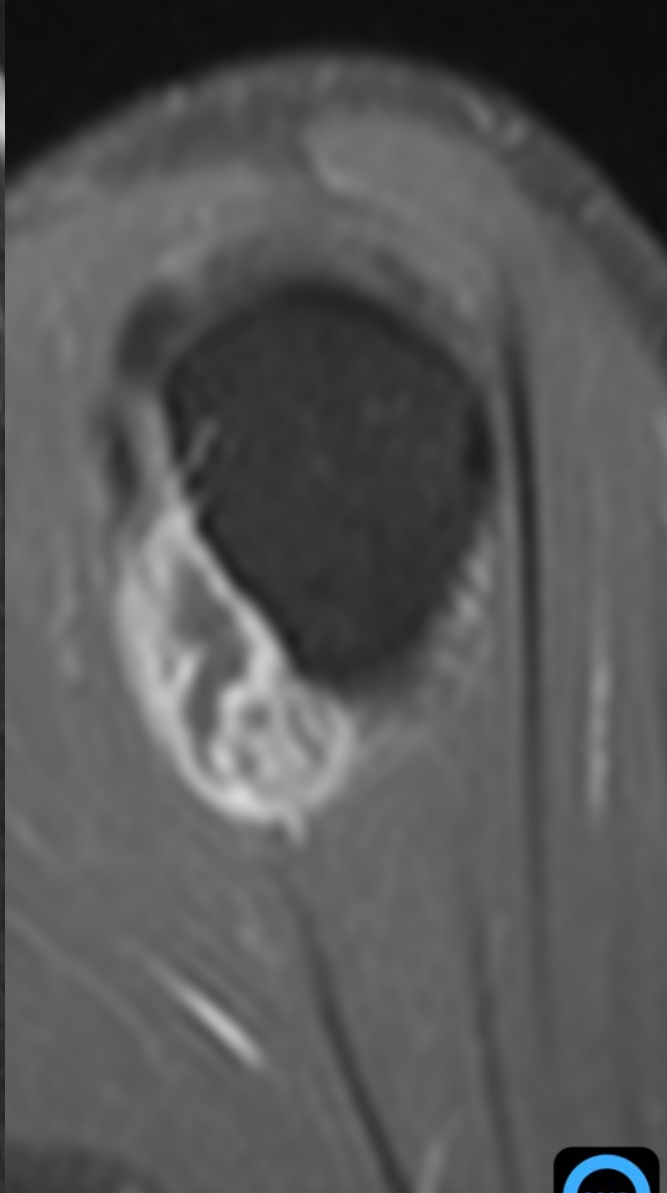
SET1



FSET2

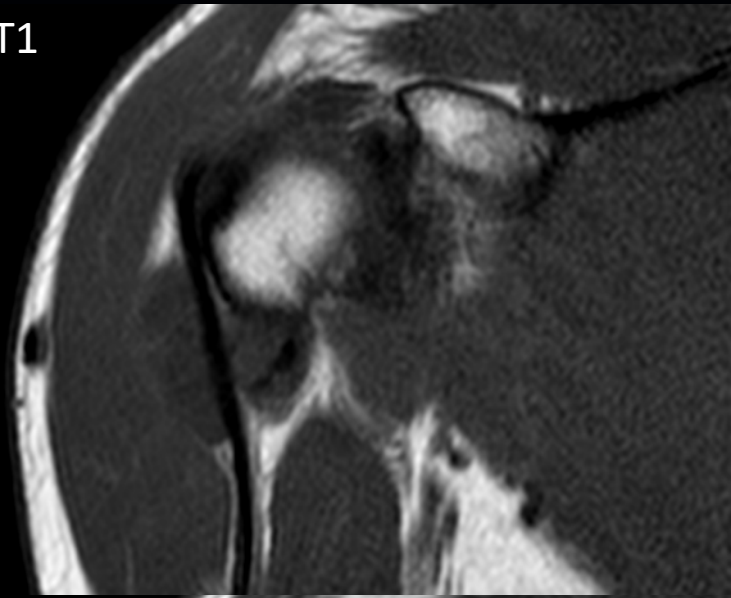


SET1FS +MDC





SET1



SET1 +MDC

