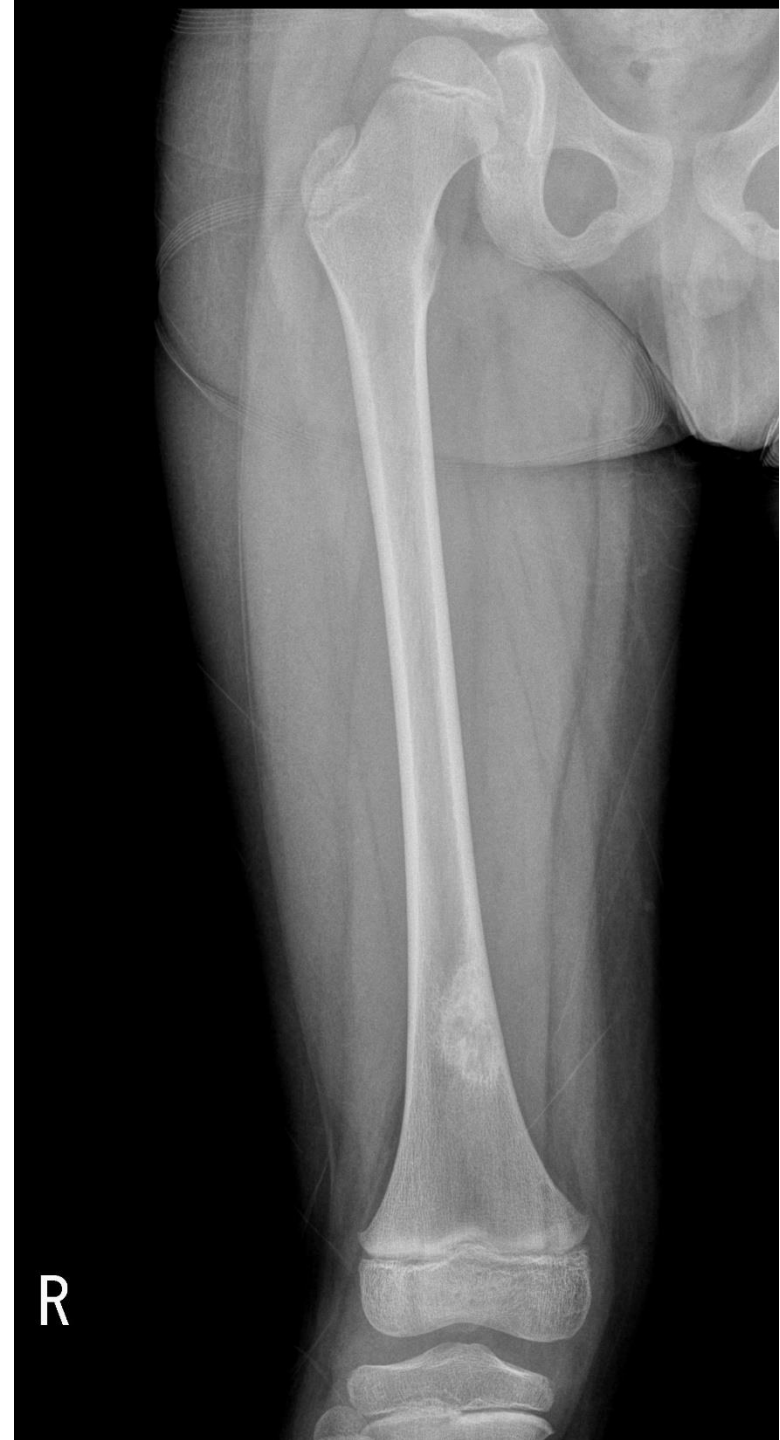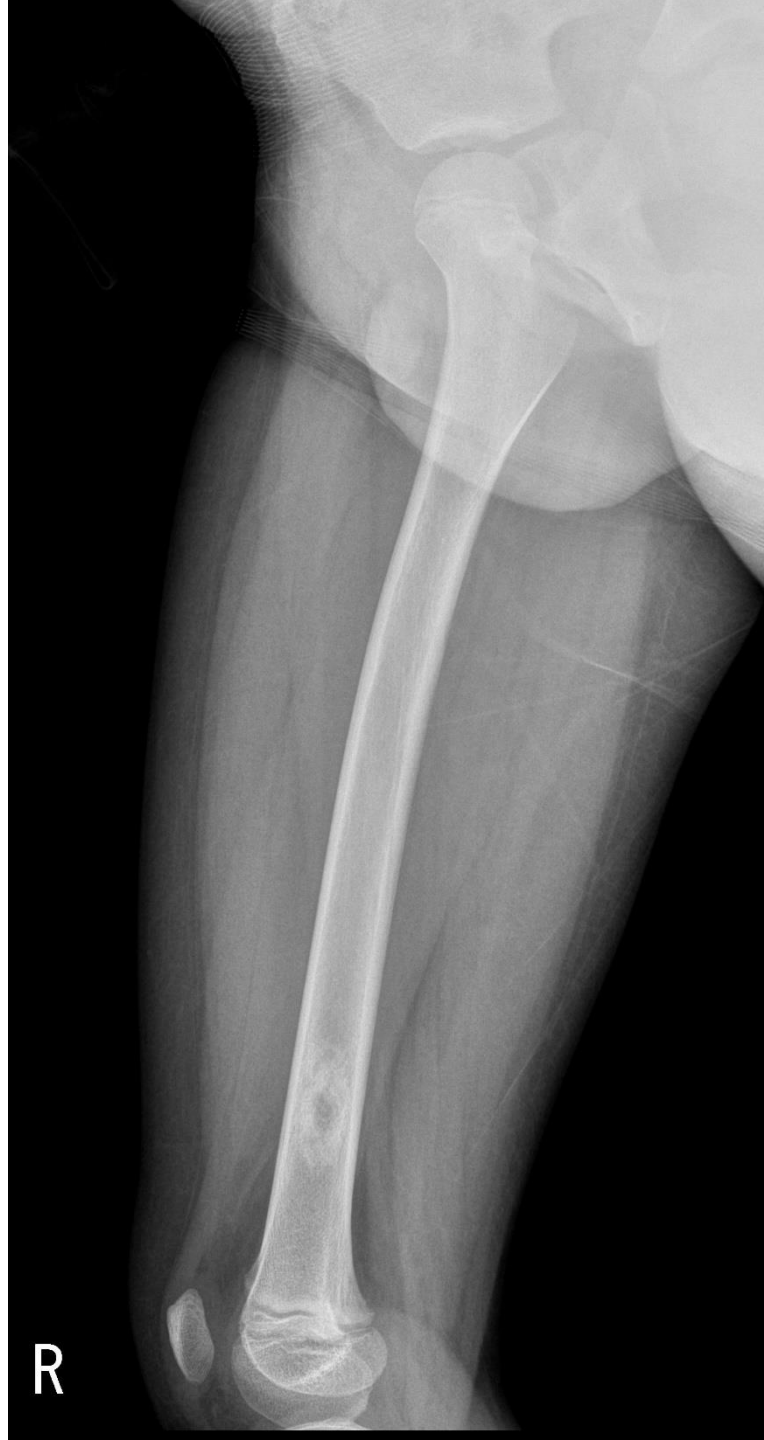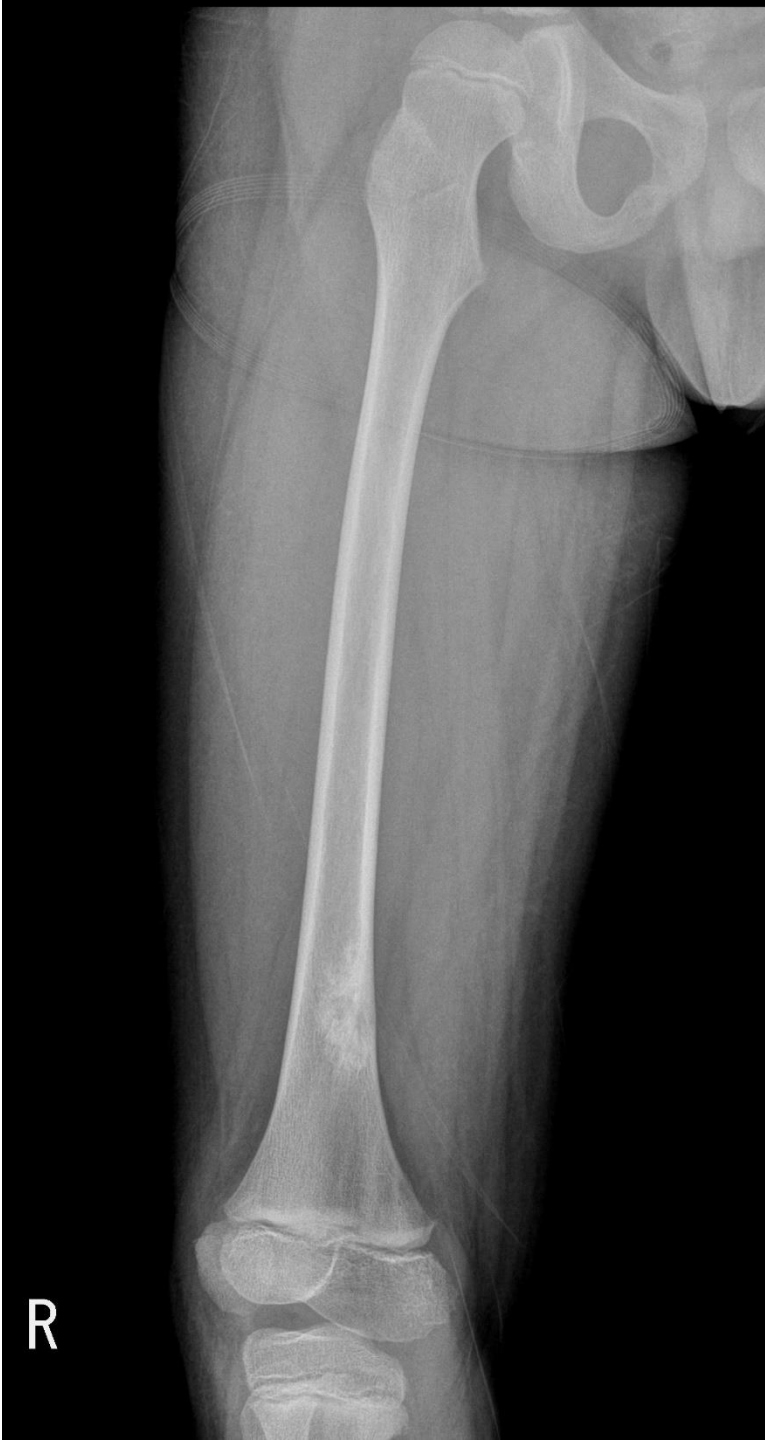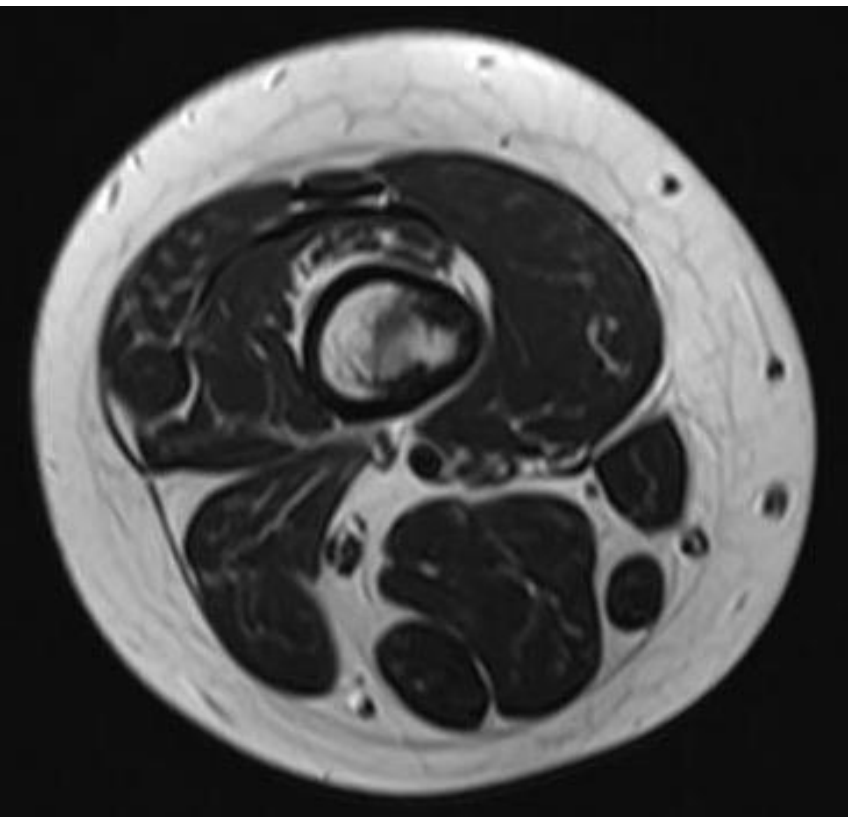


M/7
incidental bone lesion on
scanogram

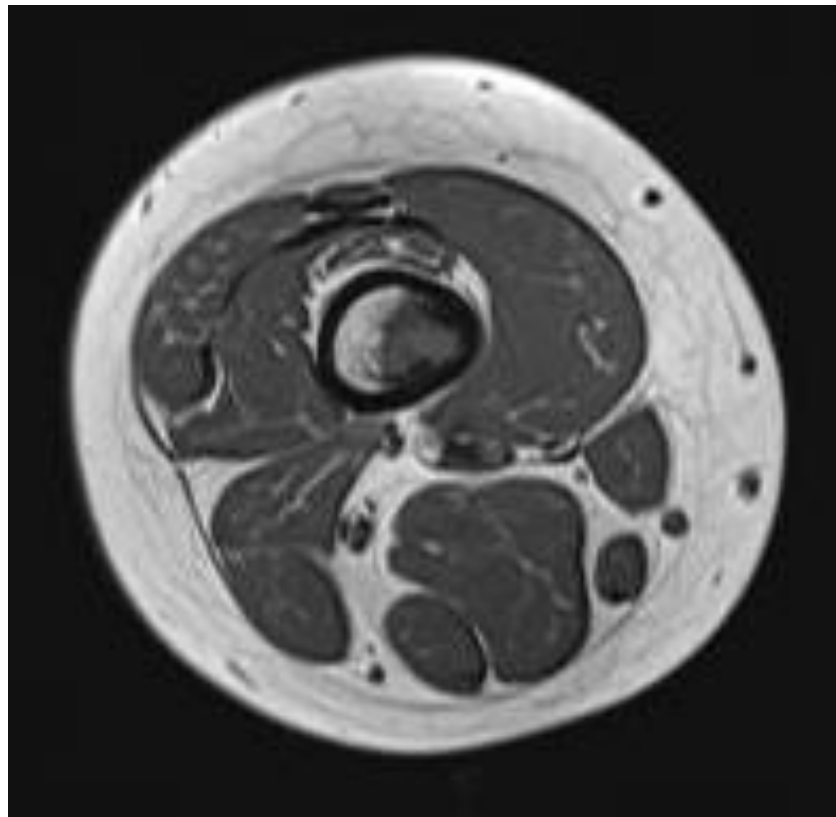
Family history: neurofibromatosis

Medical history: transient synovitis, right hip

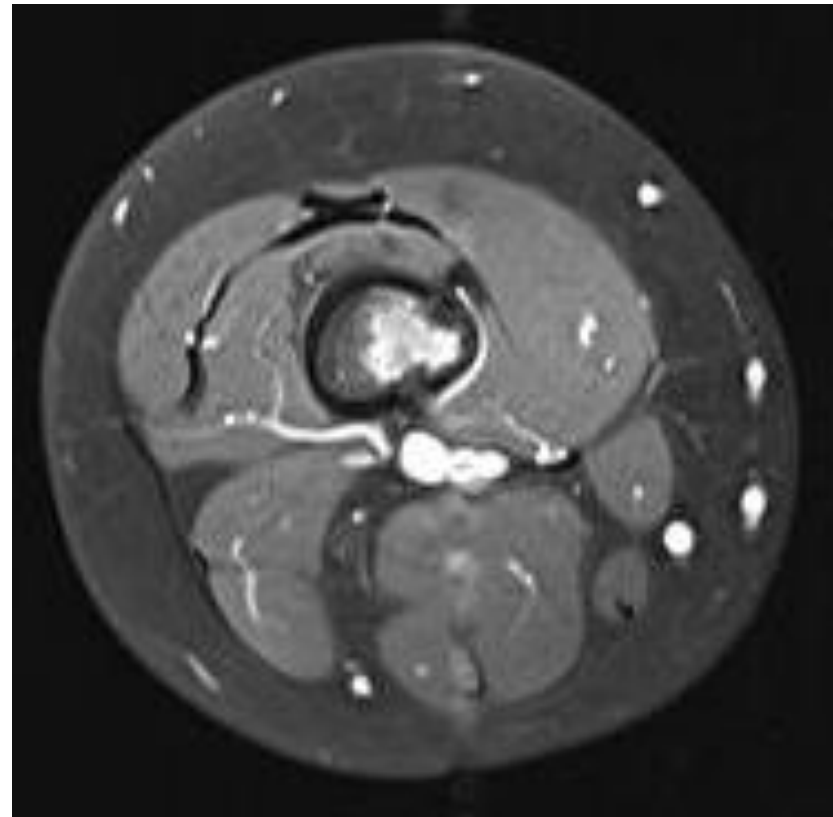




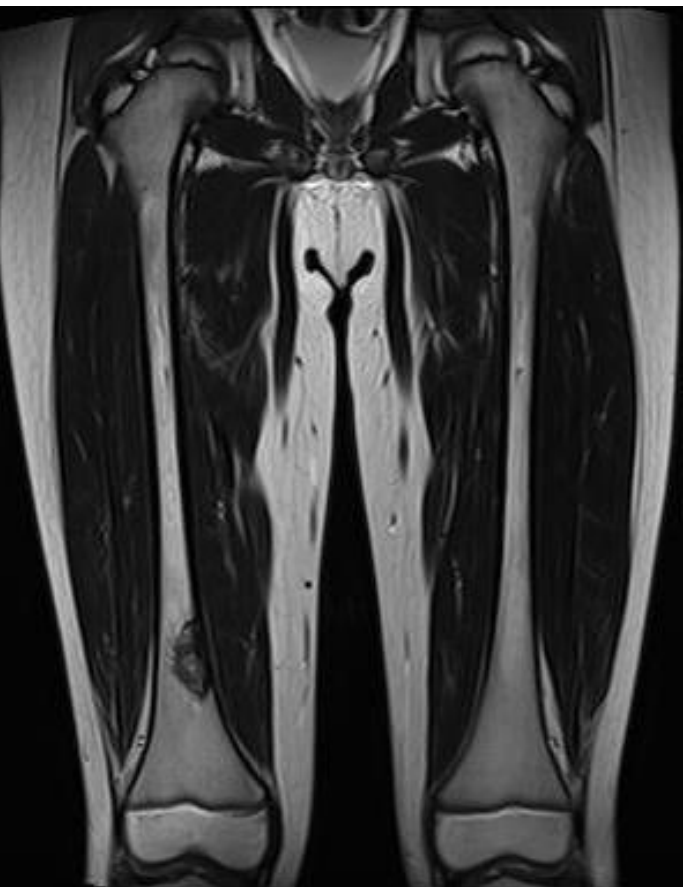T2



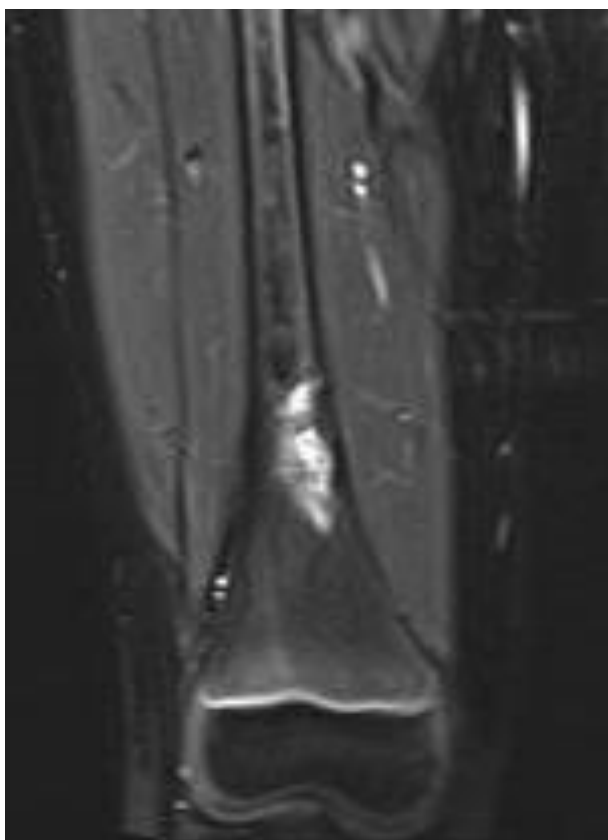
T1



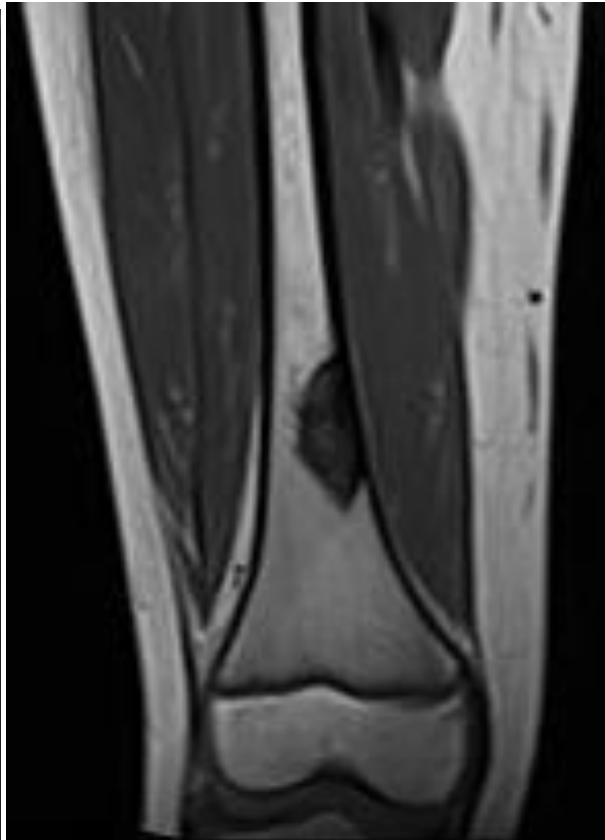
T1 C+



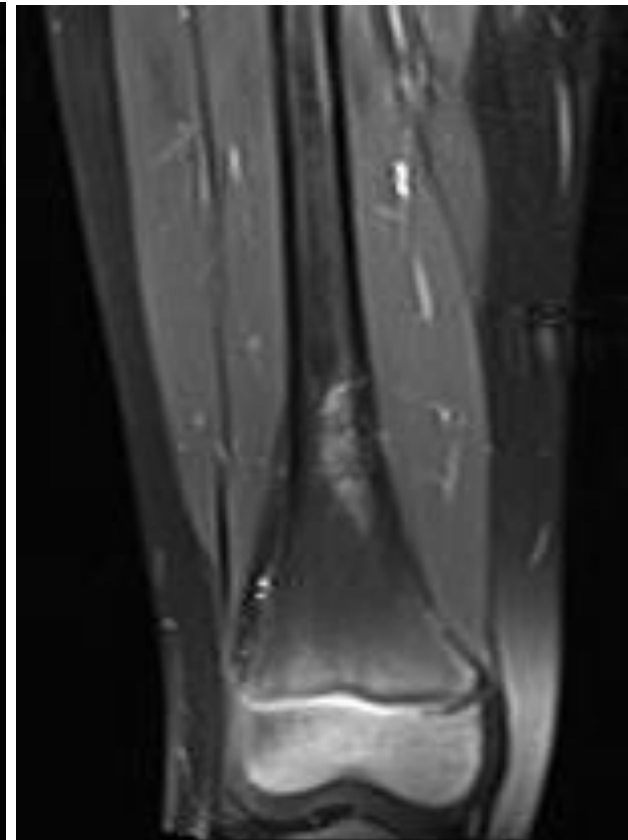
T2



T2 FS



T1



T1 C+

