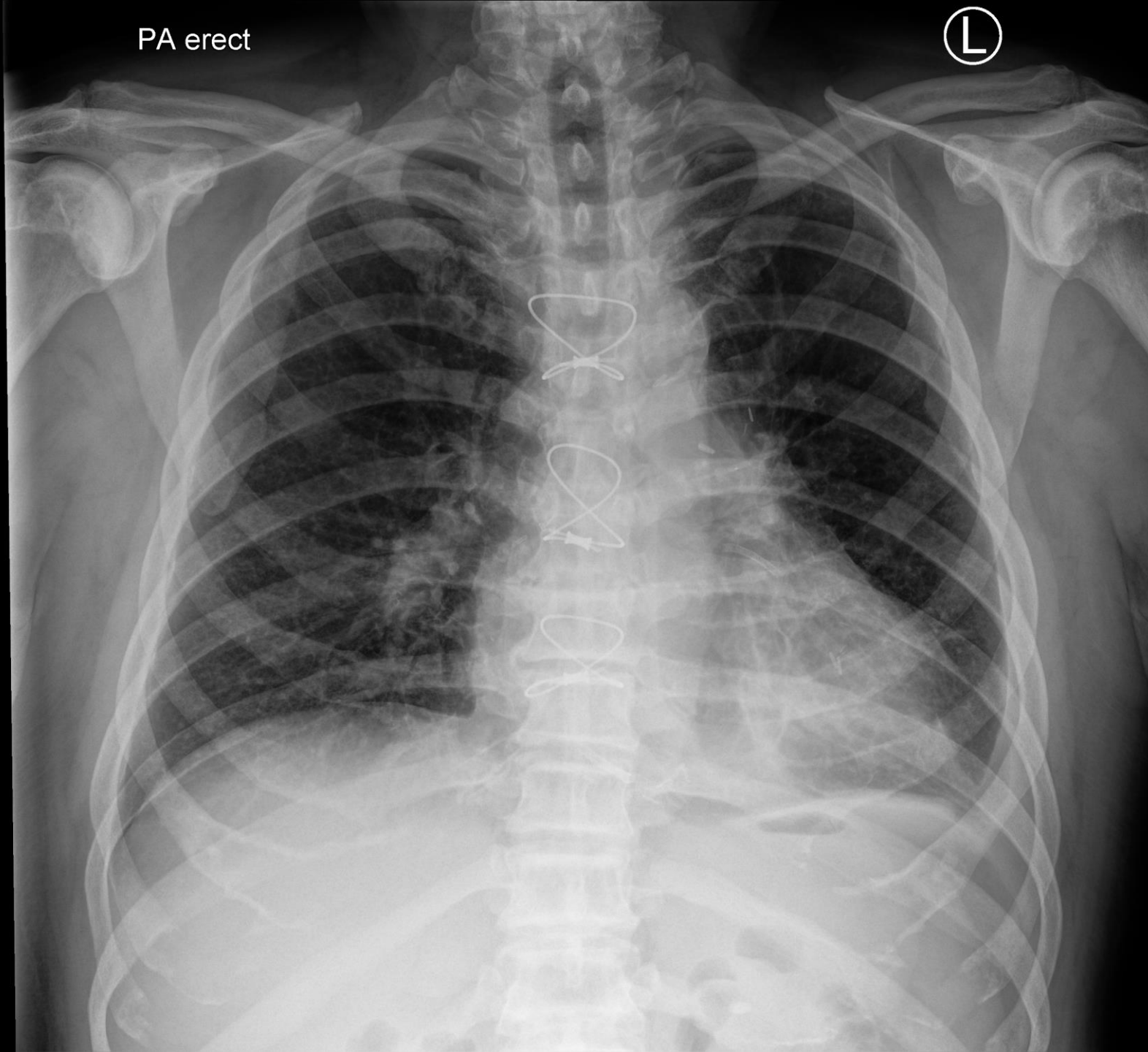
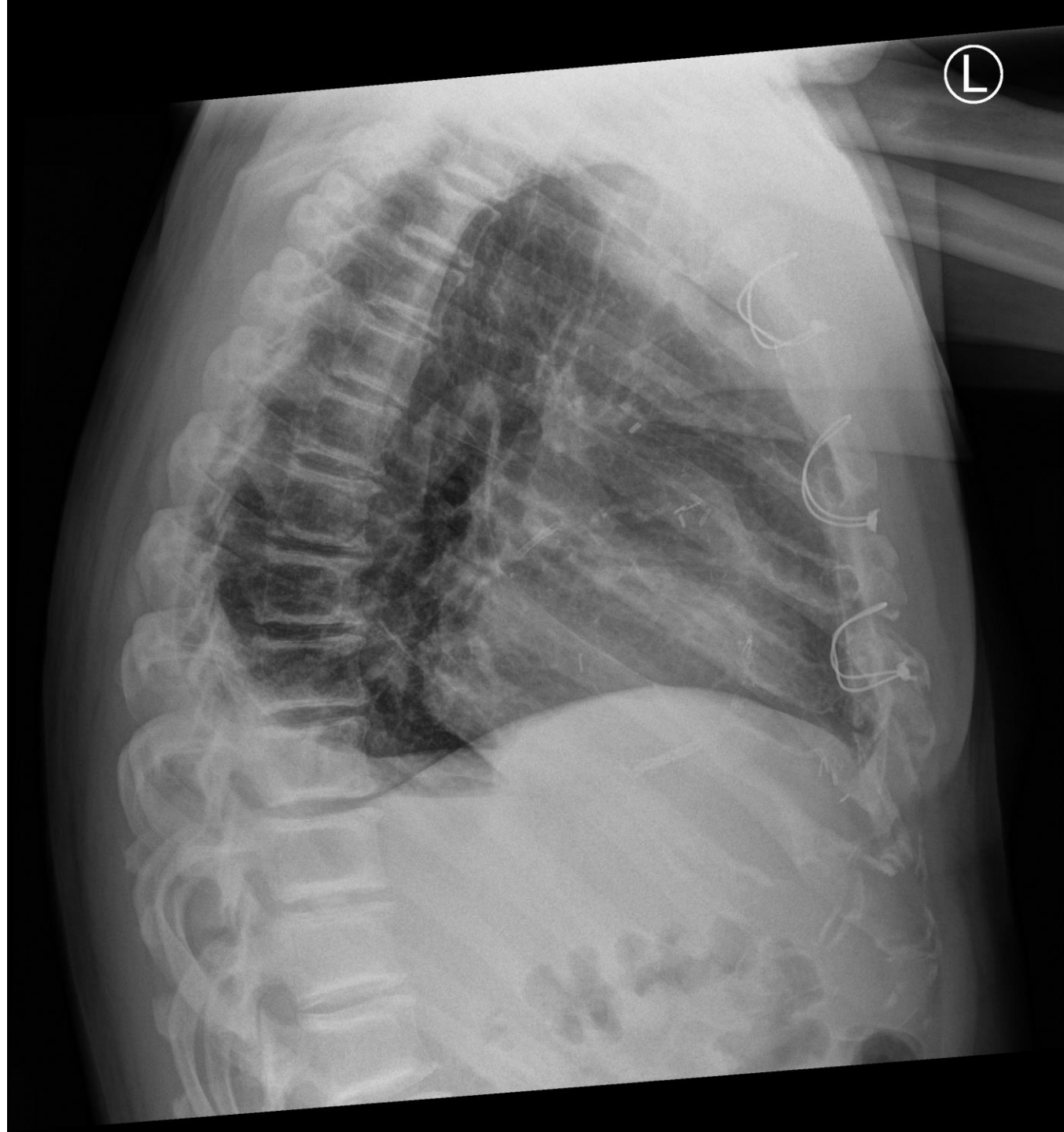

64 year old male check CXR
post CABG

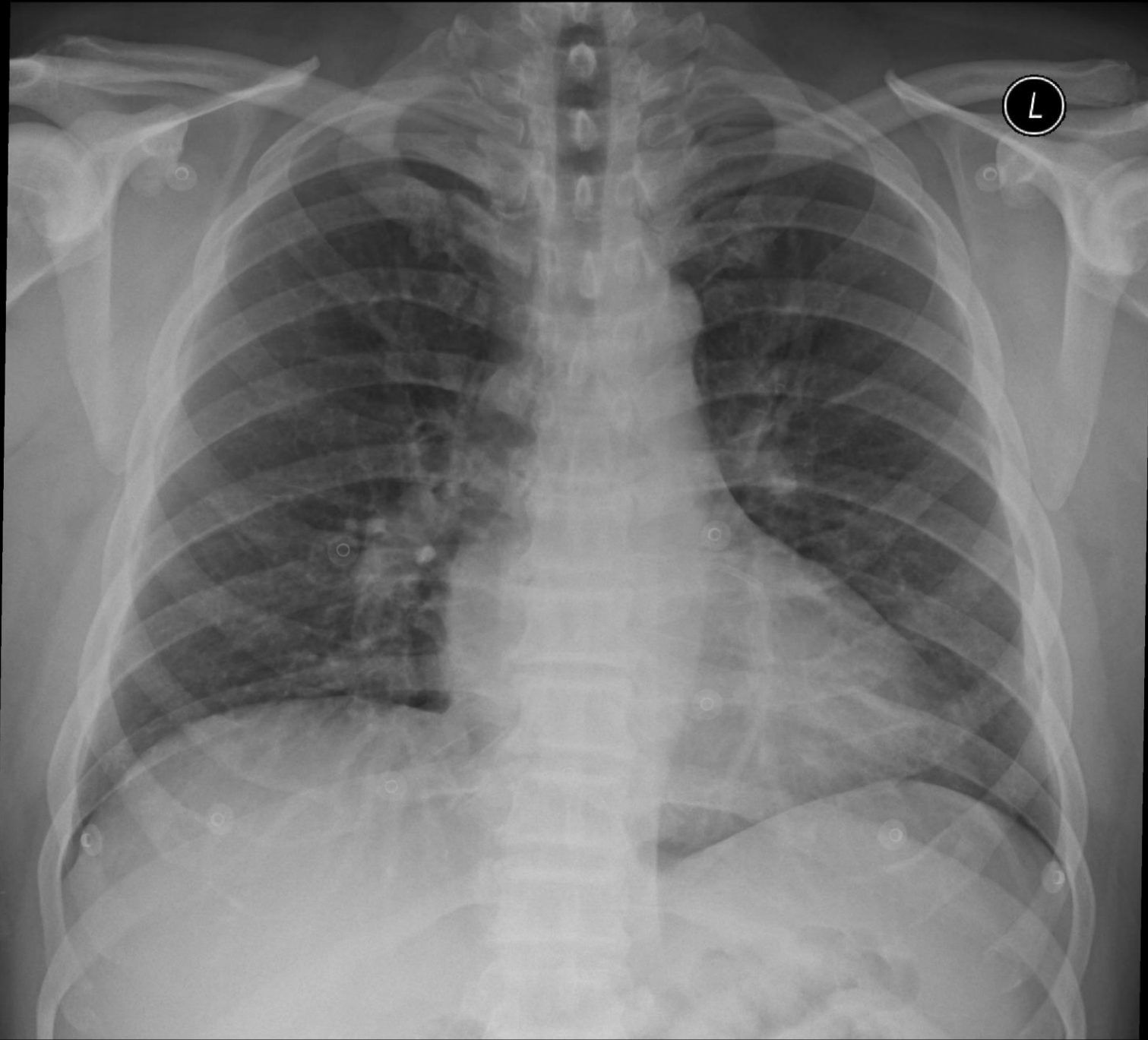
PA erect

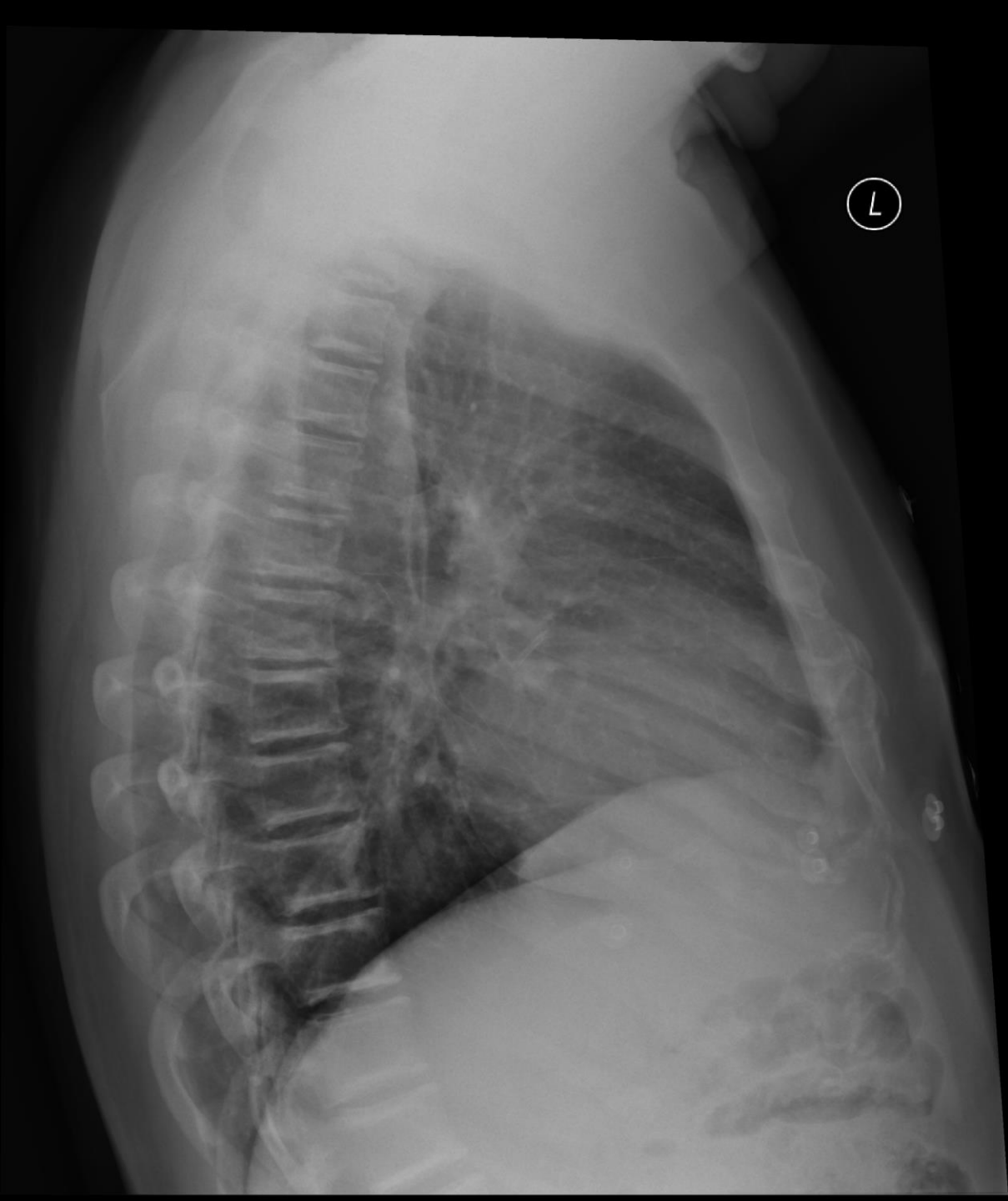
L



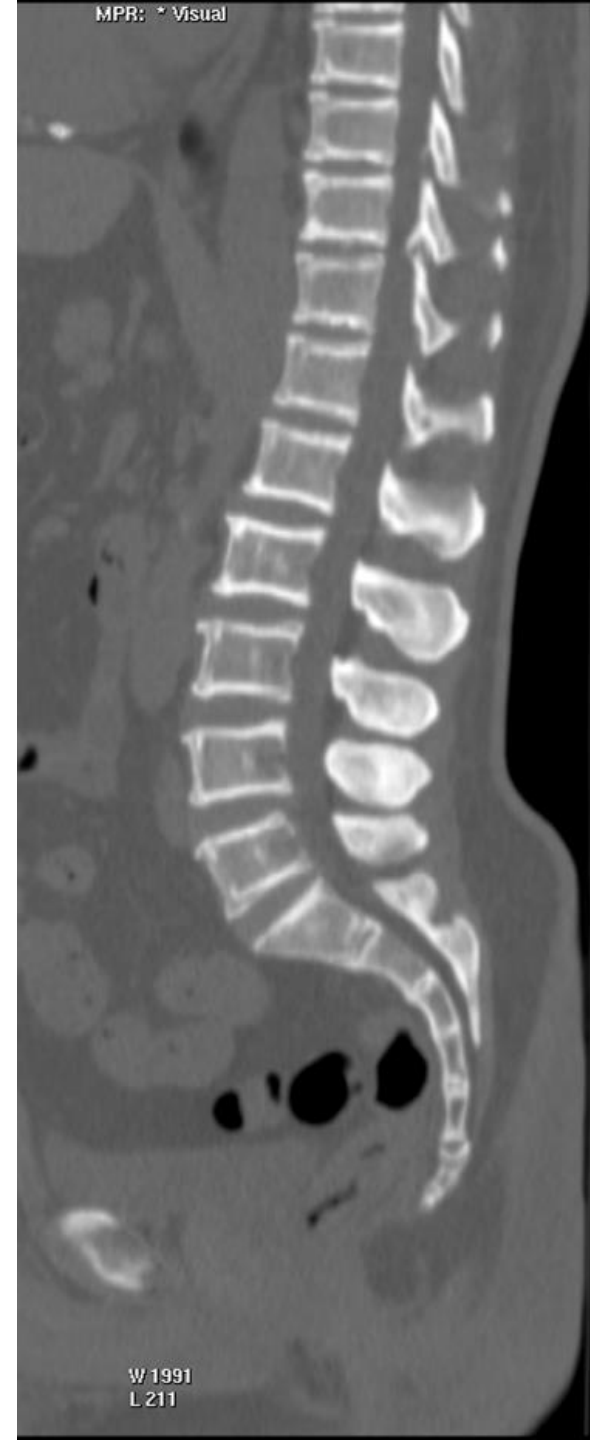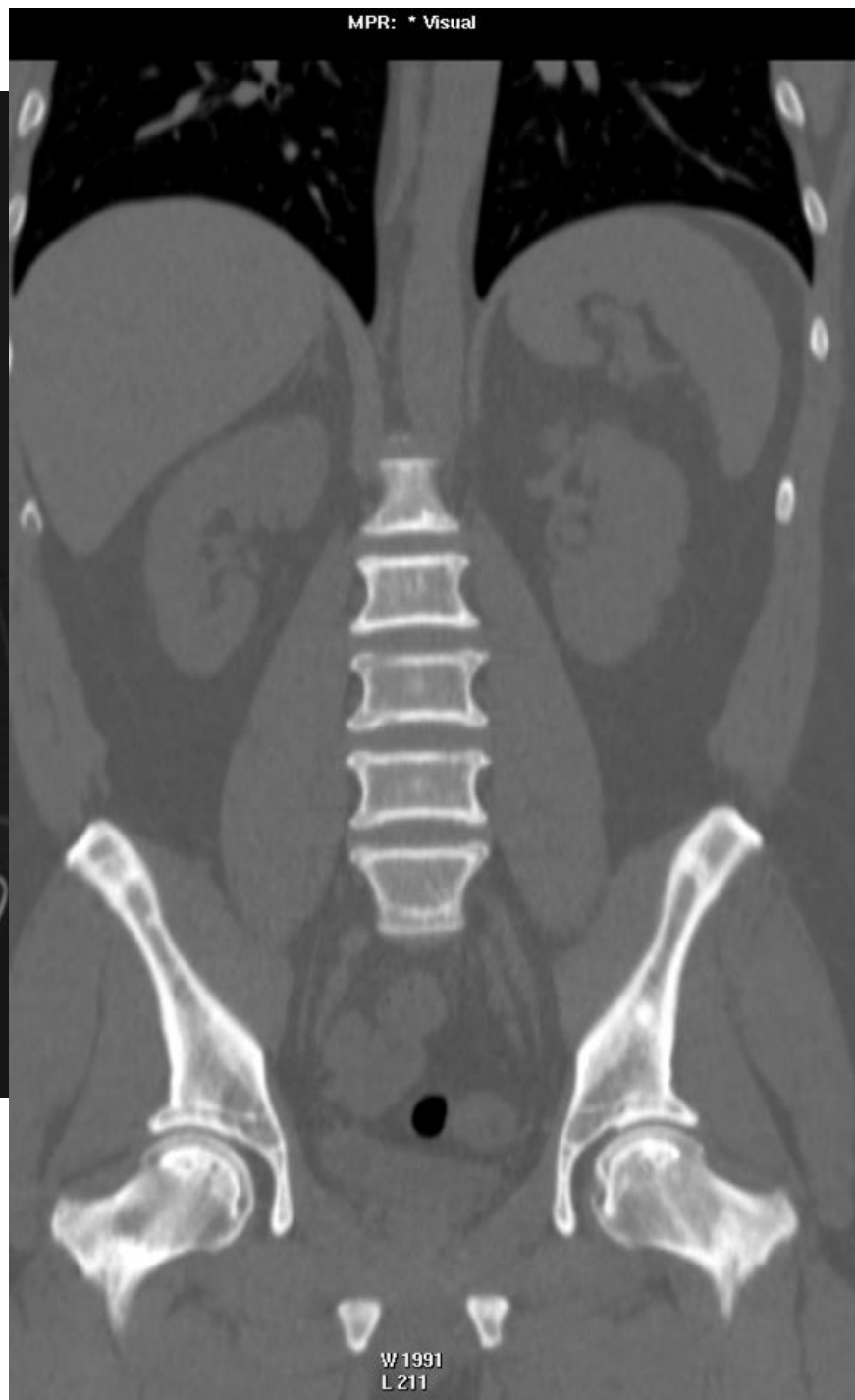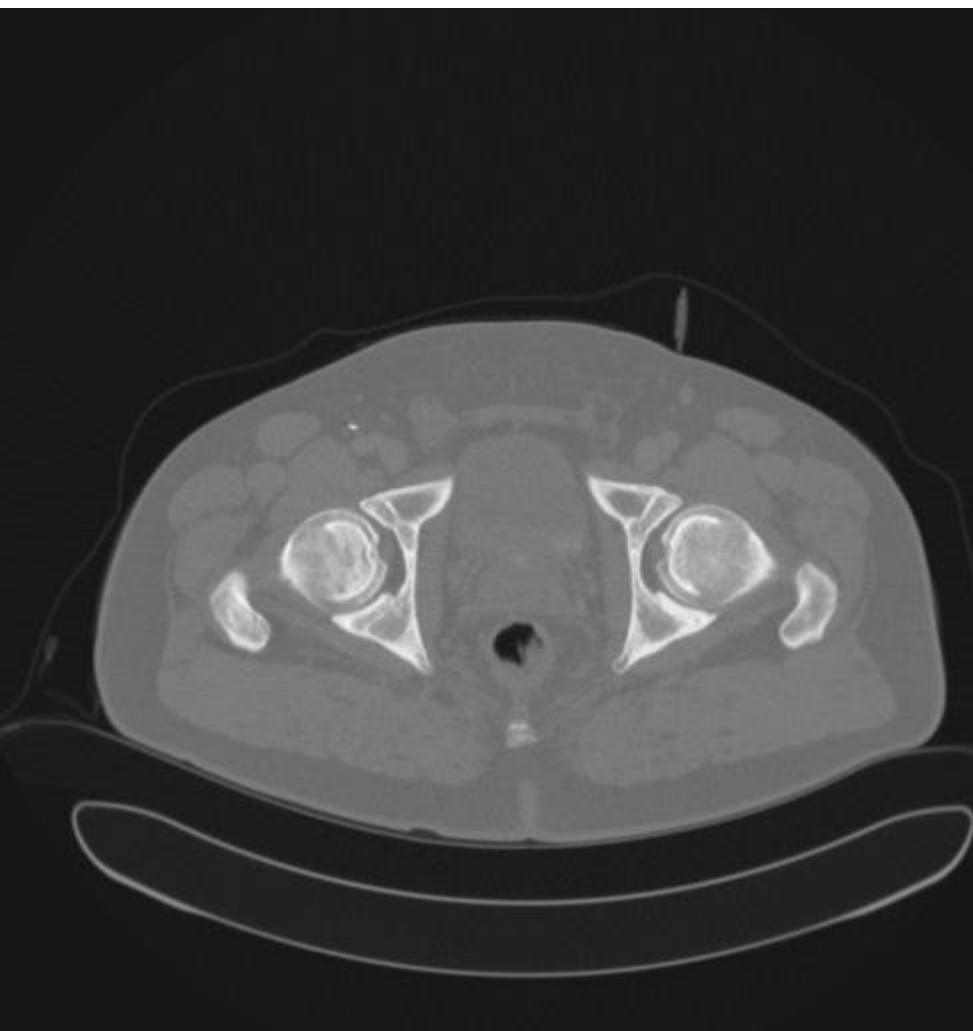


CXR 9 years previously





And abdo CT 10 years ago



I want to call this undiagnosed
adult (autosomal recessive)
osteopetrosis

Anyone disagree?