

12 month boy

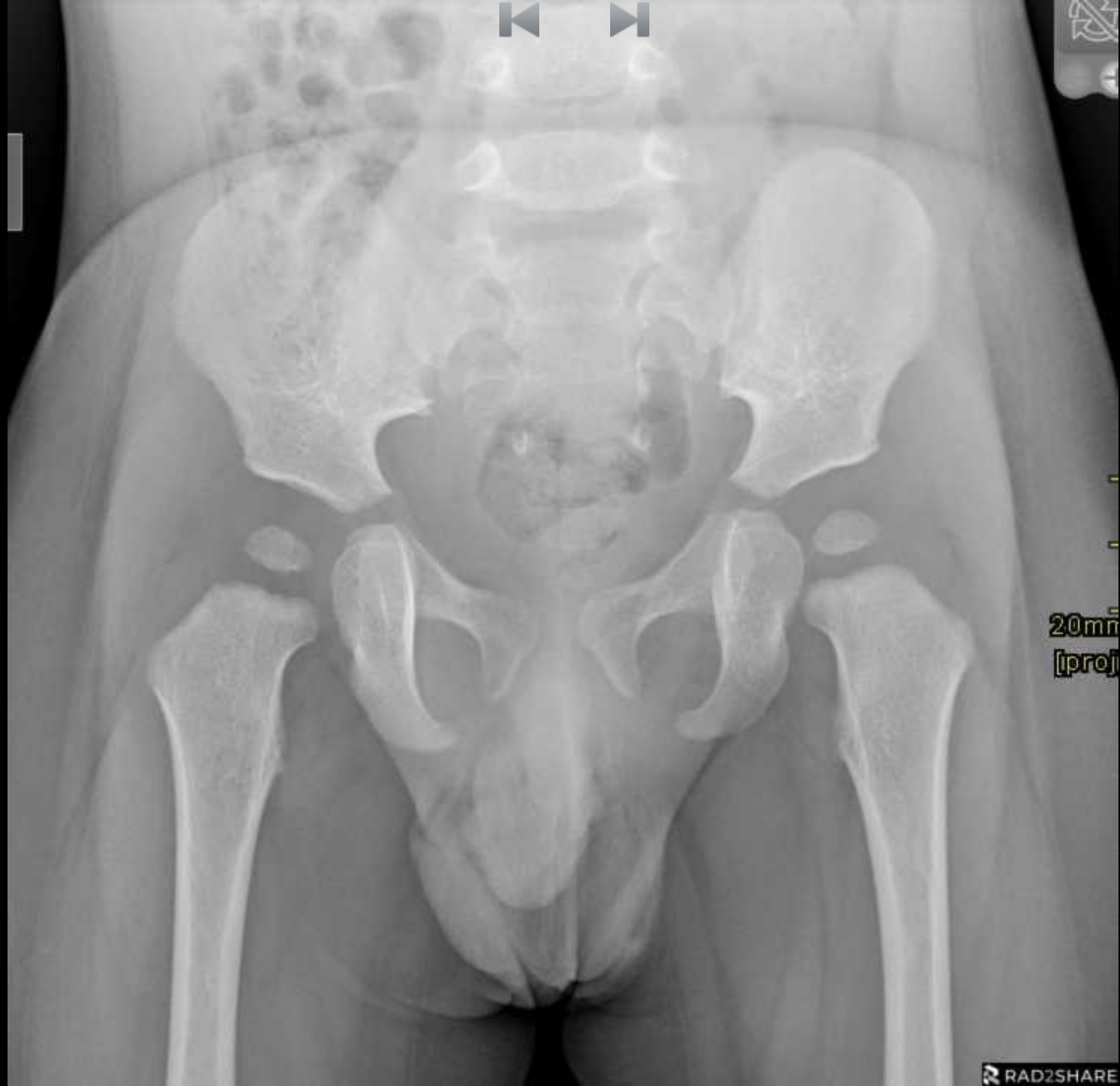Presented acutely with suspected right hip pain 4 days ago and refusing to walk on leg. Recent upper respiratory viral infection, now resolved.

Initial radiograph and ultrasound were suggestive of transient synovitis of the right hip.

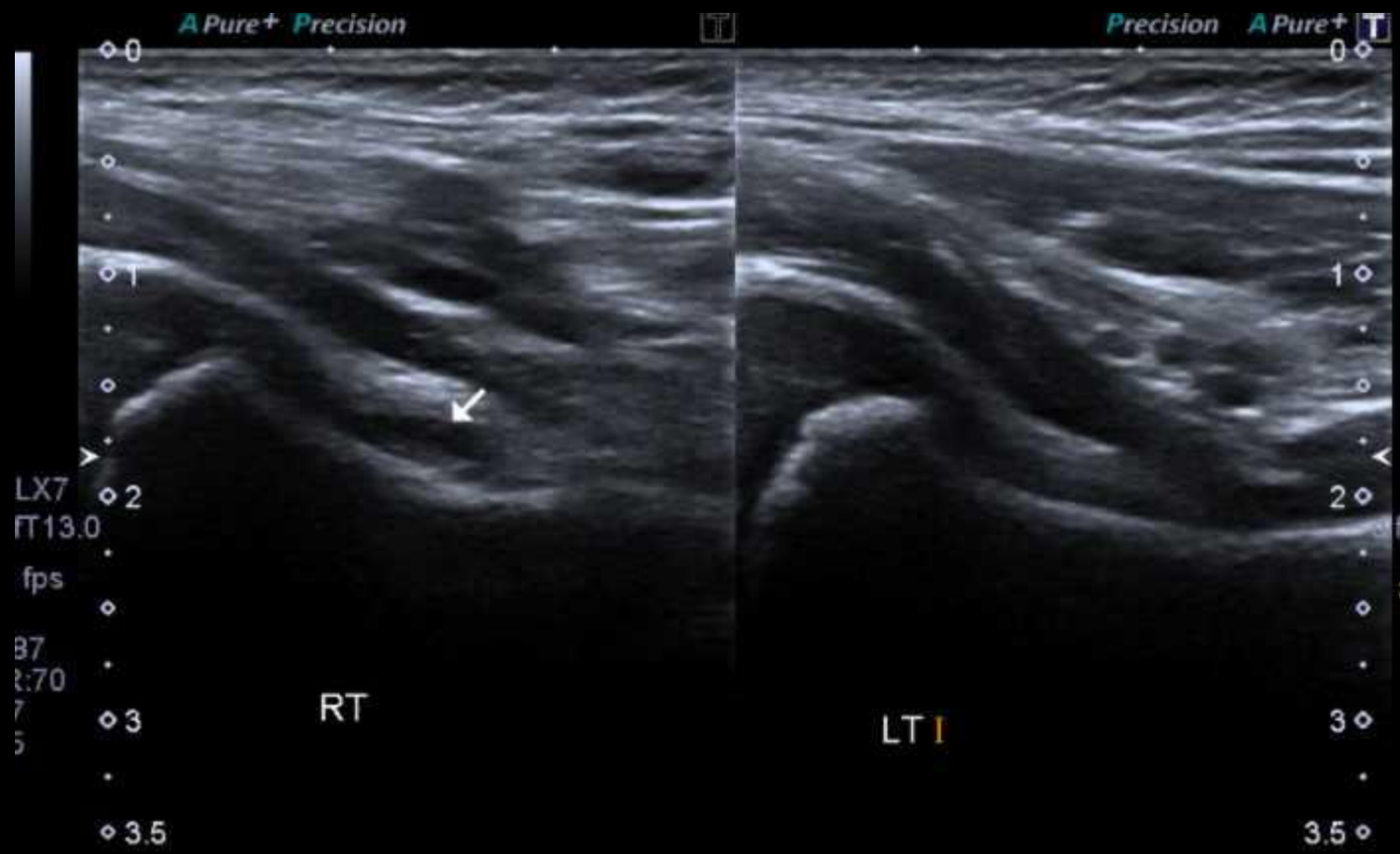

Patient treated conservatively with anti-inflammatories and hip “pain” improved over the next couple of days. At follow up examination the paediatrician noticed poor/absent reflexes in the right leg and the child was still reluctant to bear weight on the right leg.

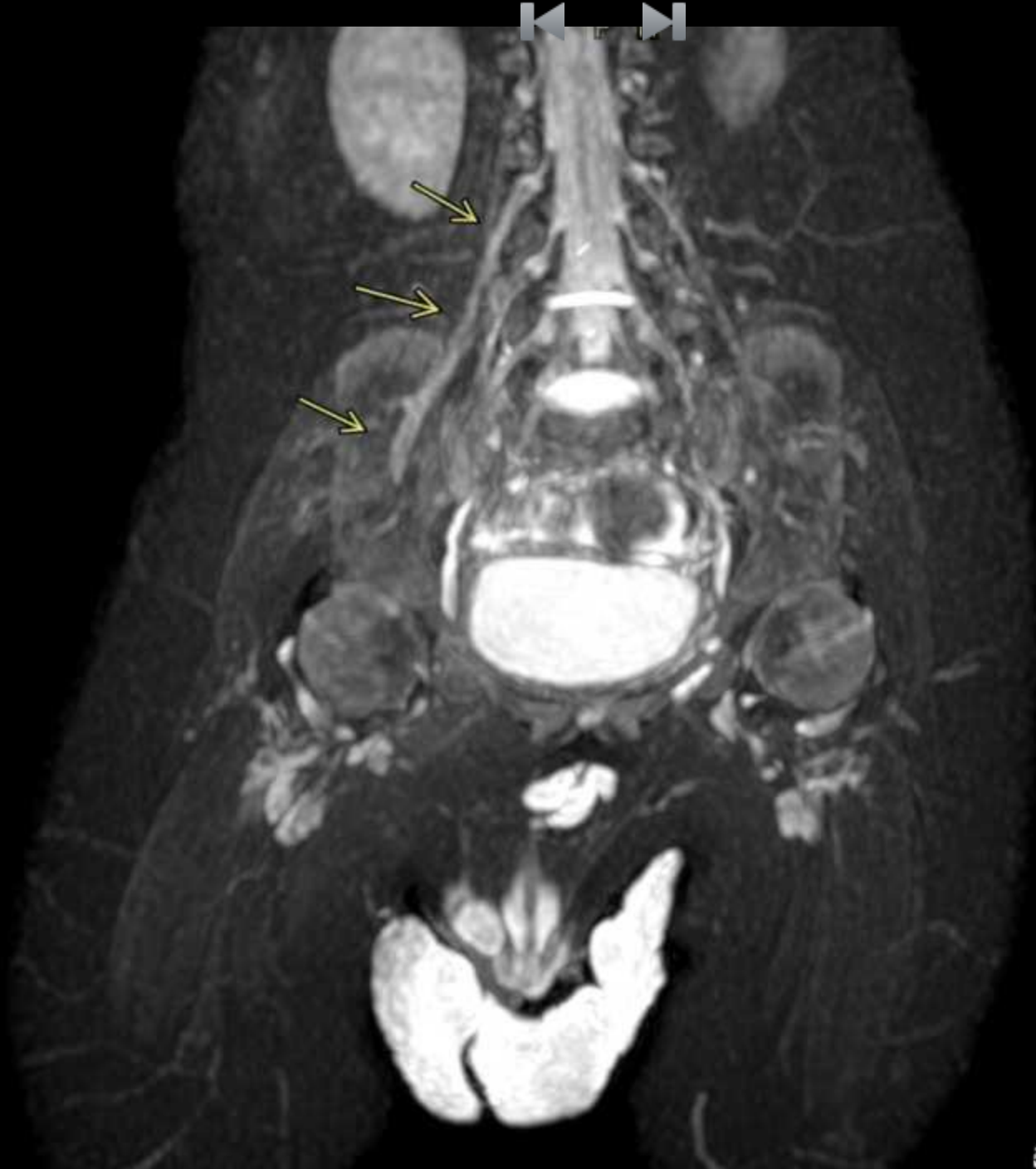MRI shows no sign of hip effusion (or other hip abnormality) but does show thickened high signal intensity lumbosacral plexus bilaterally with asymmetry of the right femoral and sciatic nerves.

Is this post inflammatory/infectious? Suggested lumbar puncture
Any other suggested investigations? White cells/CRP are normal.

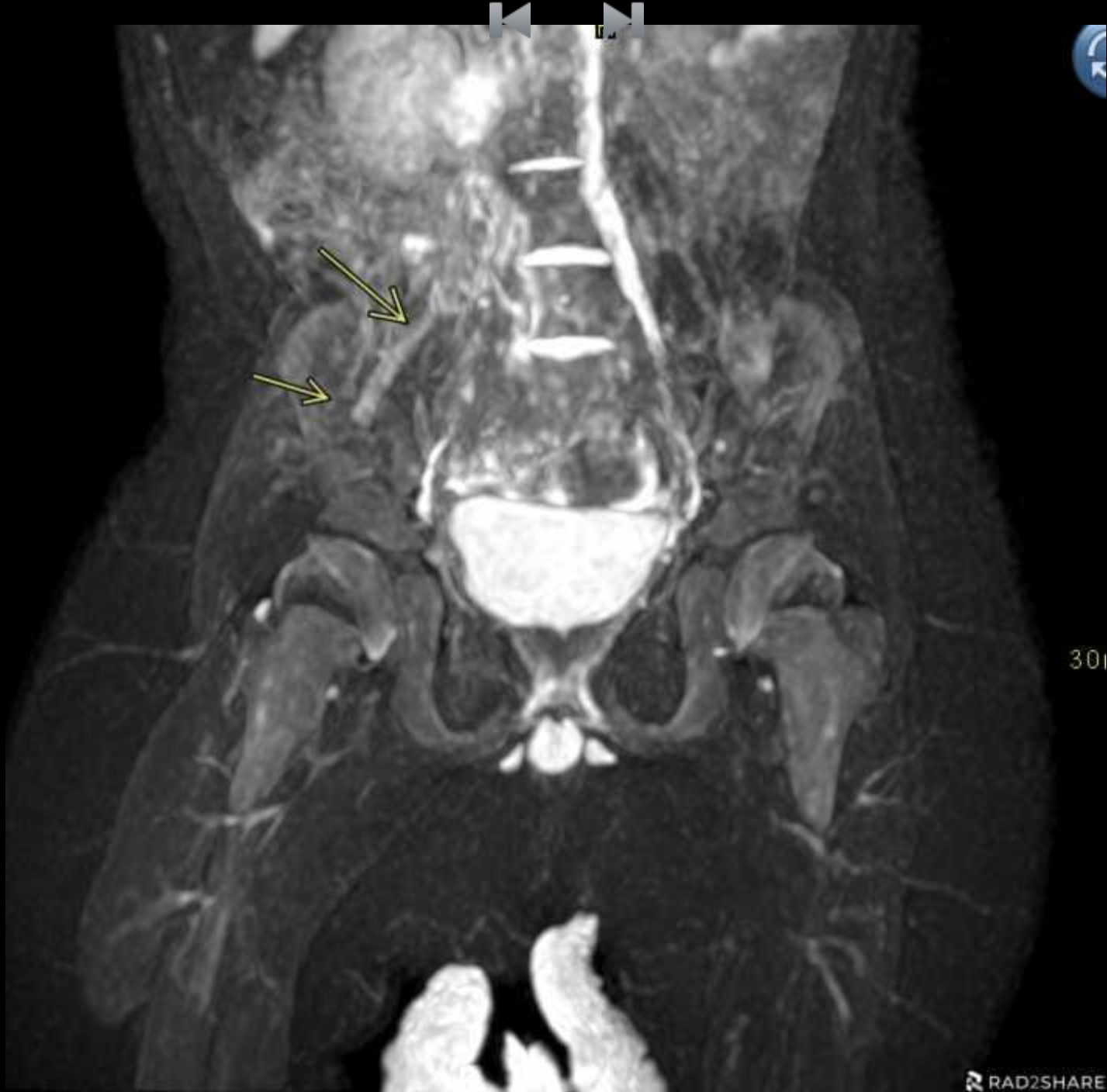

20mm
[proj]

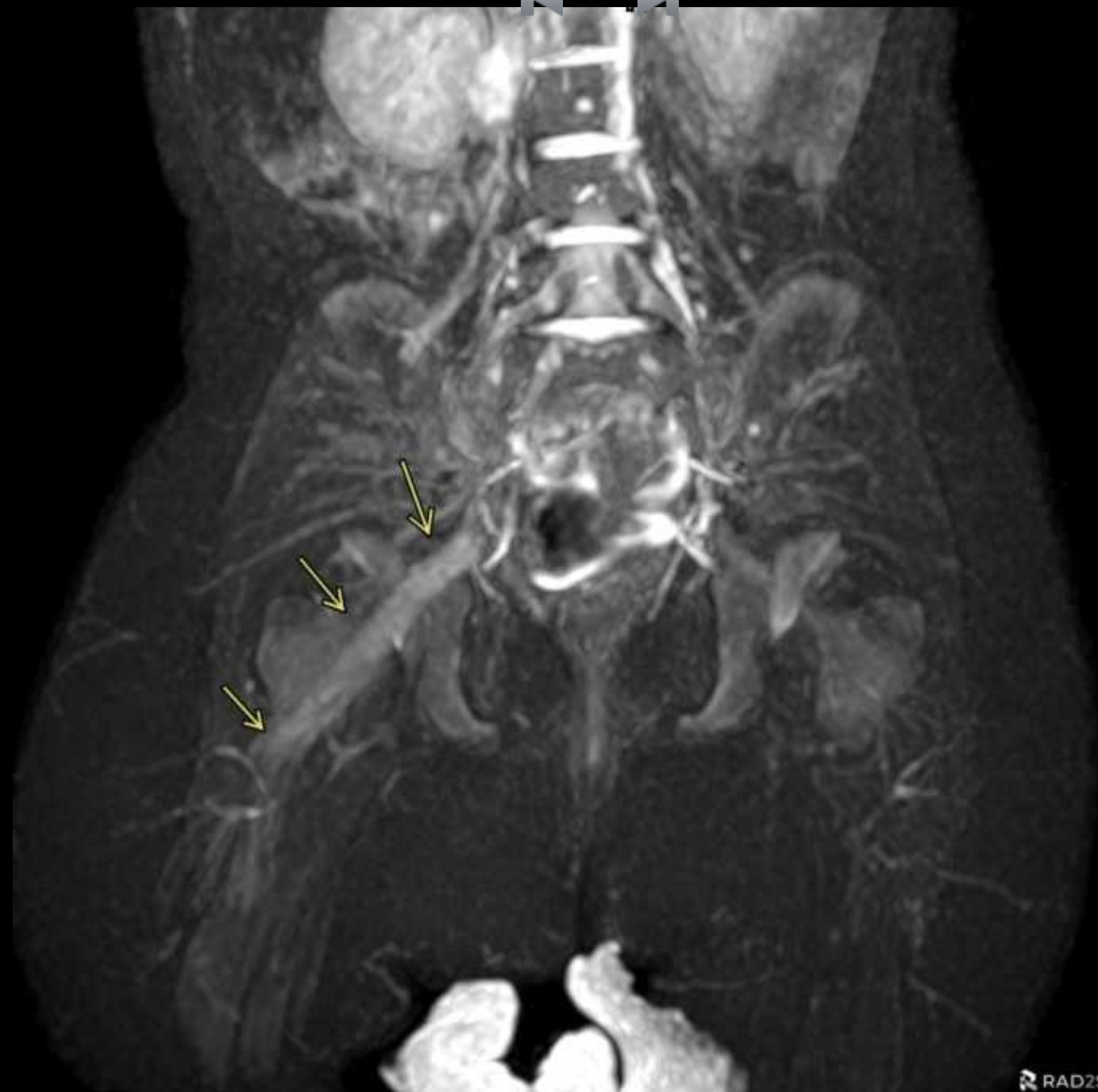



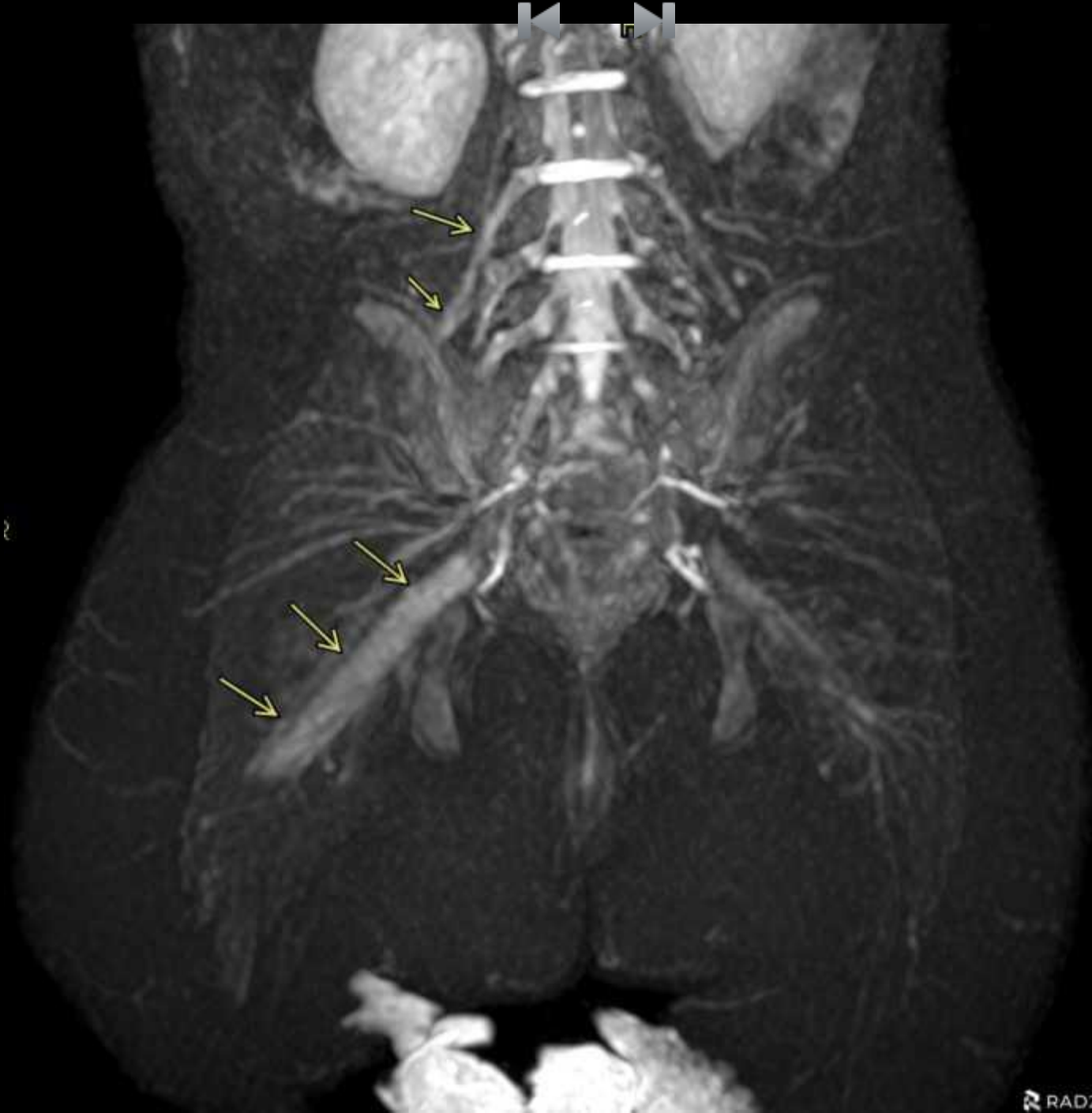301



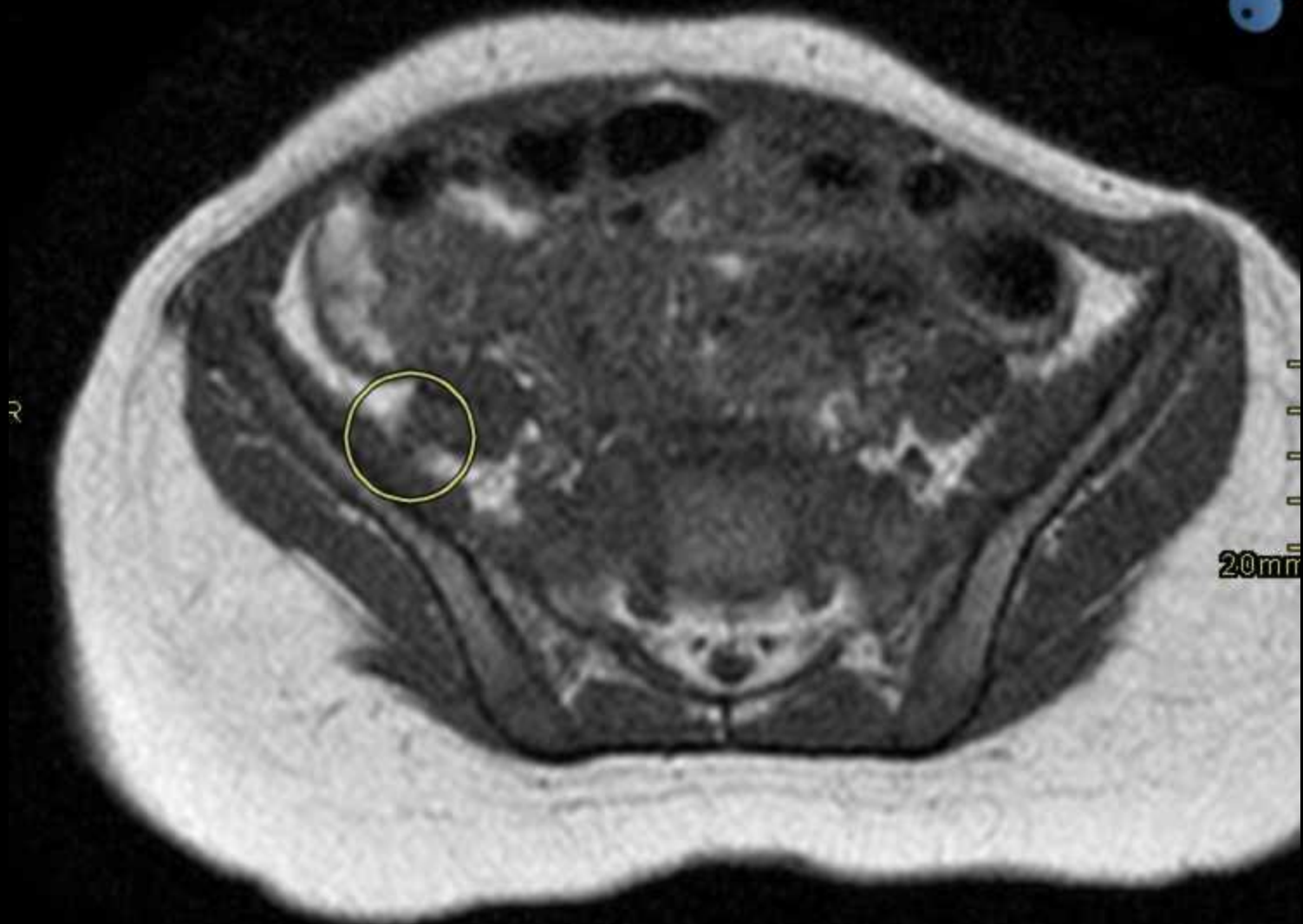

301



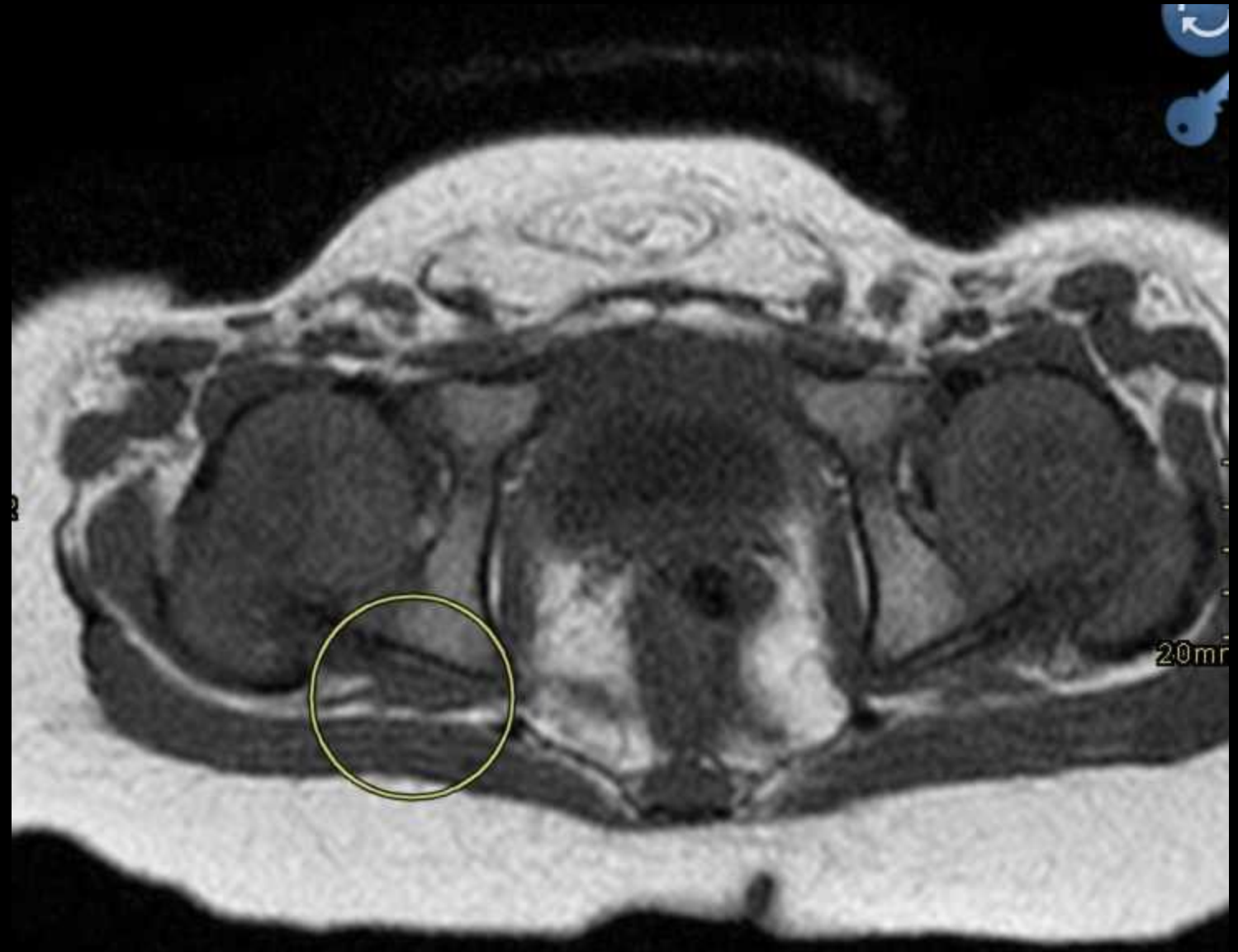
30r



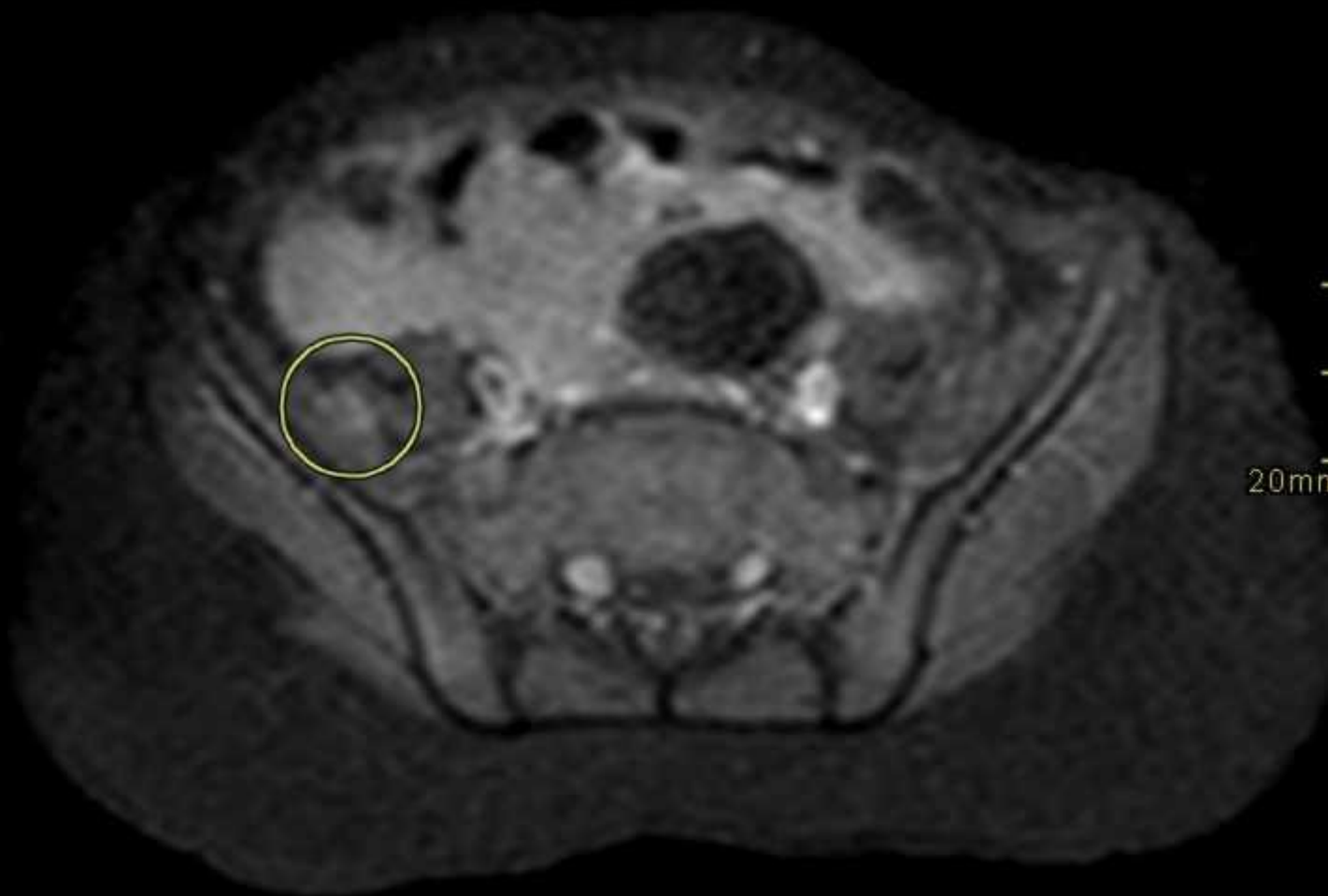

30mi



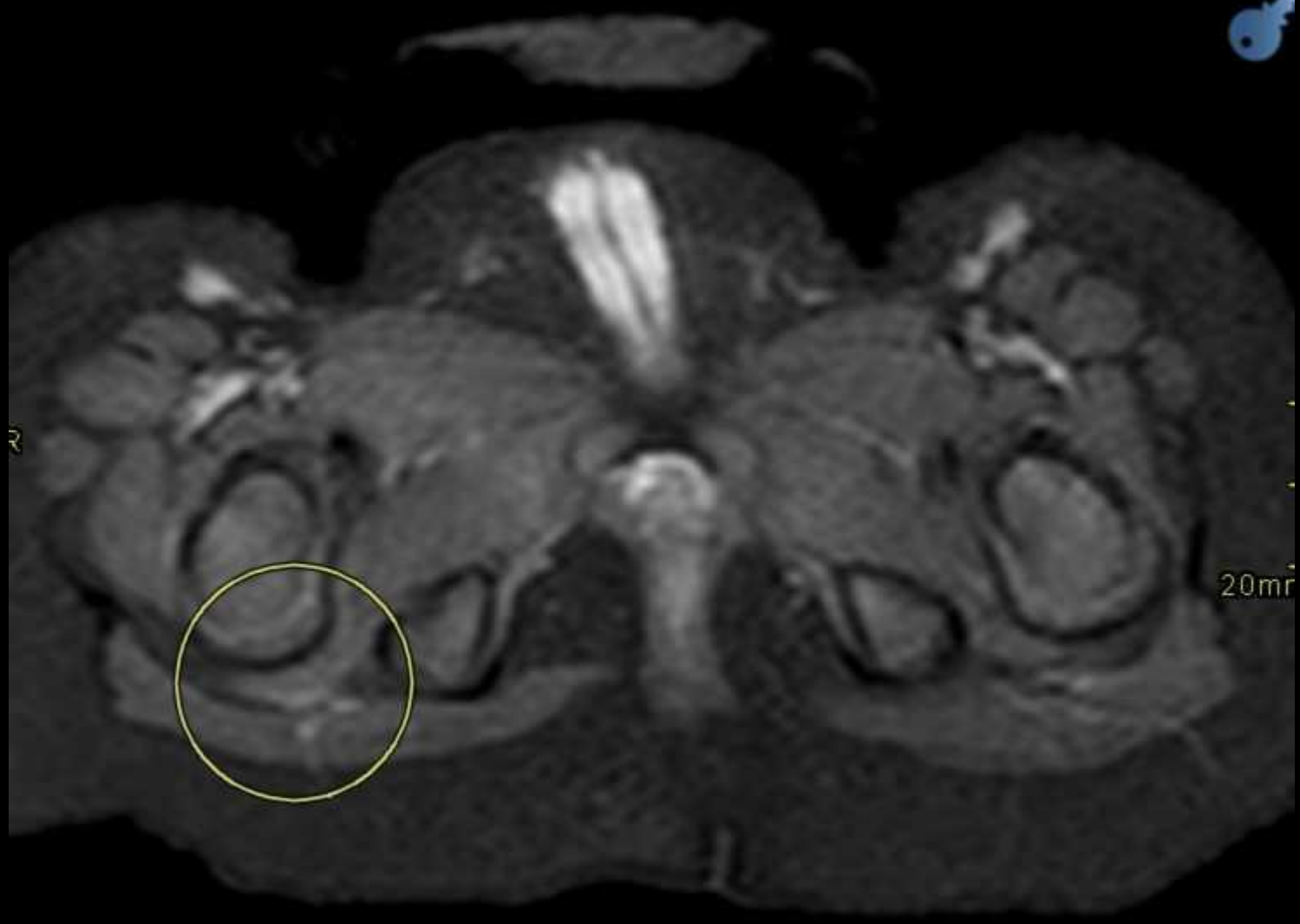20mm



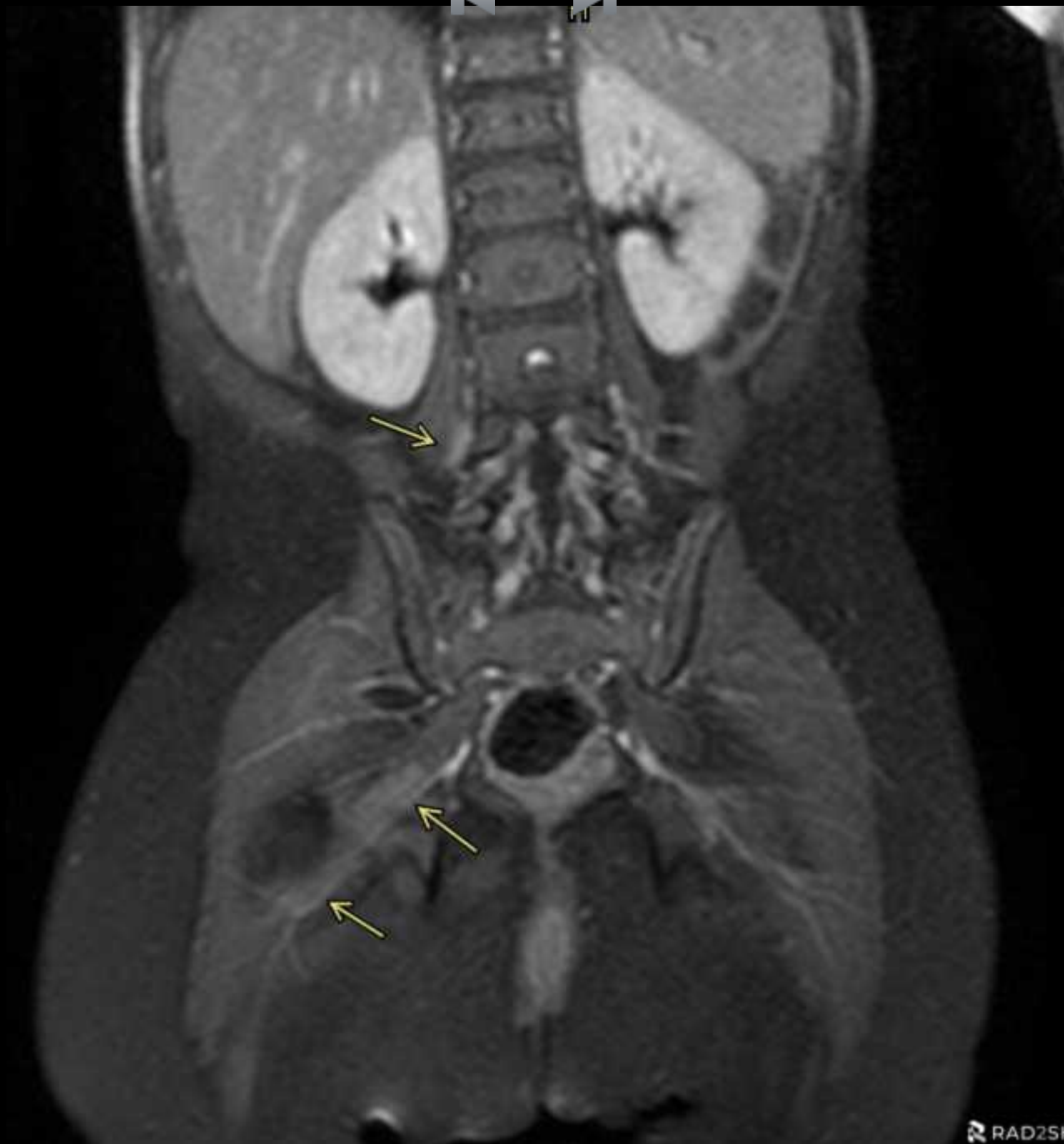20mm



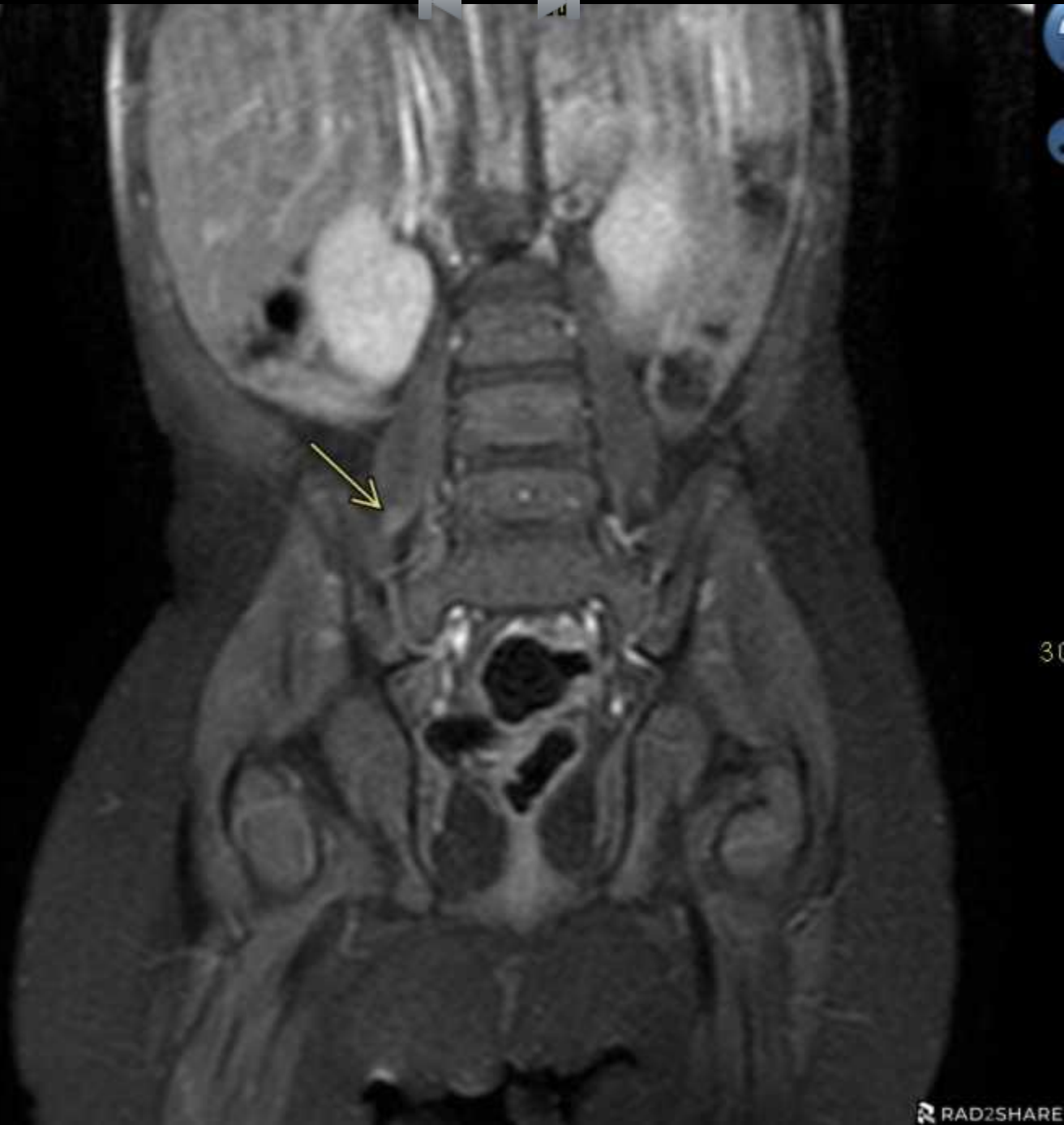20mm



20mr



30r



R

30