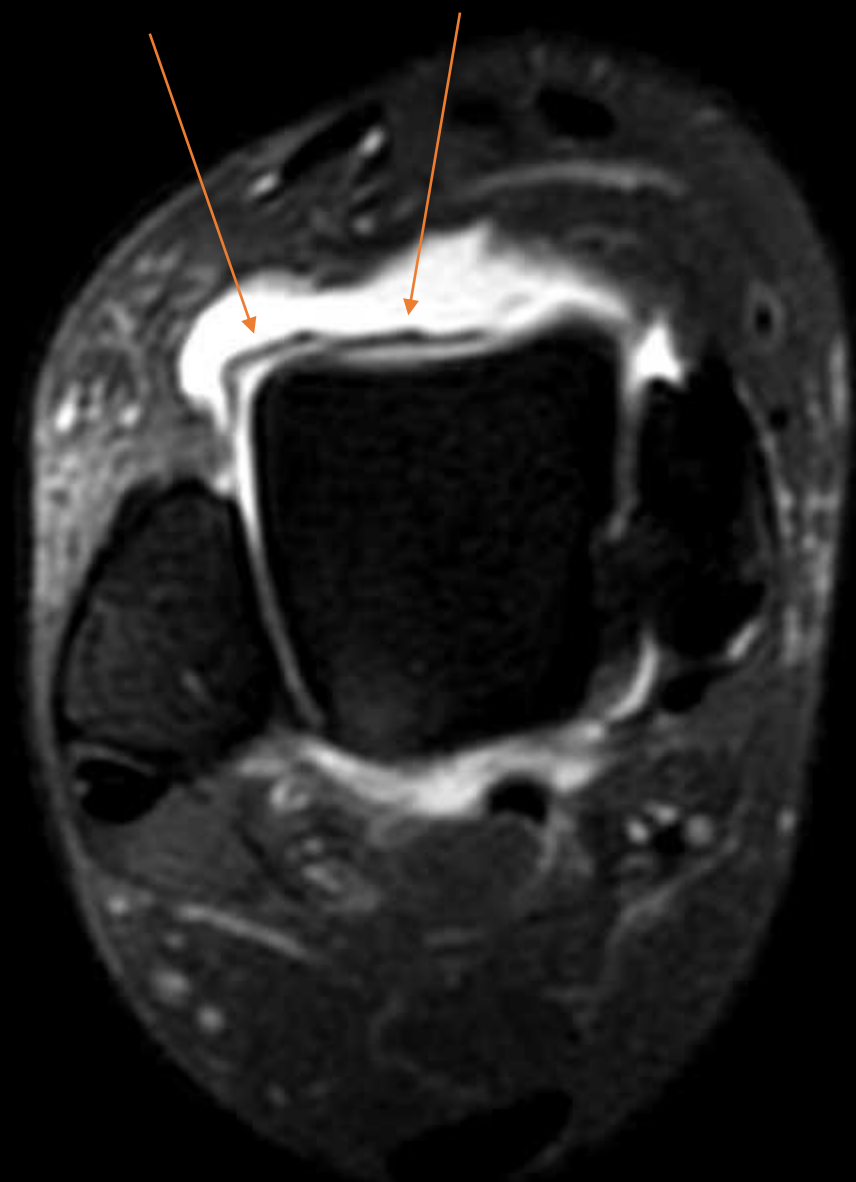


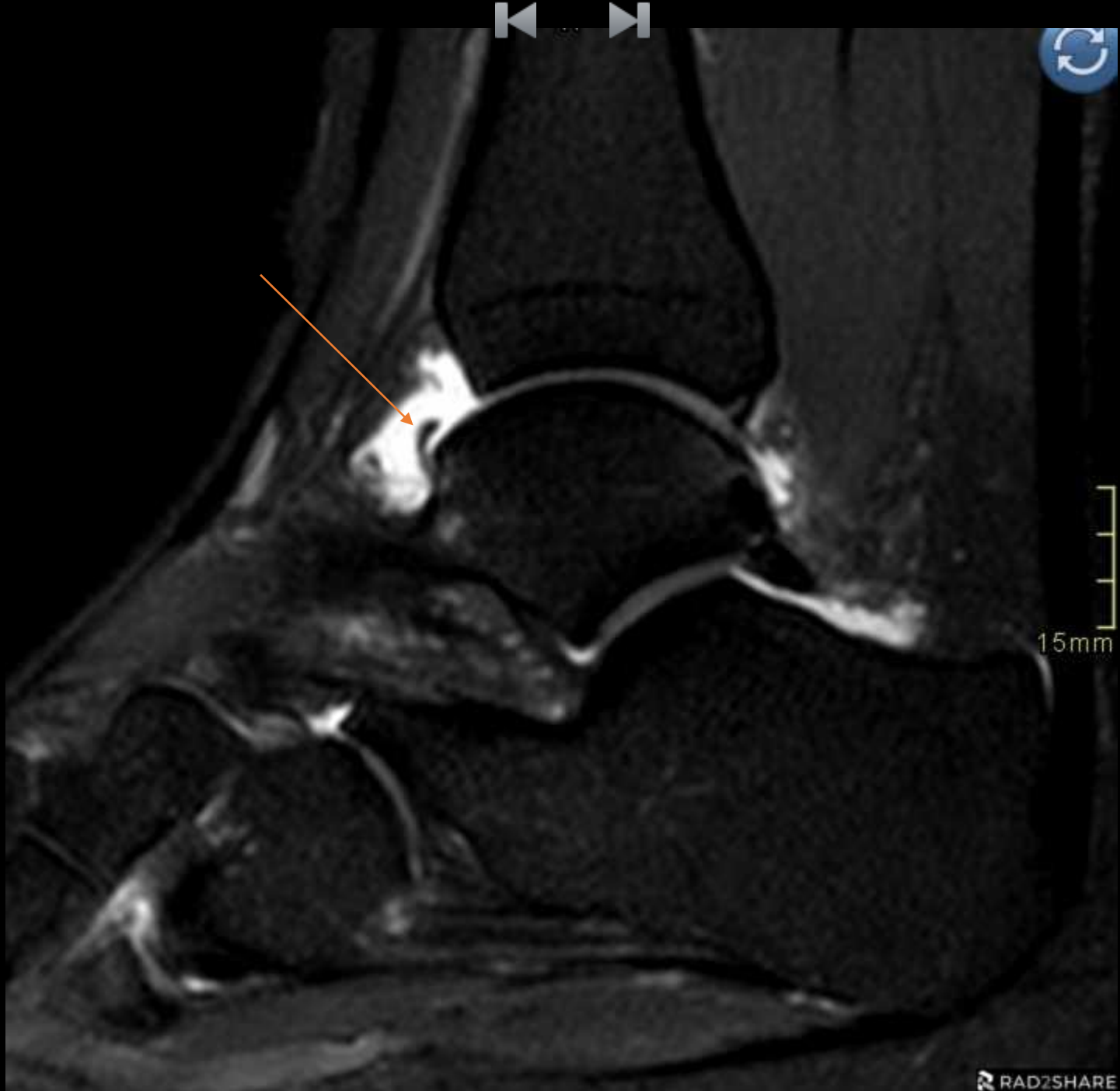
33 Yr lady twisting injury of ankle

Syndesmosis injury (not shown)

Is this structure traversing the anterior ankle joint
a large synovial plica?



15m



15mm

