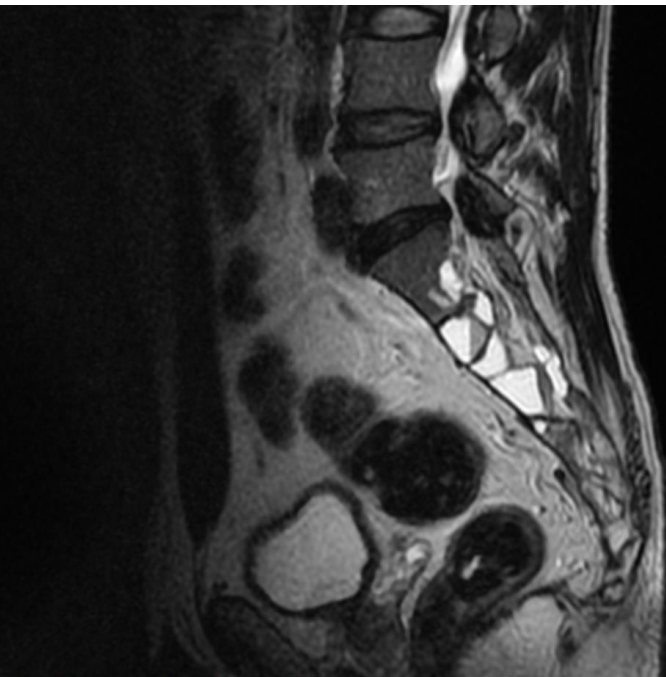
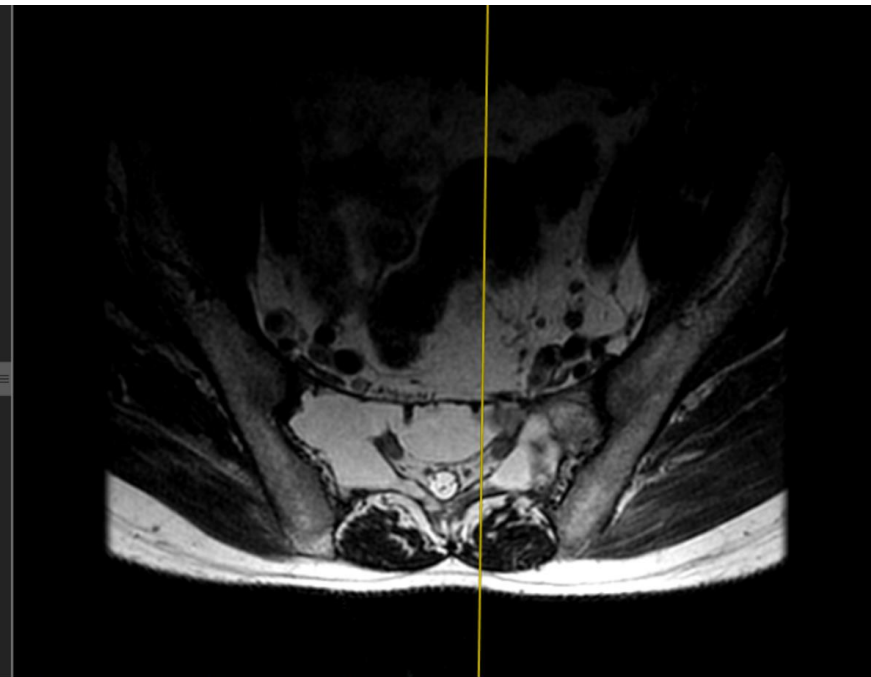


45y old, male

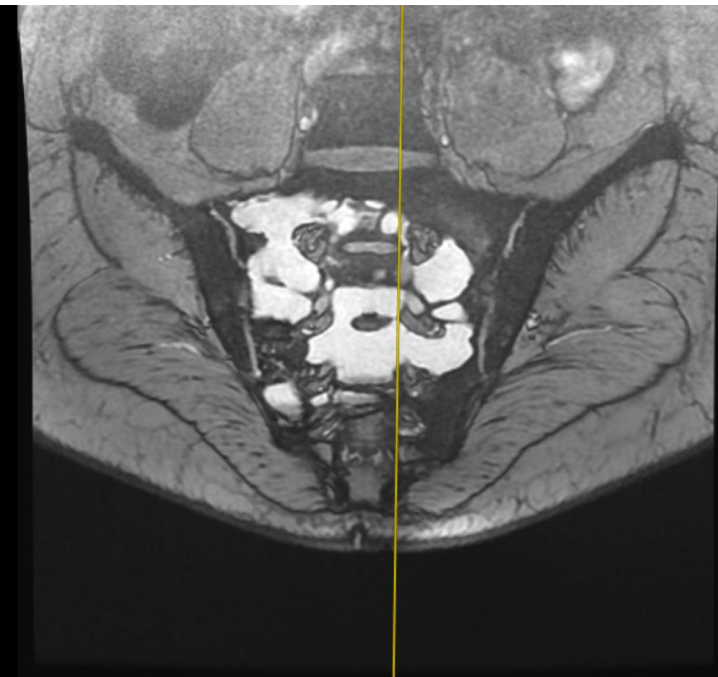
- Low back pain
- MRI lumbar spine 2007 nothing remarkable
- New MRI this year
- Aneurysmal bone cyst in my opinion
- Did a CT for extra data



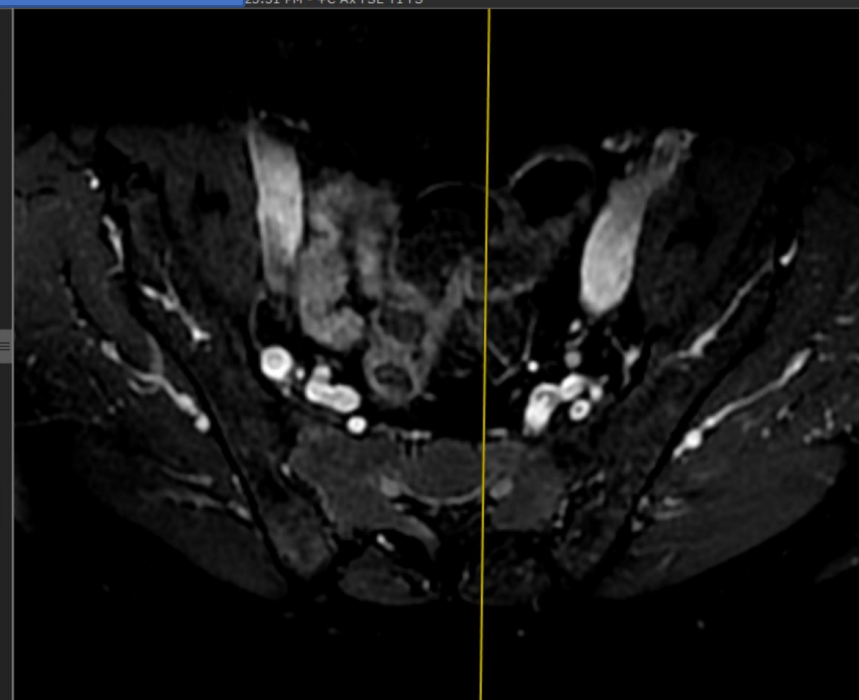
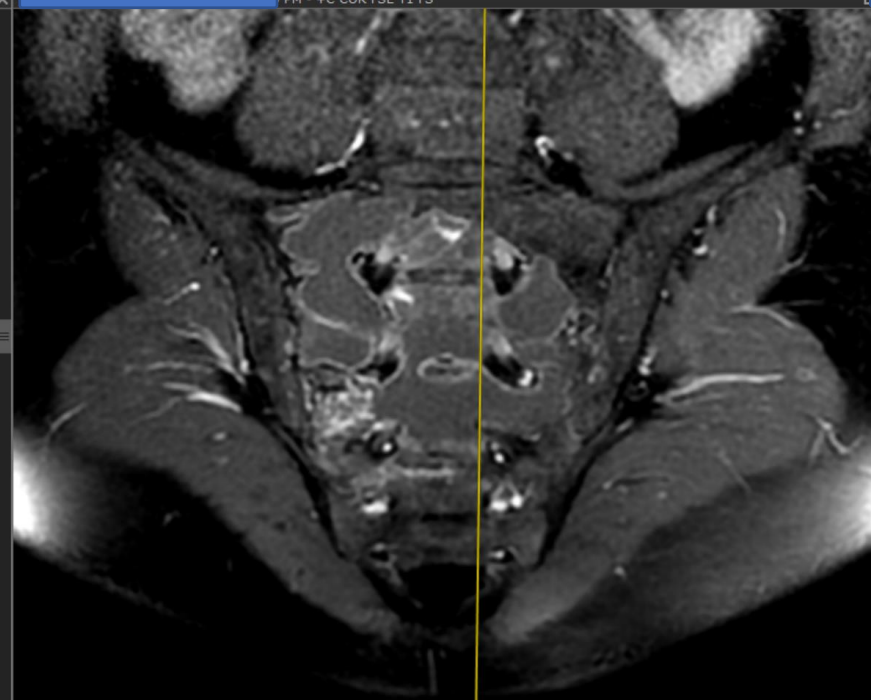
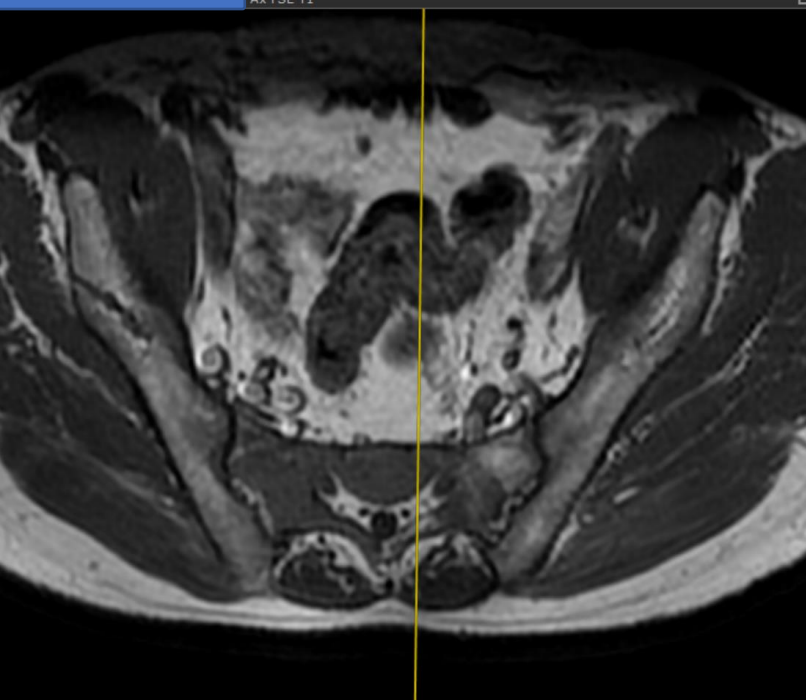
Ax FSE T1

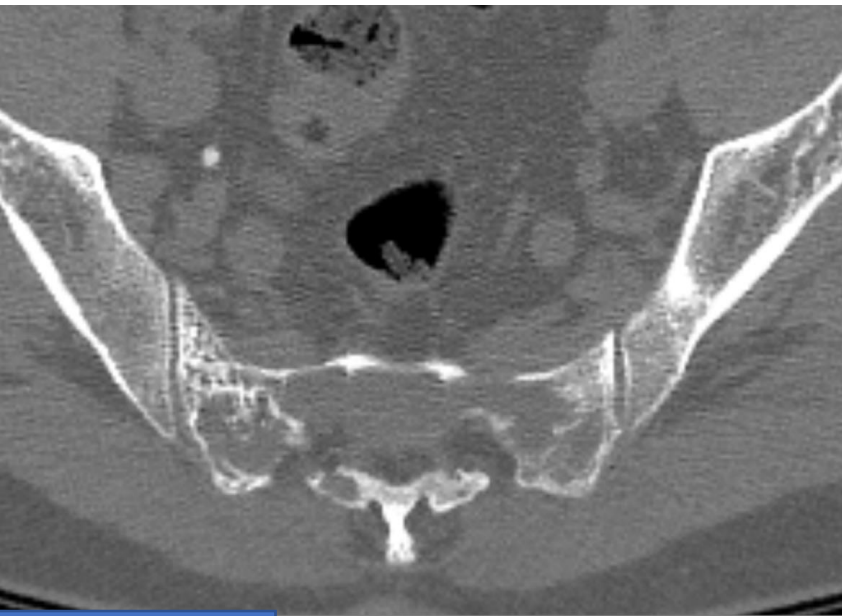


PM - +C COR FSE T1 FS

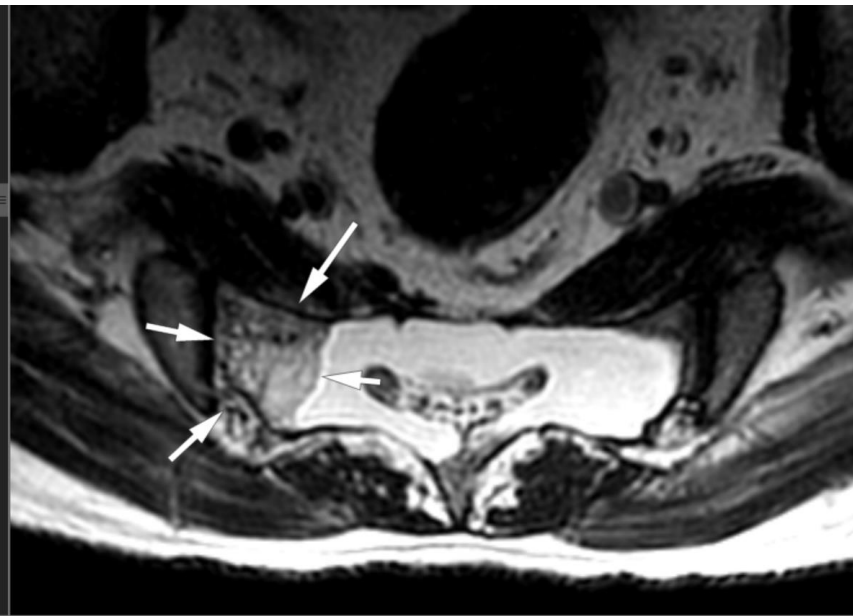


23:31 PM - +C Ax FSE T1 FS

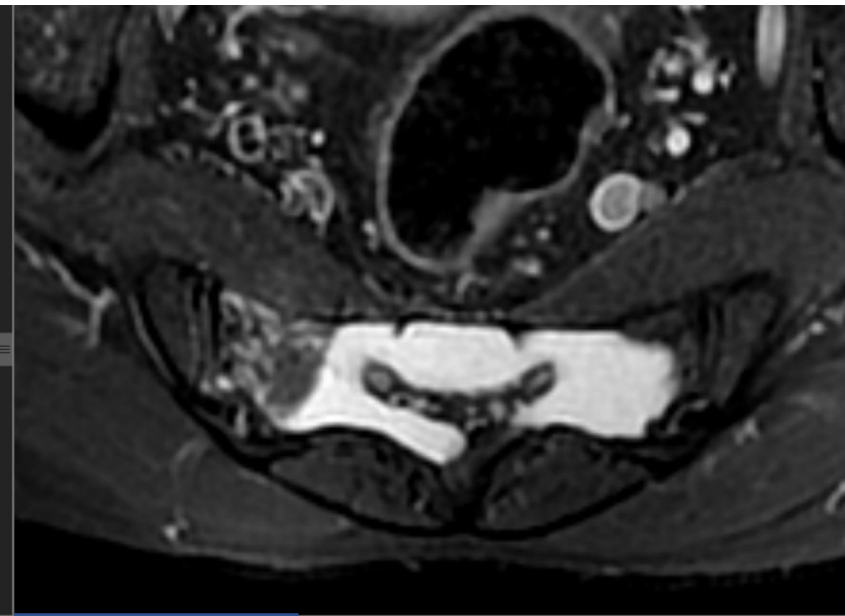




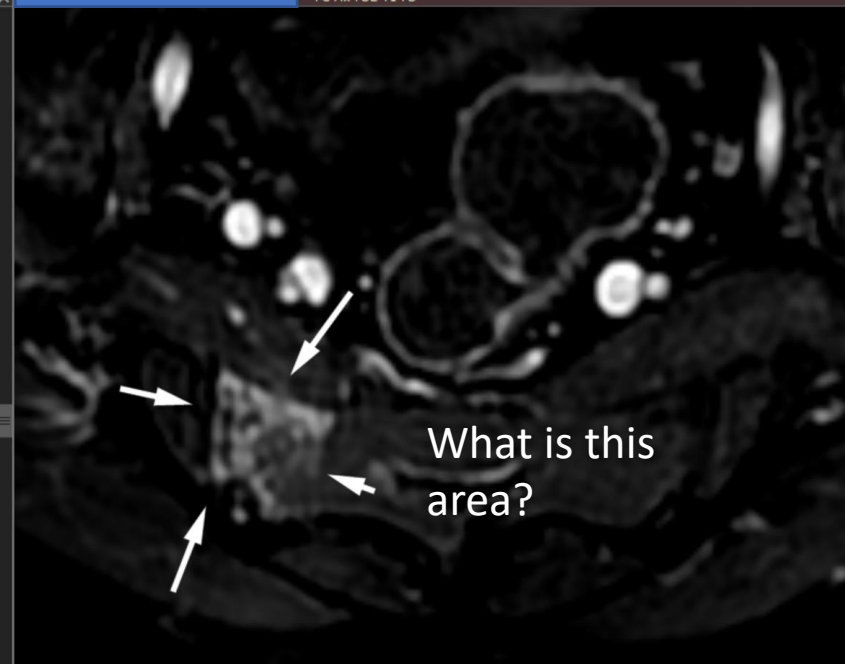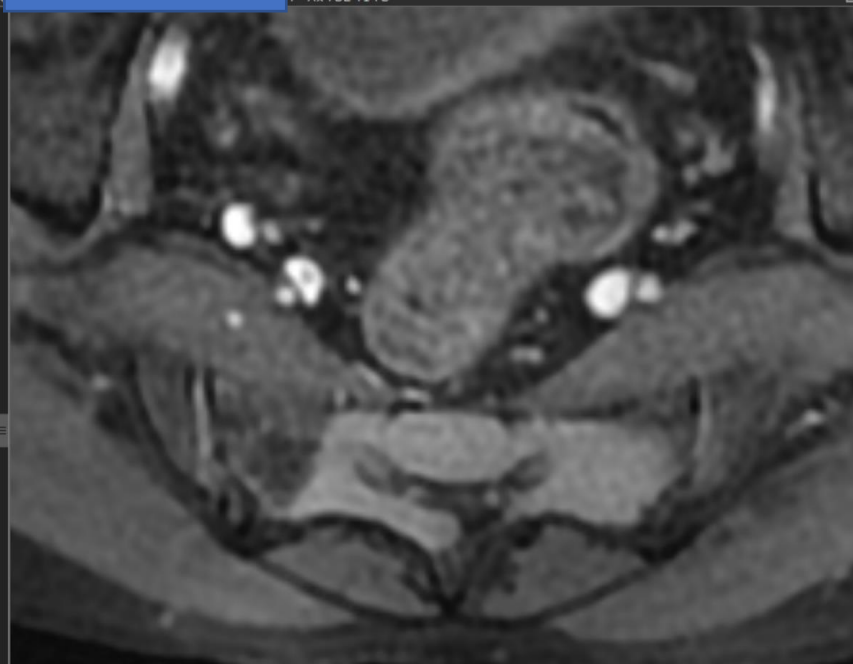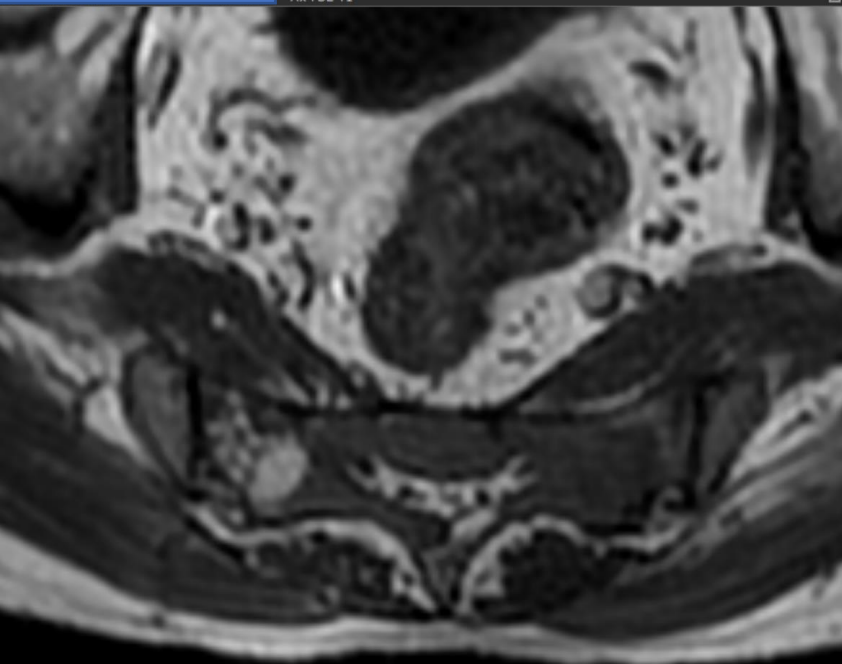
- Ax FSE T1



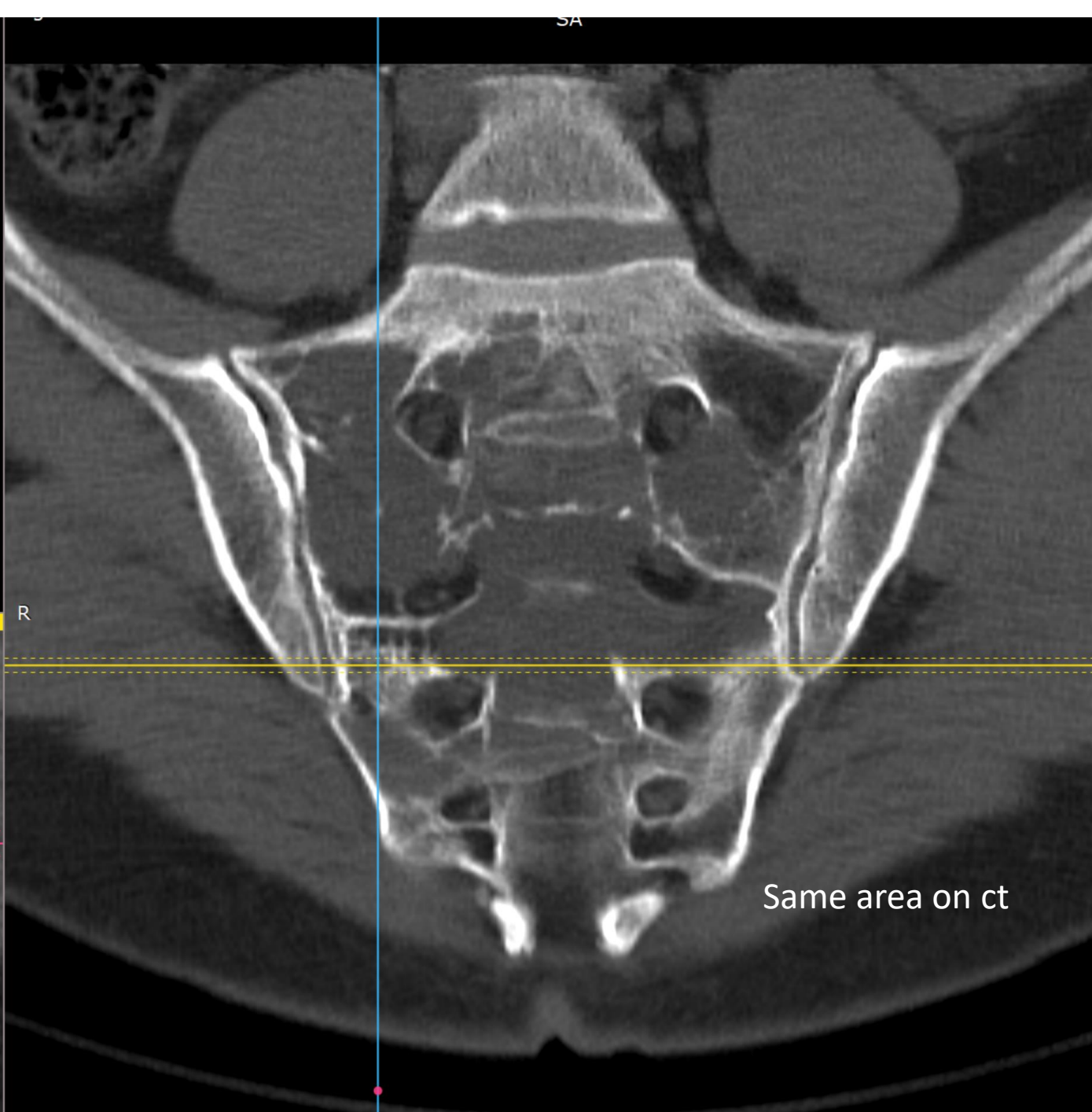
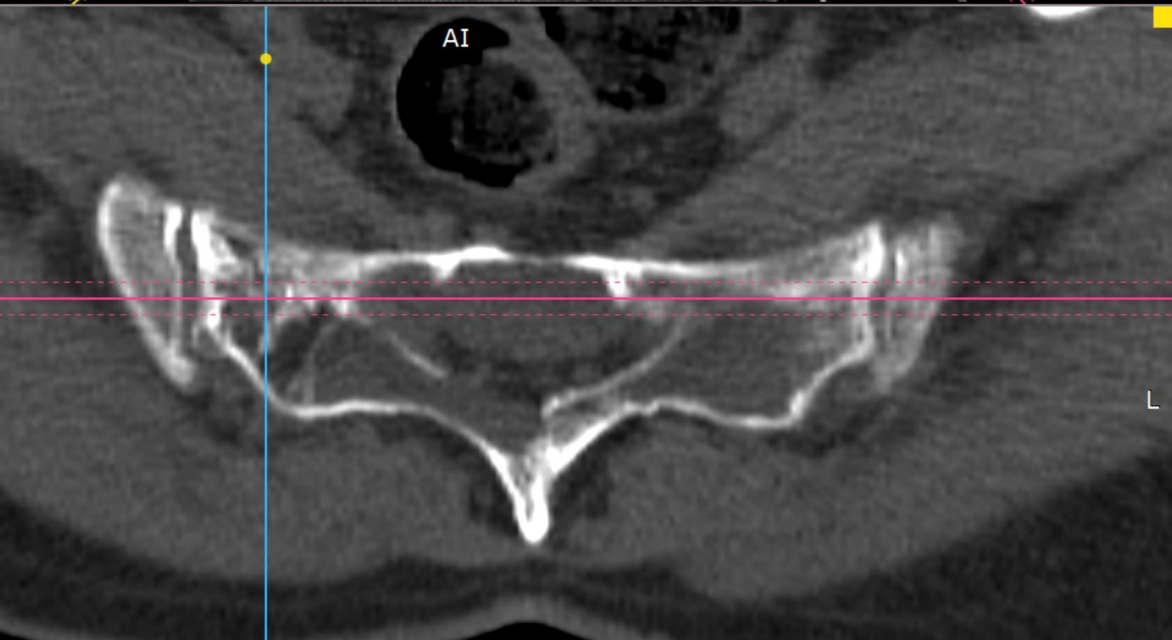
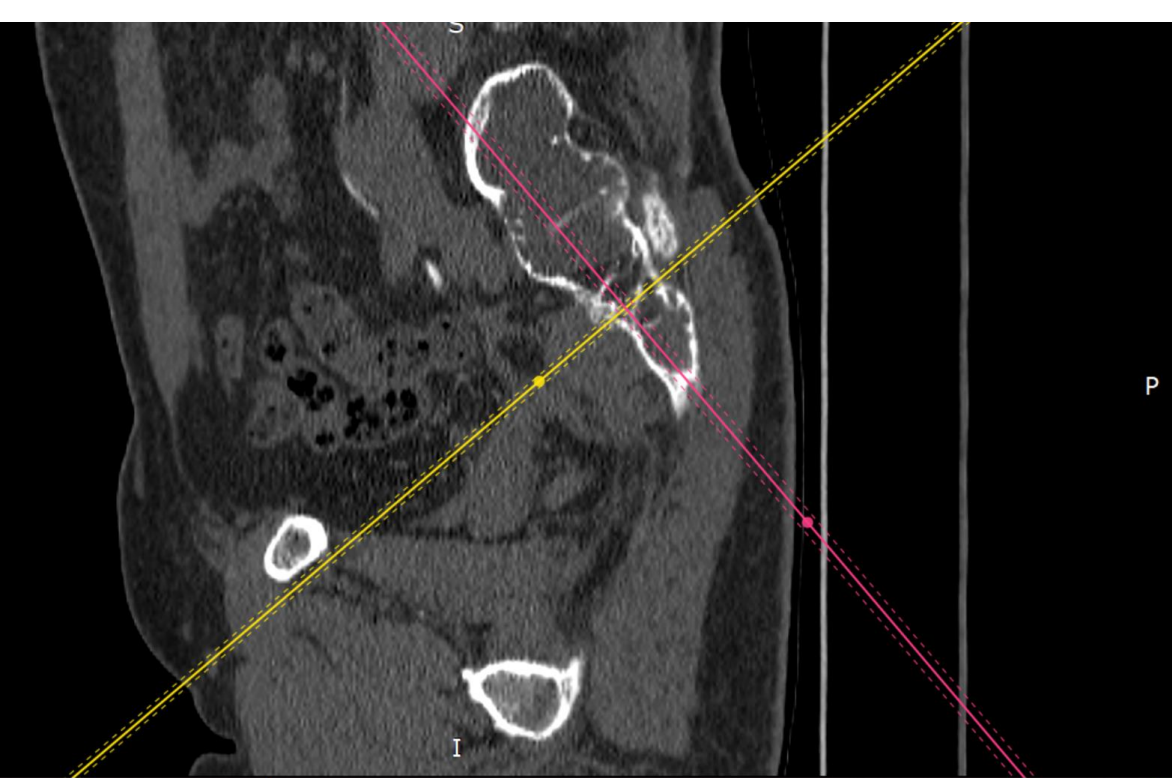
1 - Ax FSE T1 FS

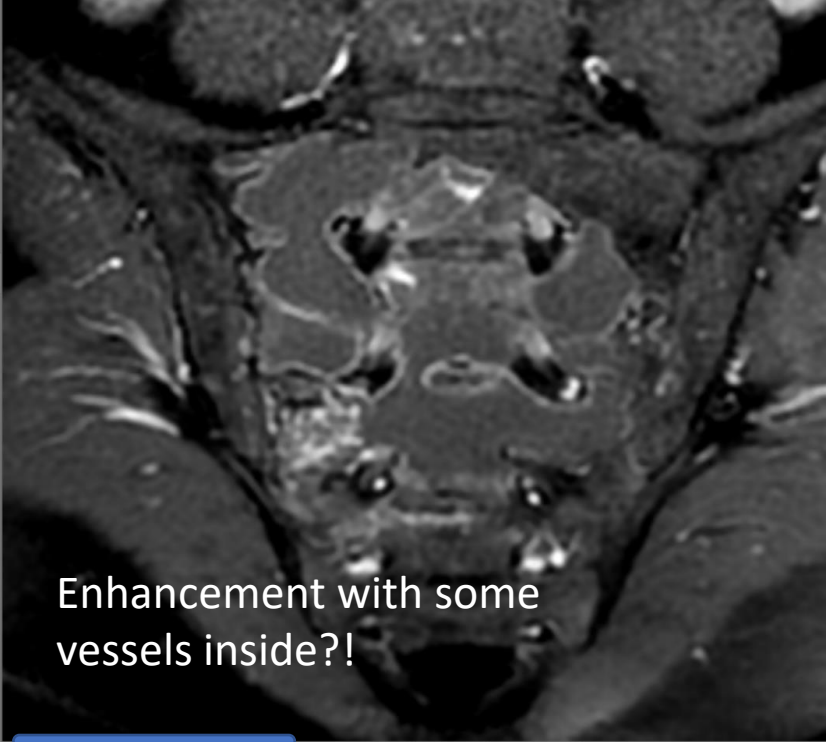
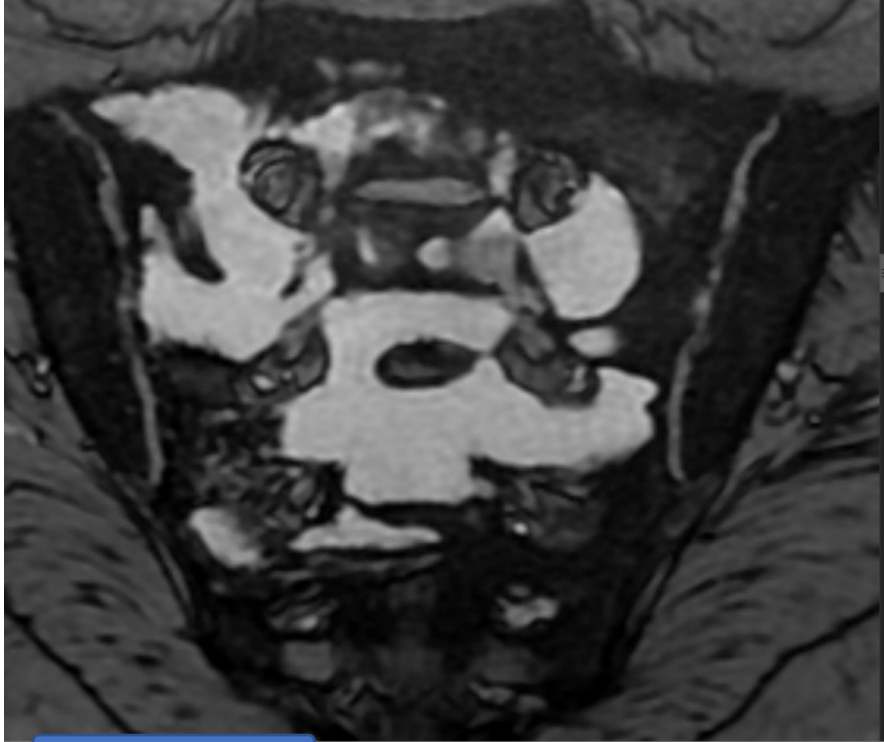


- +C Ax FSE T1 FS



What is this area?

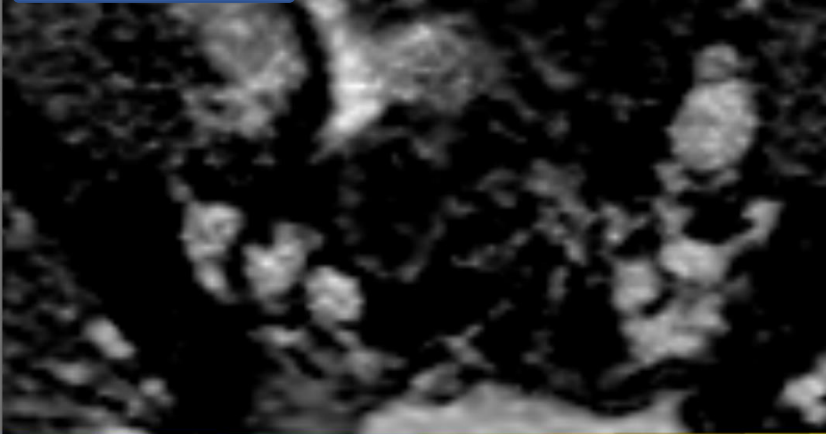




Enhancement with some vessels inside?!

DAI [redacted] WI B1000

[redacted] M - Apparent Diffusion Coefficient (mm²/s)



No dwi restriction

What about these calcifications on the obturator membrane? Any thoughts? Postinflammation? Metabolic?



