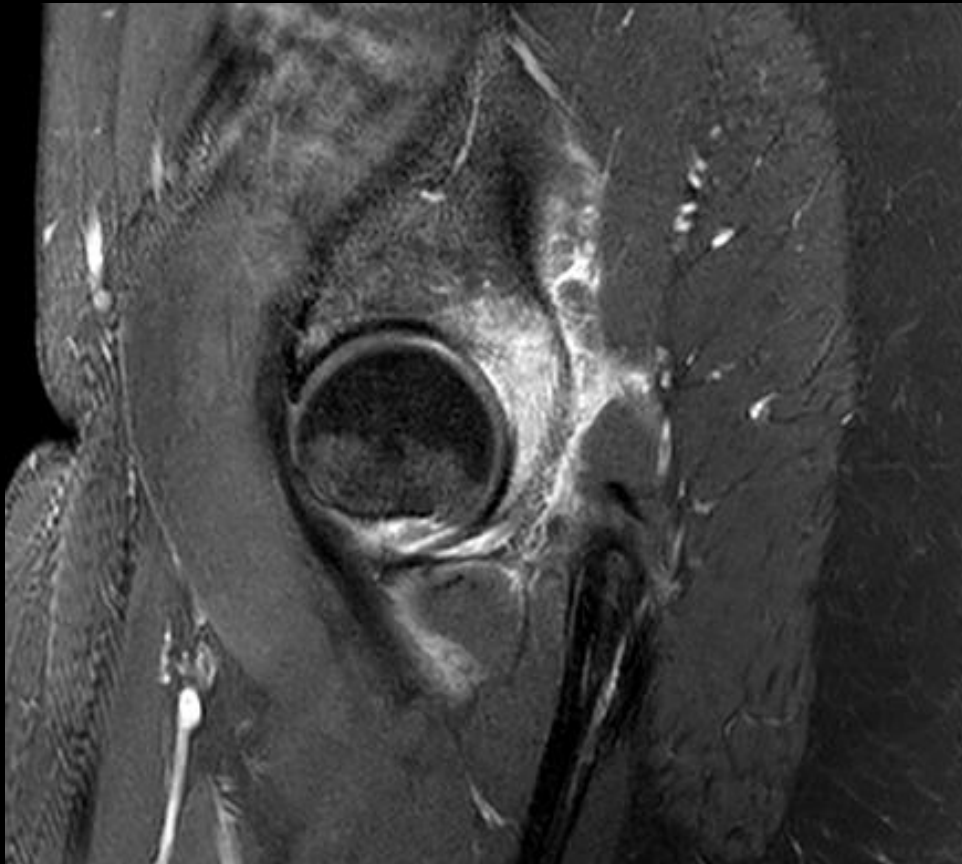
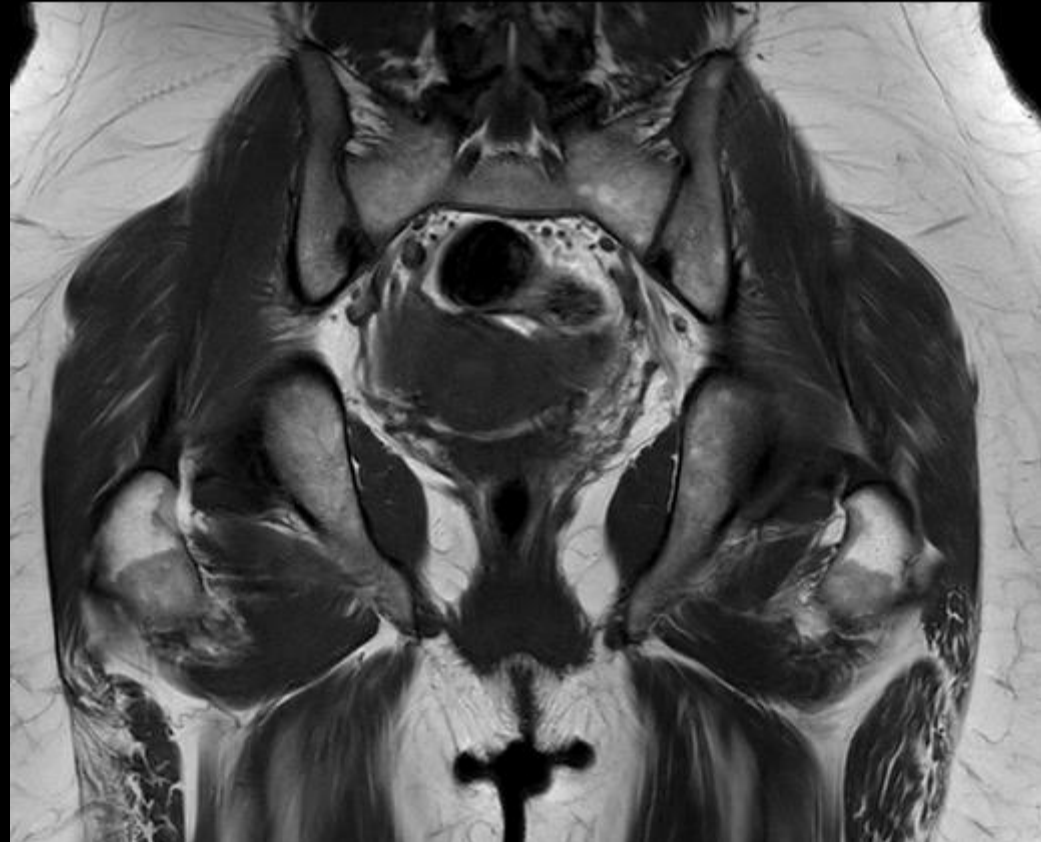

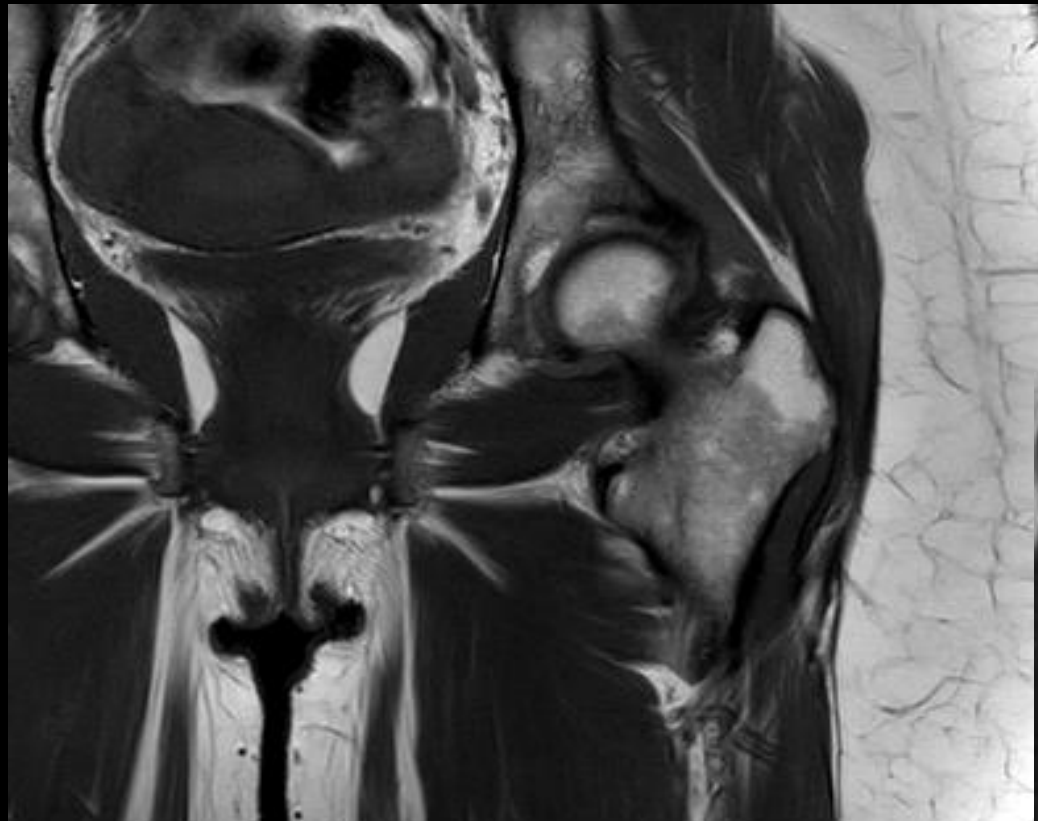
39 YO Female presents to ER with “sudden” and significant Left hip pain. Past Med Hx otherwise unremarkable

T1W-fs with con

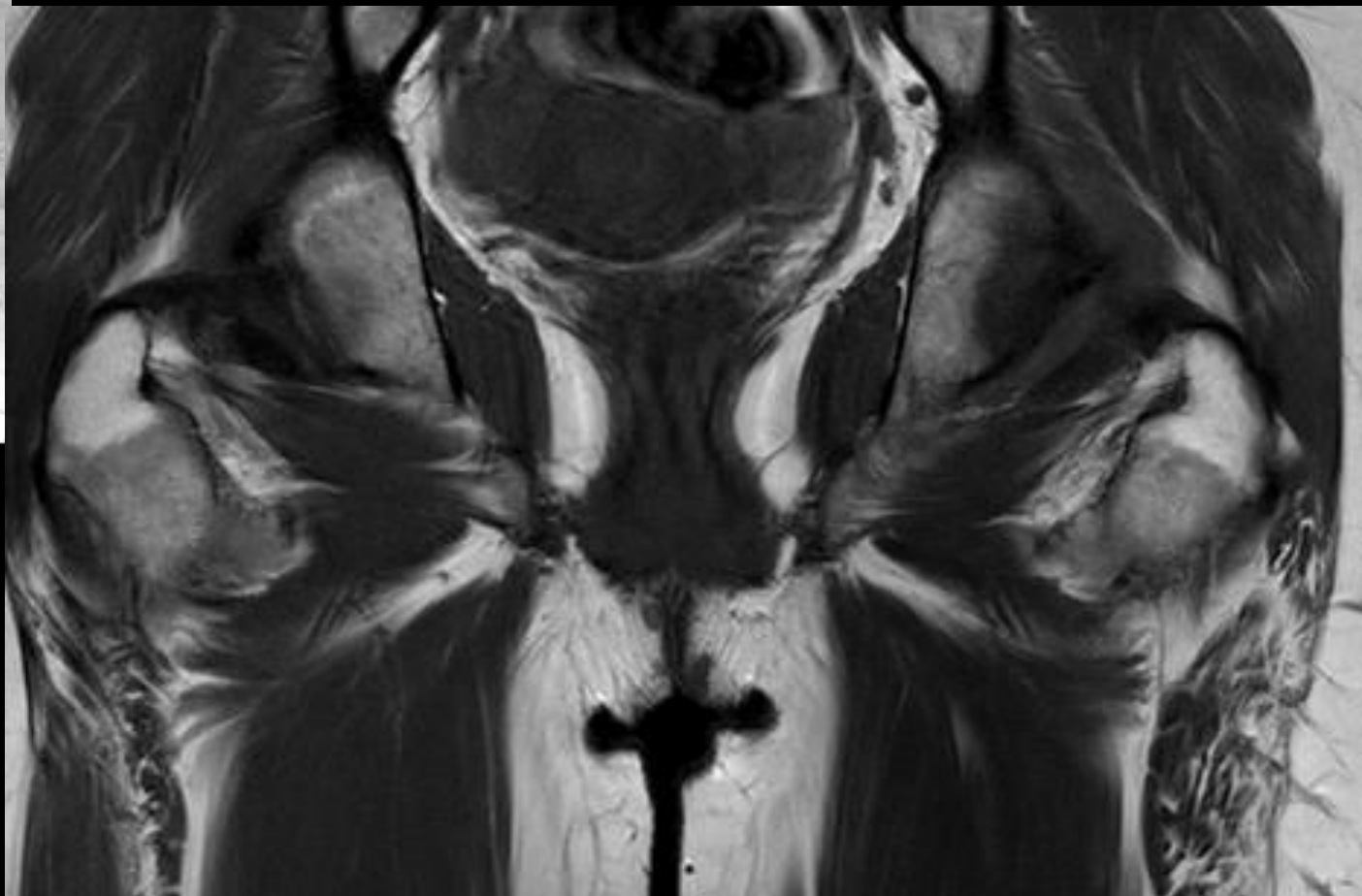


T1



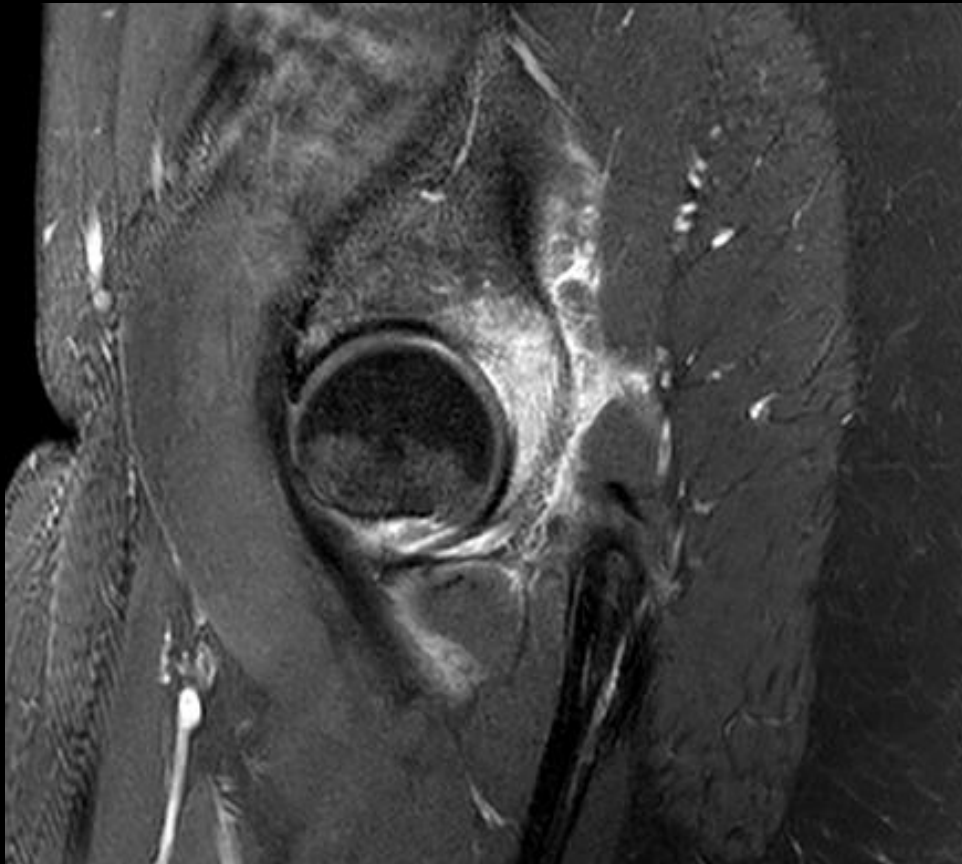


T1W

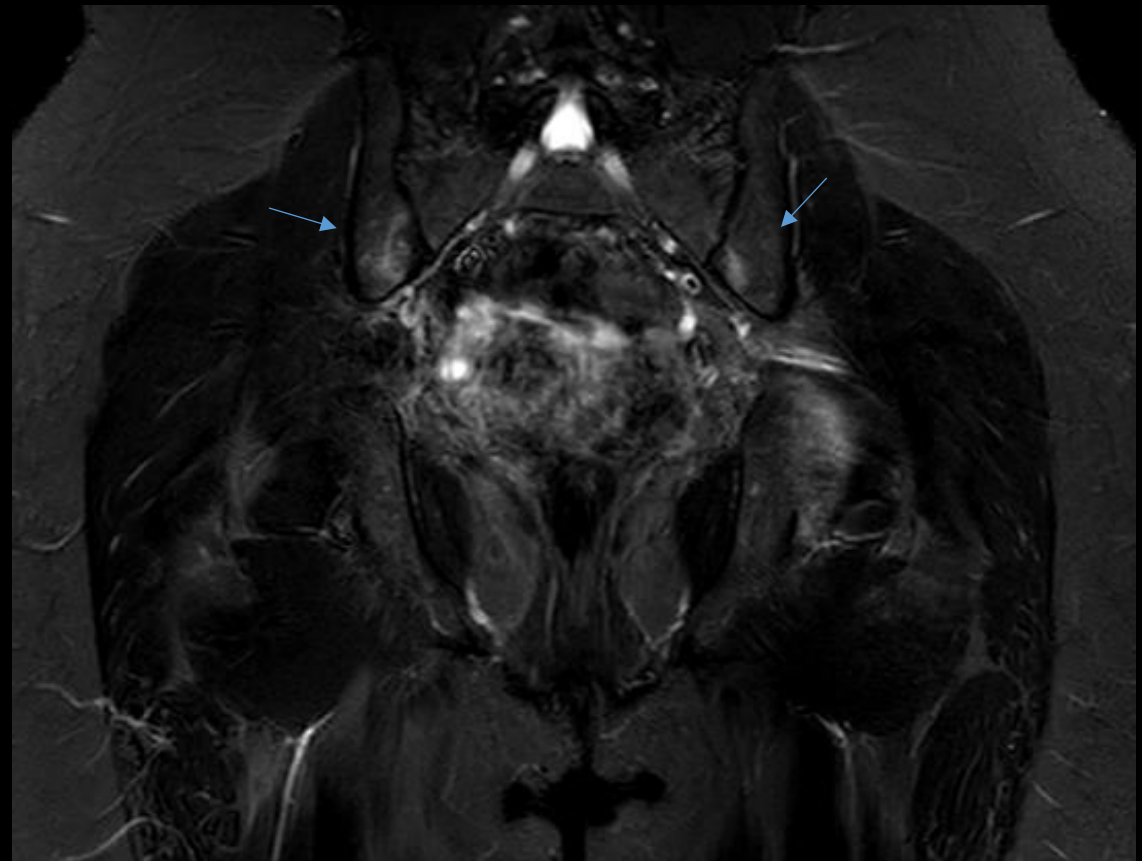


39 YO Female presents to ER with “sudden” and significant Left hip pain. Past Med Hx otherwise unremarkable

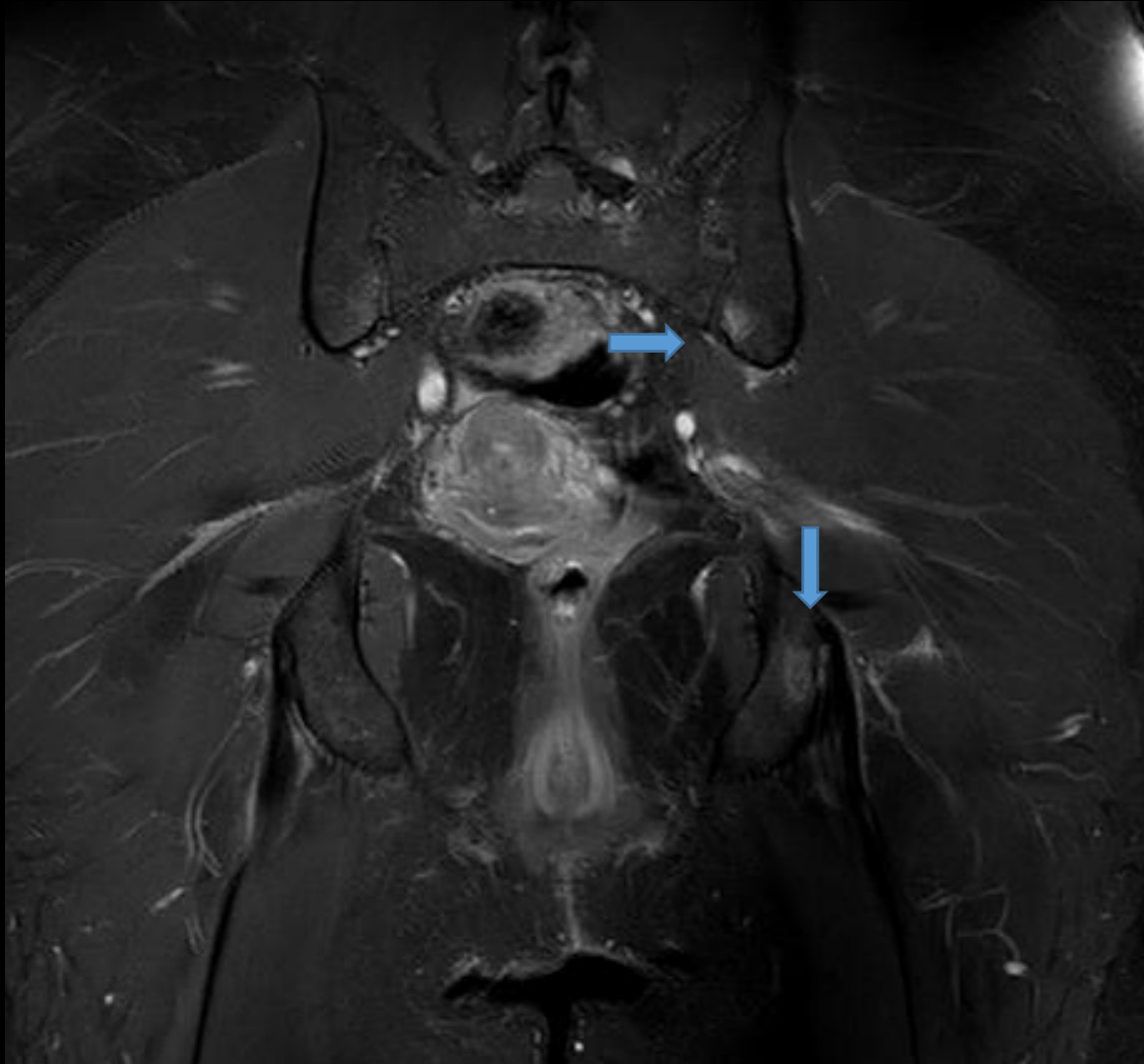T1W-fs with con



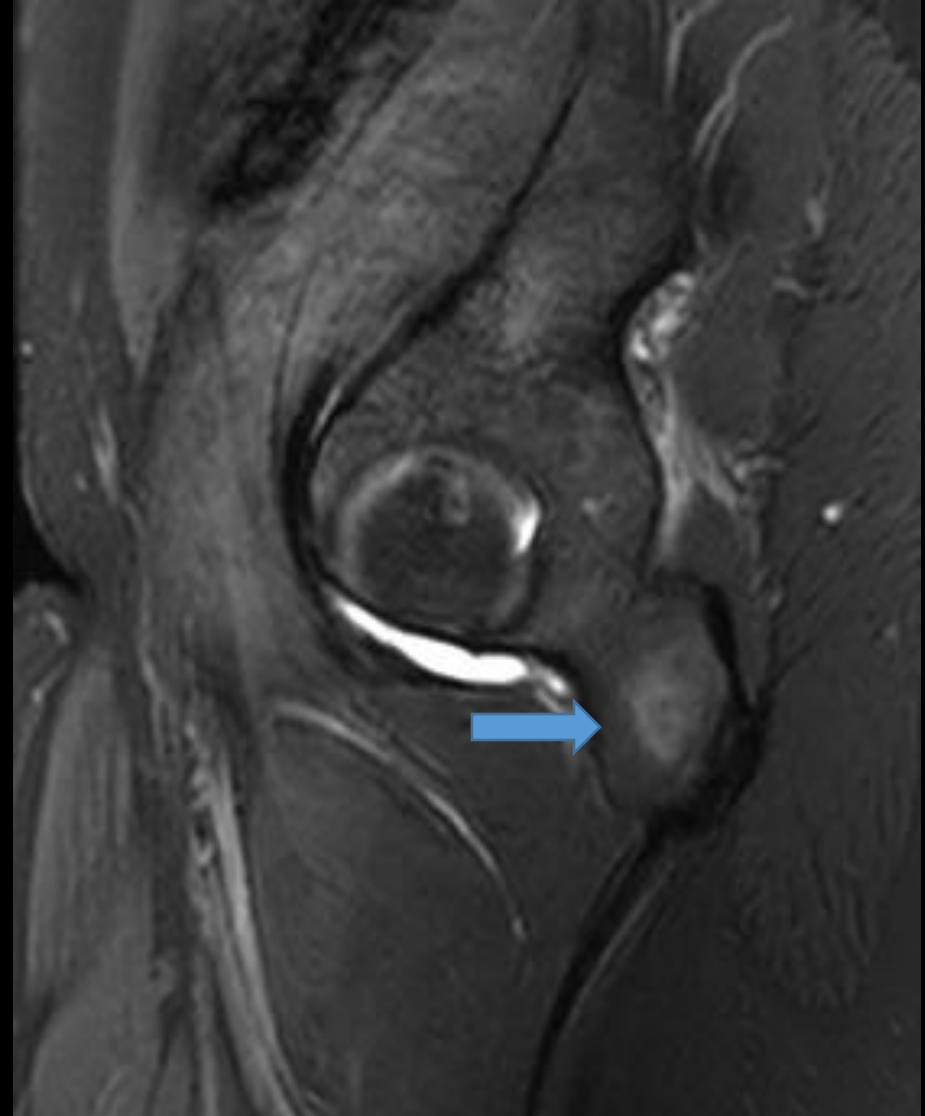
STIR

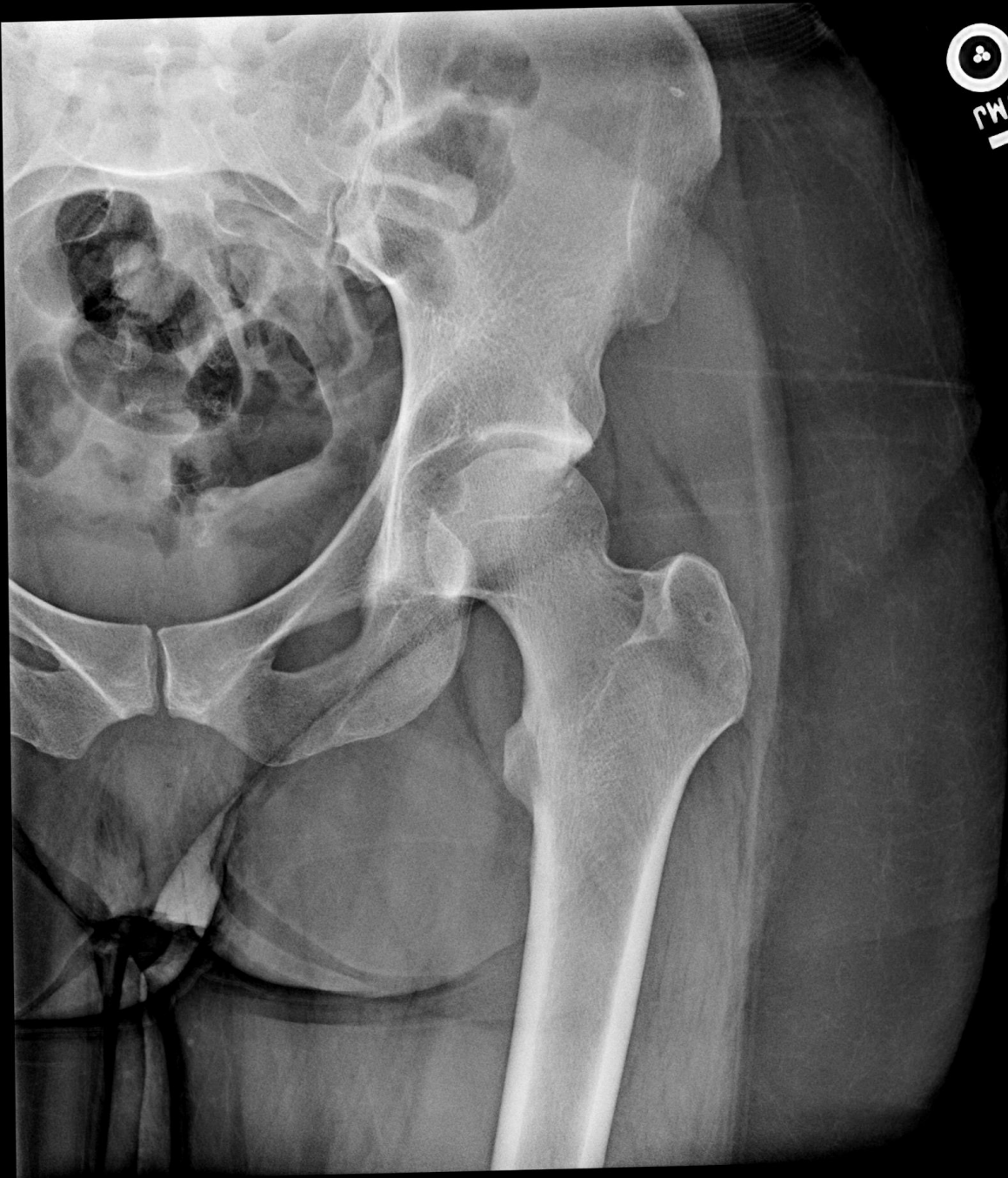

T1W-fs with



PD fs





BMJ
L

