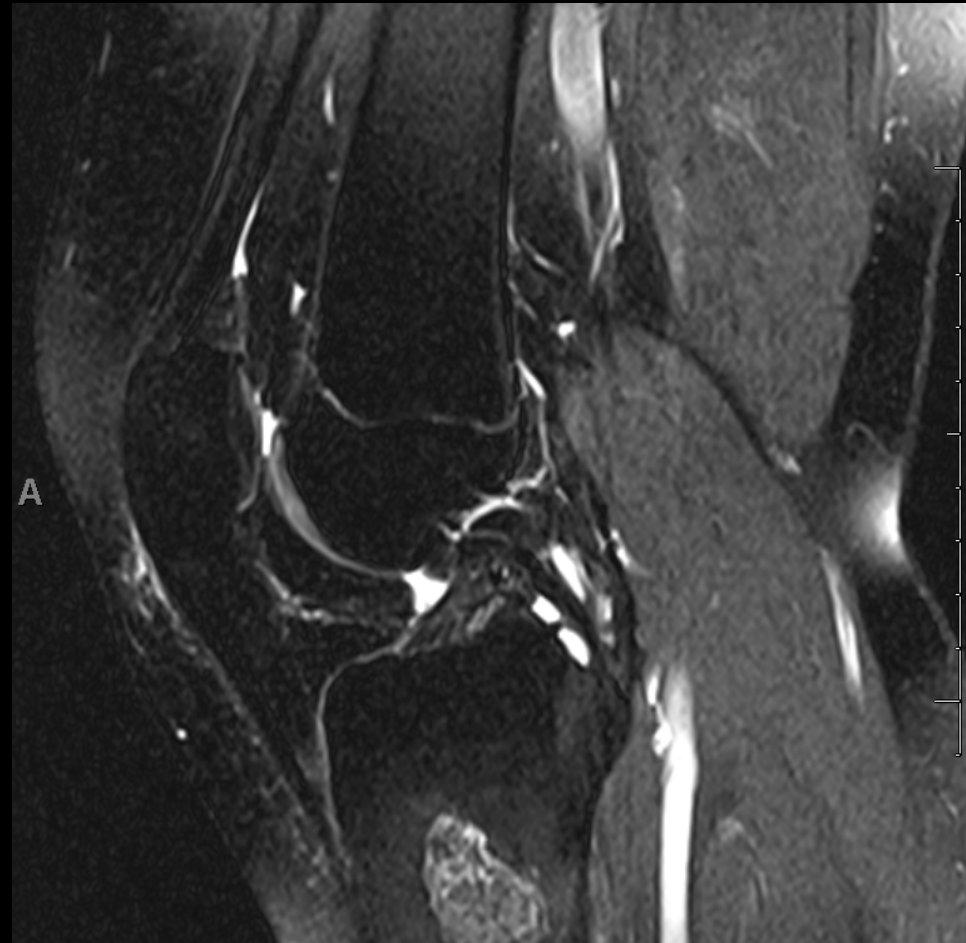
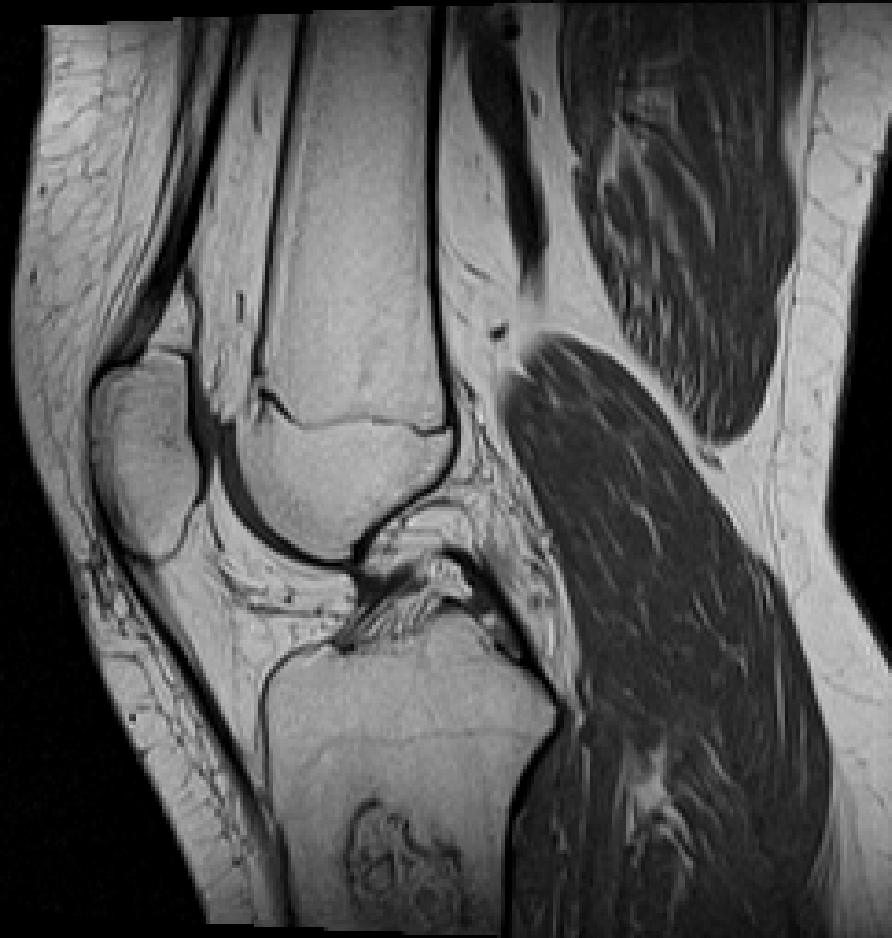
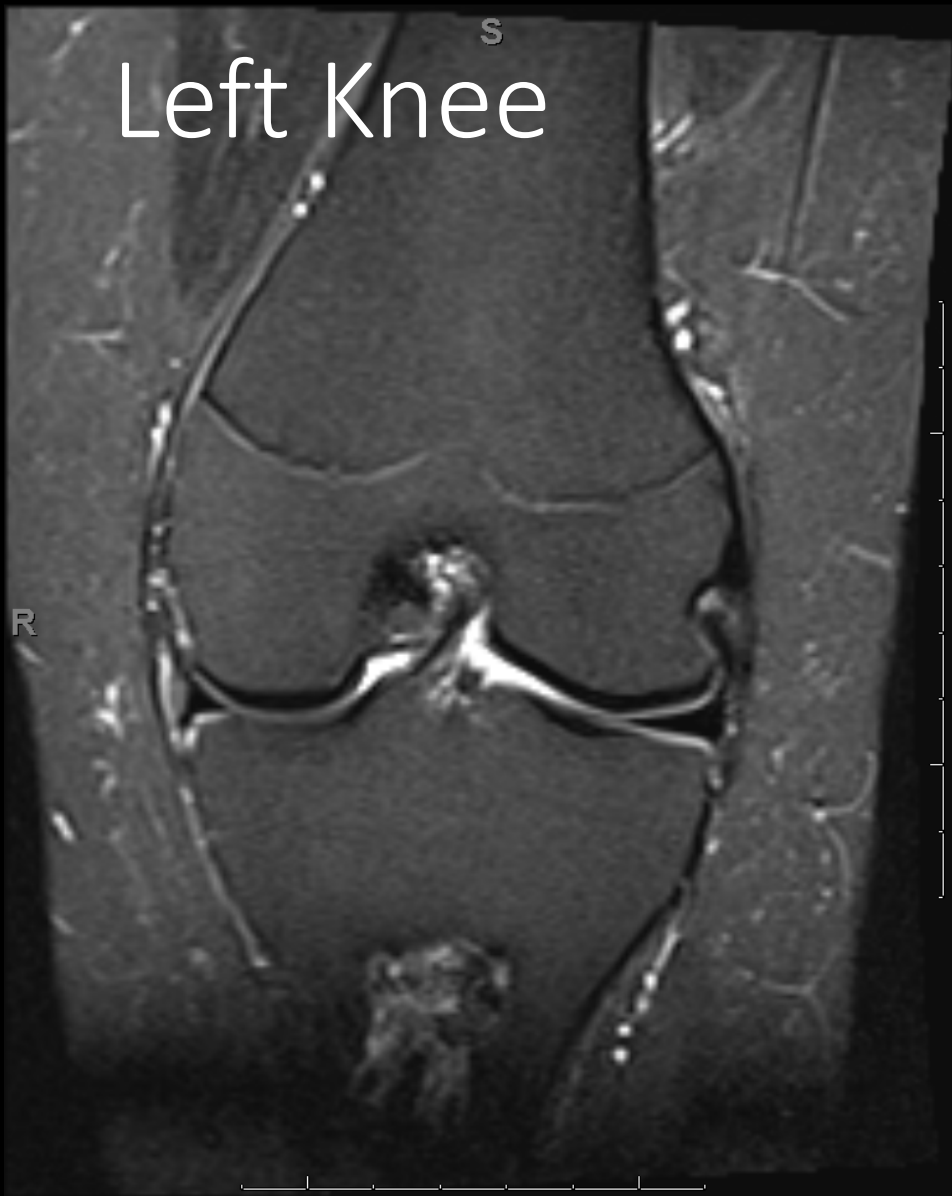
16 YO with pancytopenia and ALL. “Acute and severe bilateral knee pain. Possible septic joint”

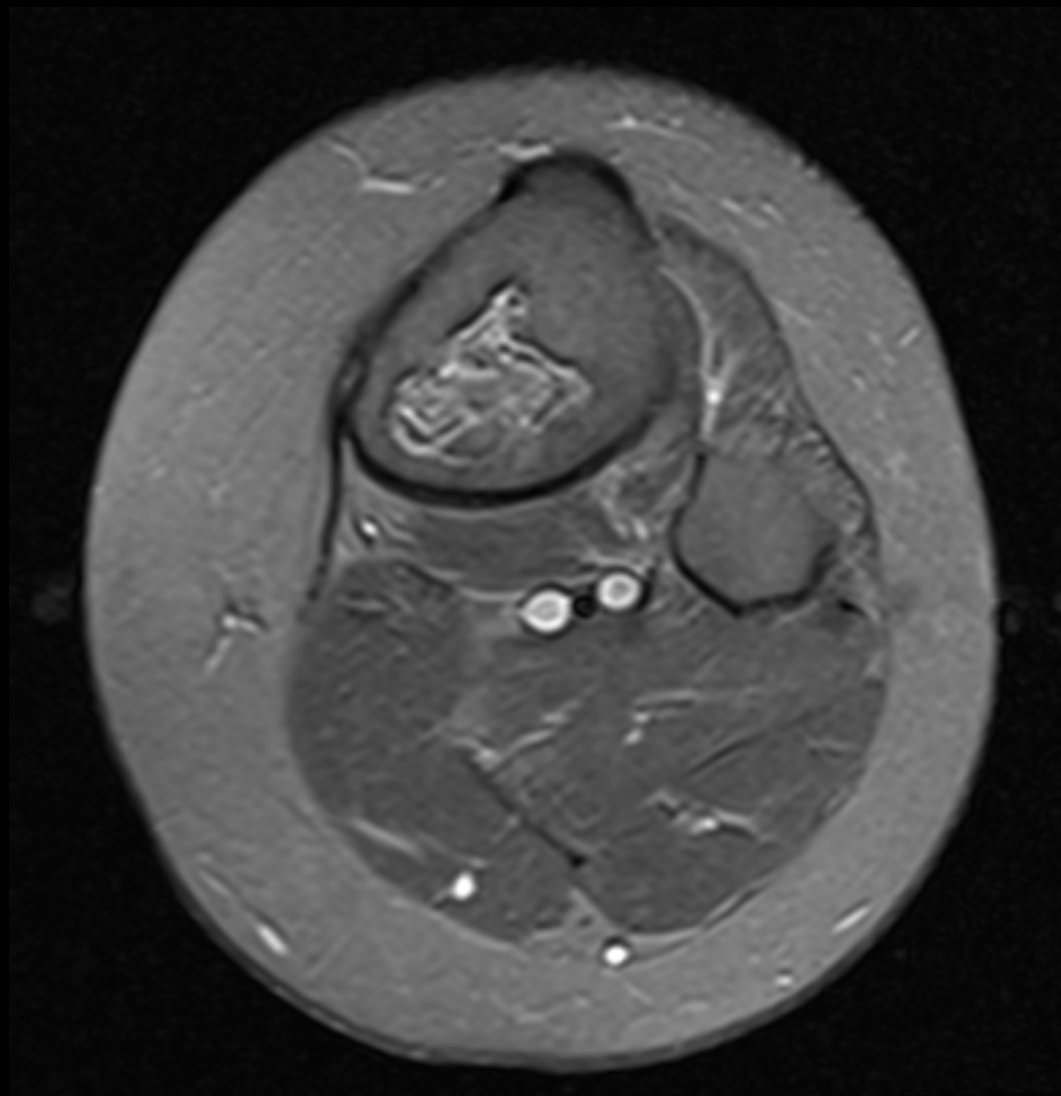
Left Knee



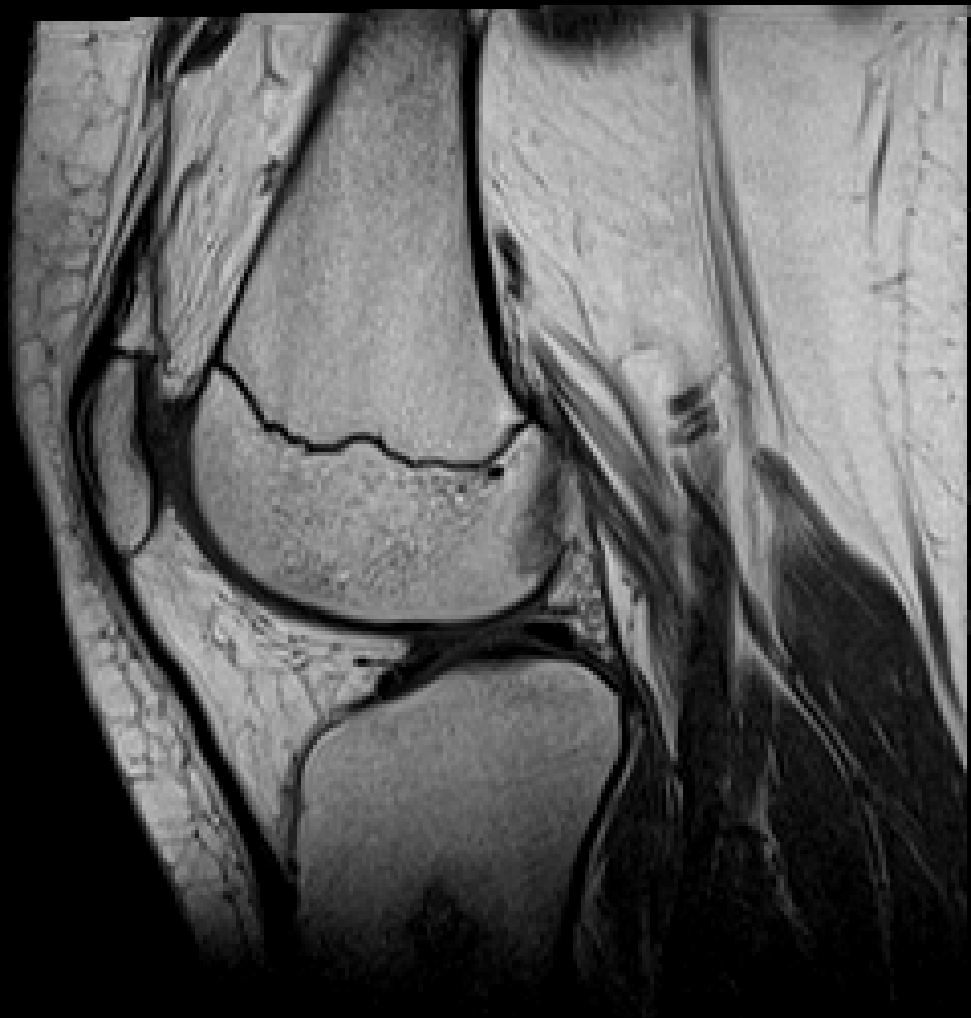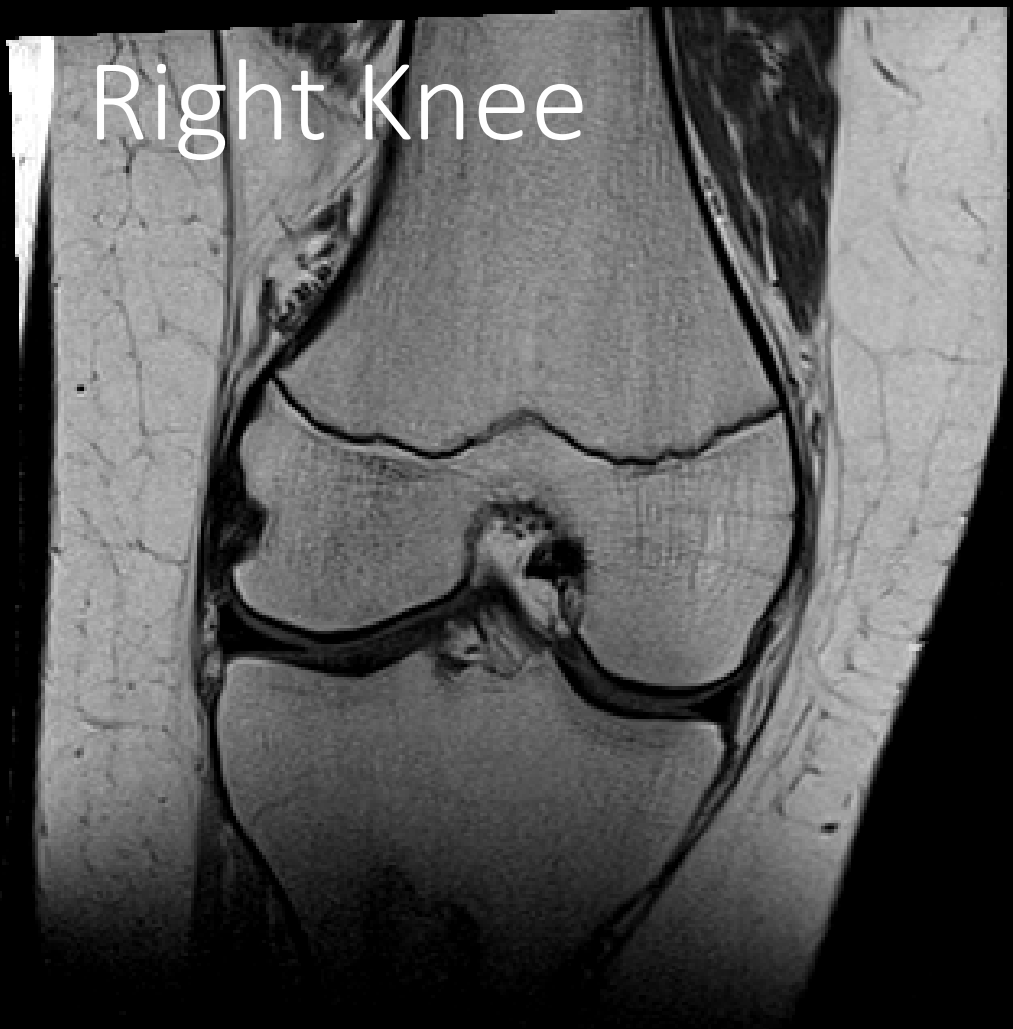Left Knee



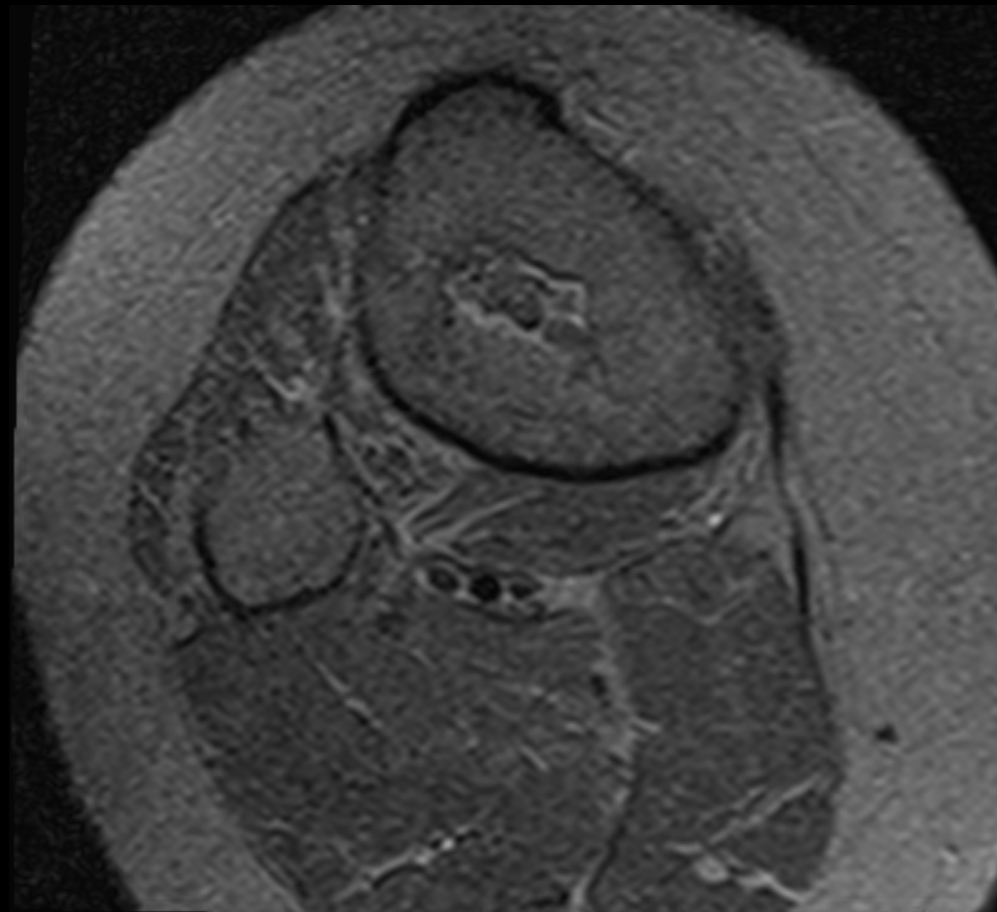
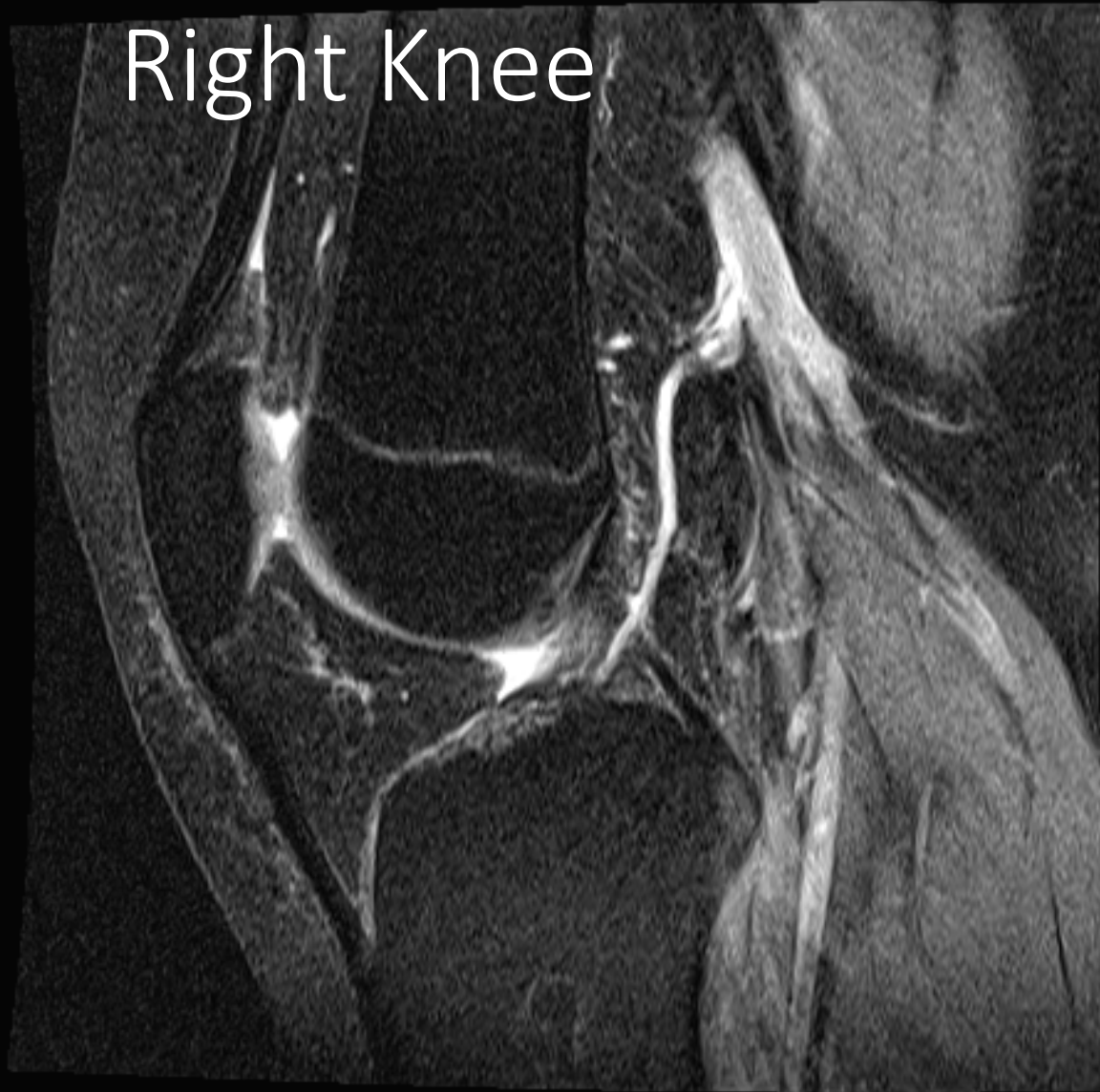Coronal Link



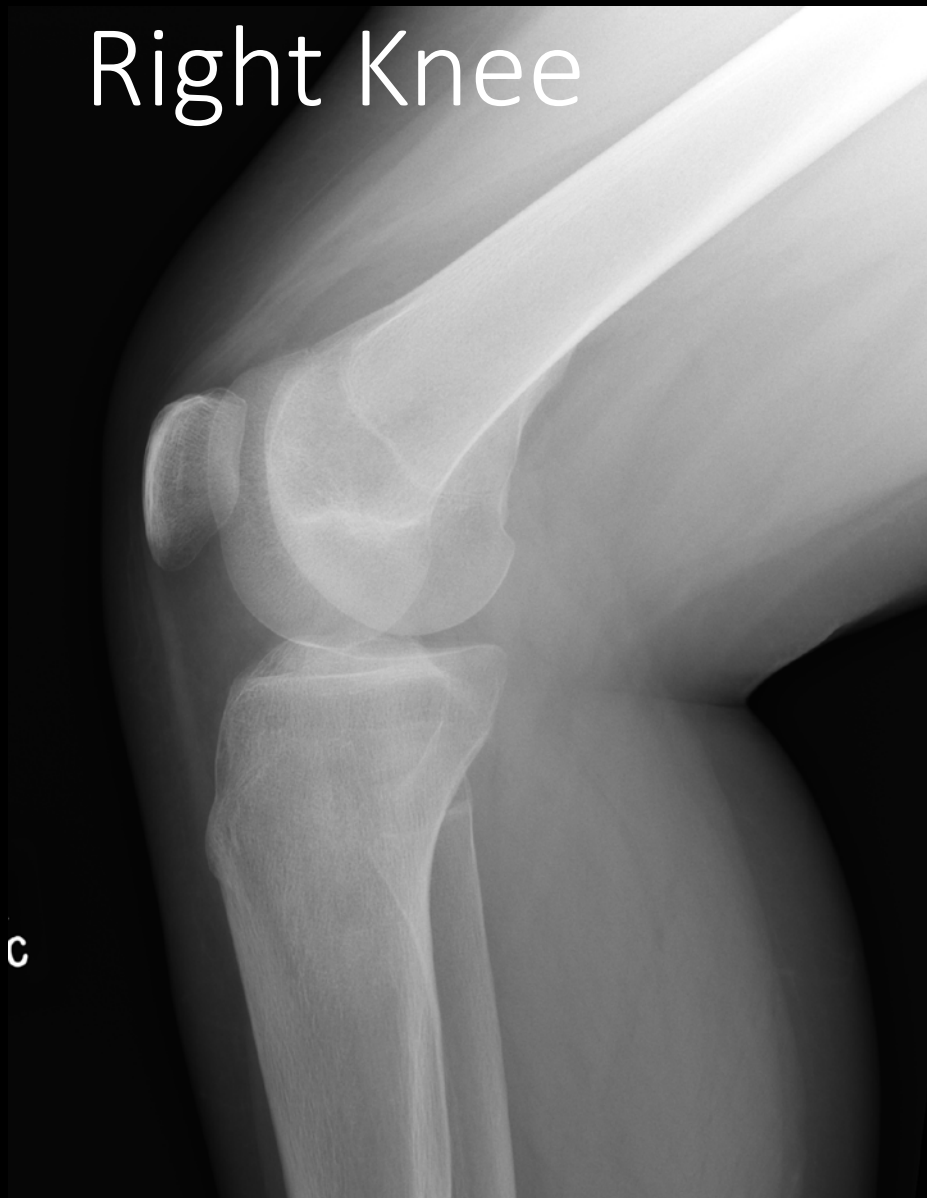
Right Knee



Right Knee



Right Knee



Left Knee



