

49/F, Palpable subcutaneous anechoic bean-like nodules adjacent to cephalic vein at the left proximal upper arm for 6 weeks

- Past medical history
  - ORIF for right distal femur open fracture on car accident 5 months ago
  - Local gynecology clinic, suspected of vaginitis and blisters on lips  
--> HSV on acyclovir, 2 months ago

MSK Superfic

TIS0.0 MI 0.6

L12-5

76Hz

RS

M2

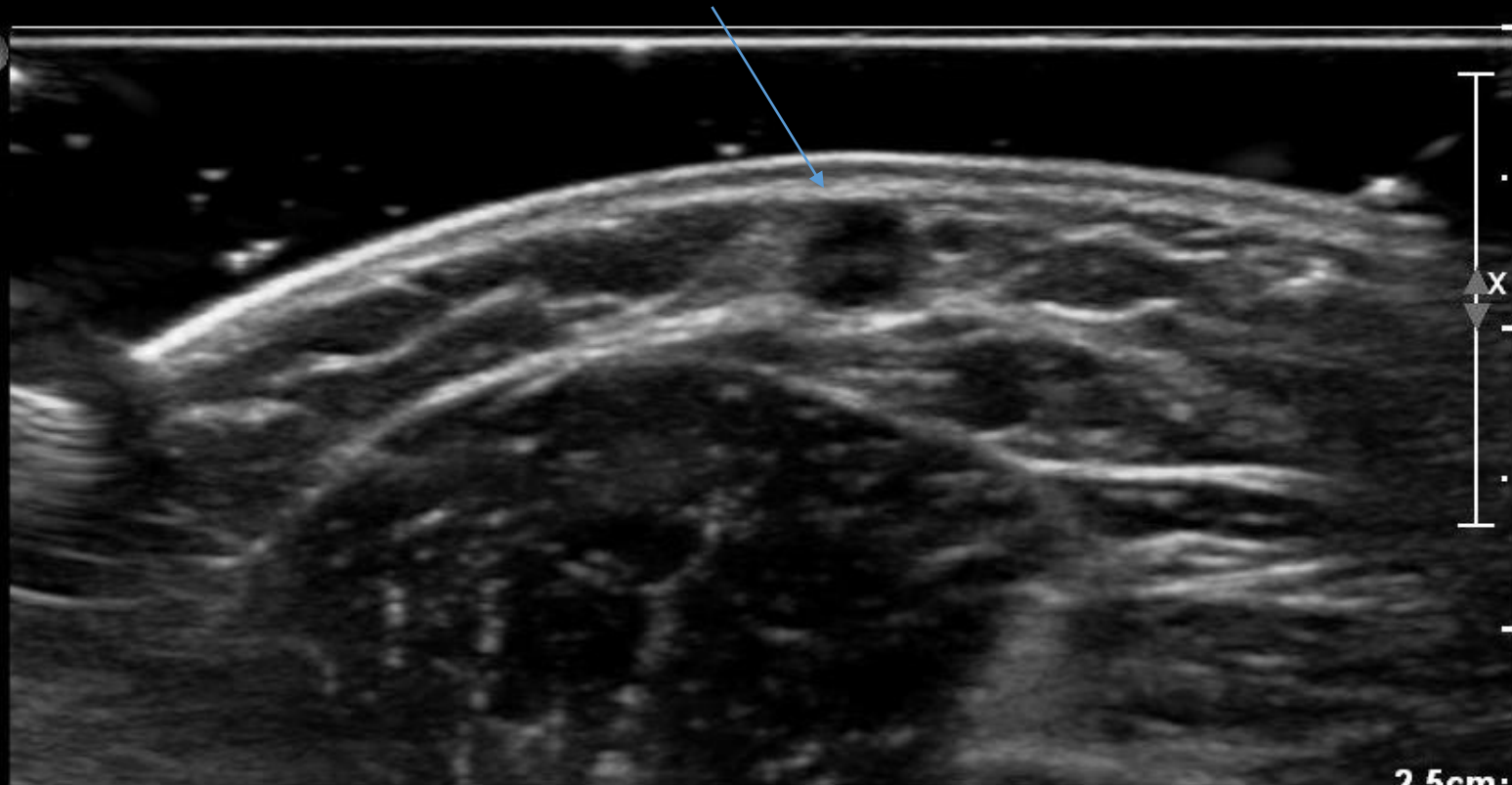
2D

27%

Dyn R 55

P Low

Res



2.5cm

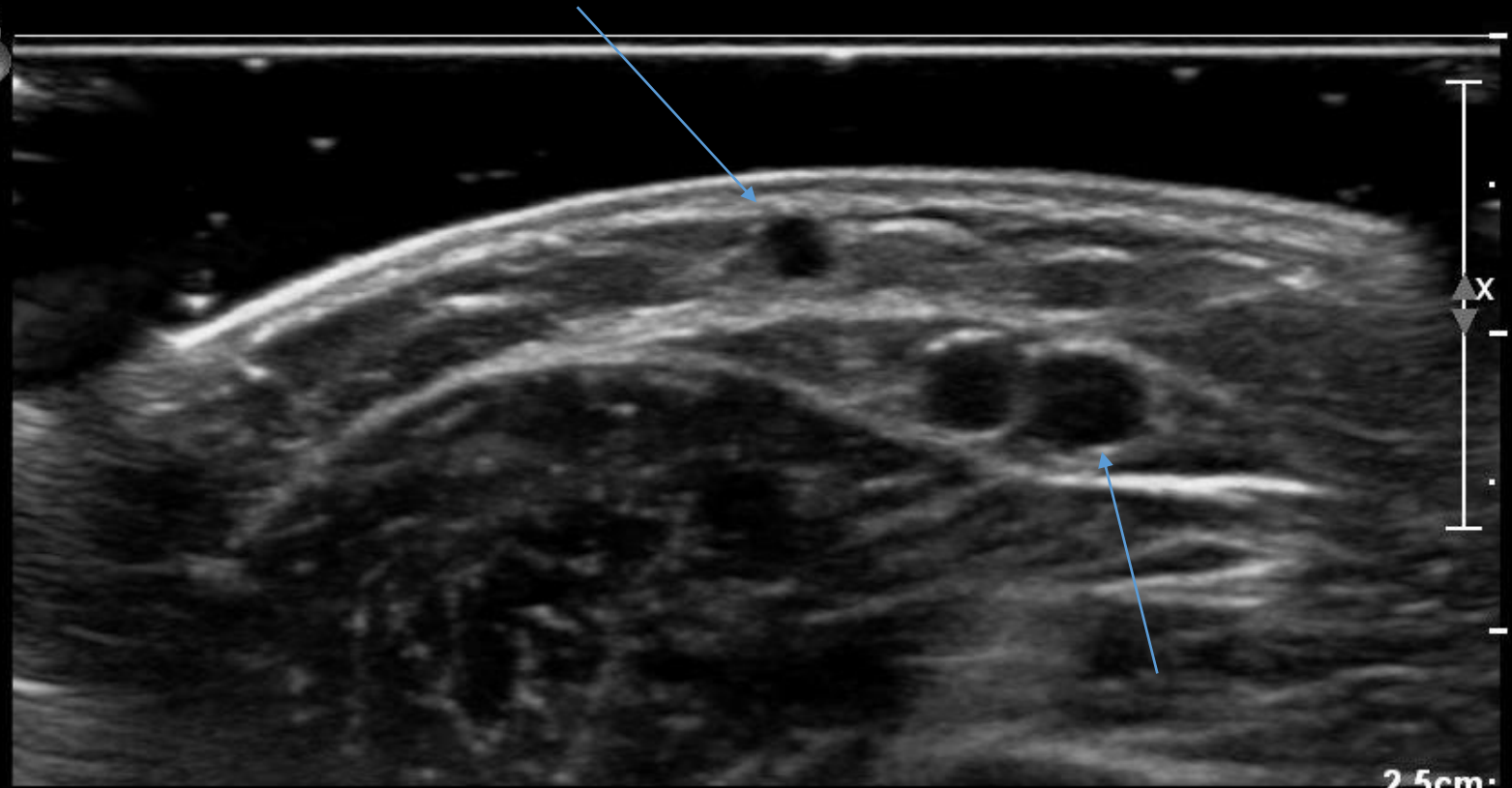
MSK Superfic

TIS0.0 MI 0.6

L12-5  
76Hz  
RS

M2

2D  
27%  
Dyn R 55  
P Low P  
Res



2.5cm

MSK Superfic

TIS0.1 MI 0.7

L12-5

8Hz

2D

57%

Dyn R 60

P Med P

Res

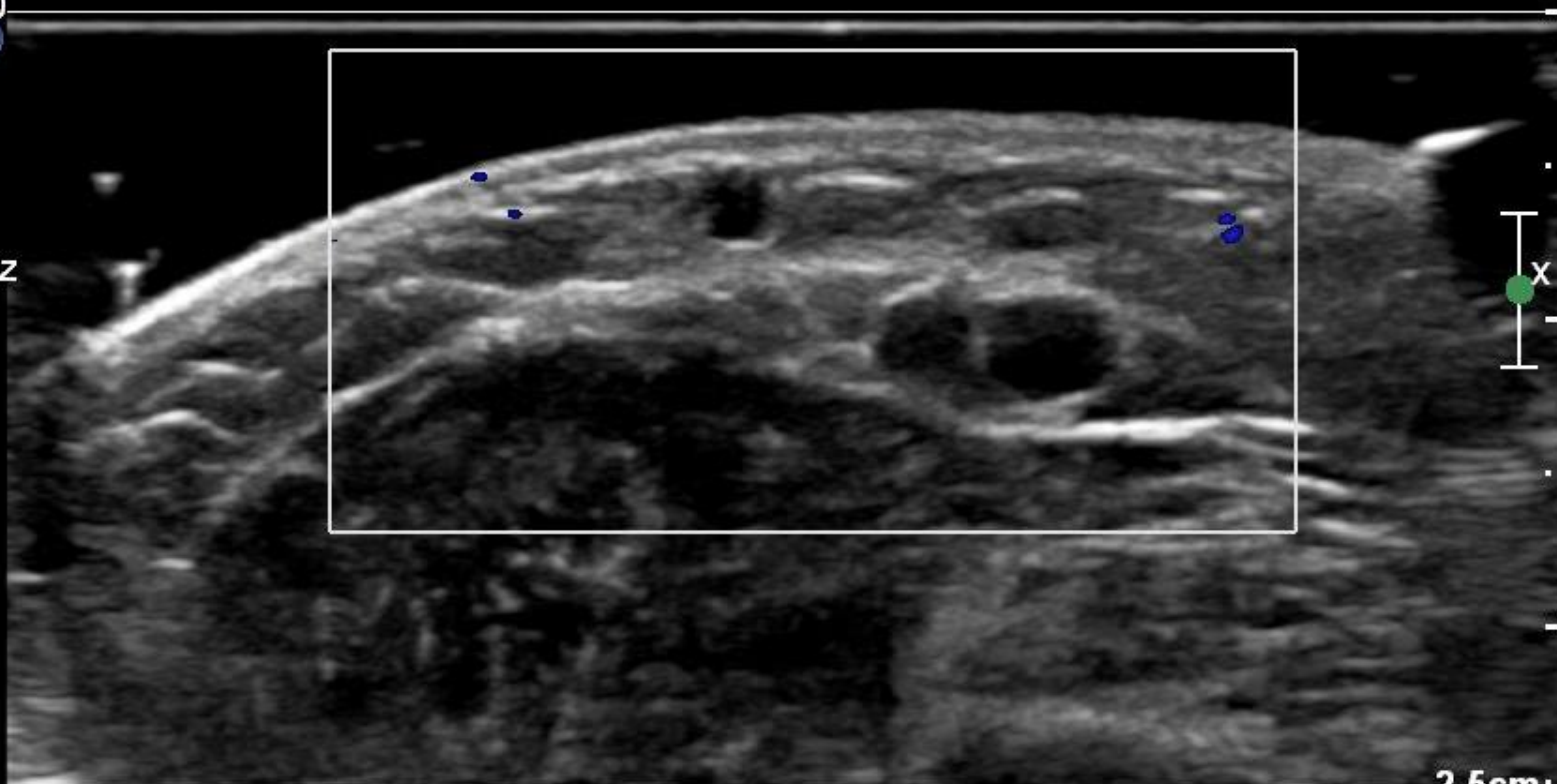
CF

47%

649Hz

WF 35Hz

6.3MHz



M2 M3

+4.0



-4.0

cm/s

2.5cm

MSK Superfic

TIS0.0 MI 0.6

L12-5  
76Hz  
RS  
Z 1.0

x

x

Firm nodules, not compressible

2.5cm

