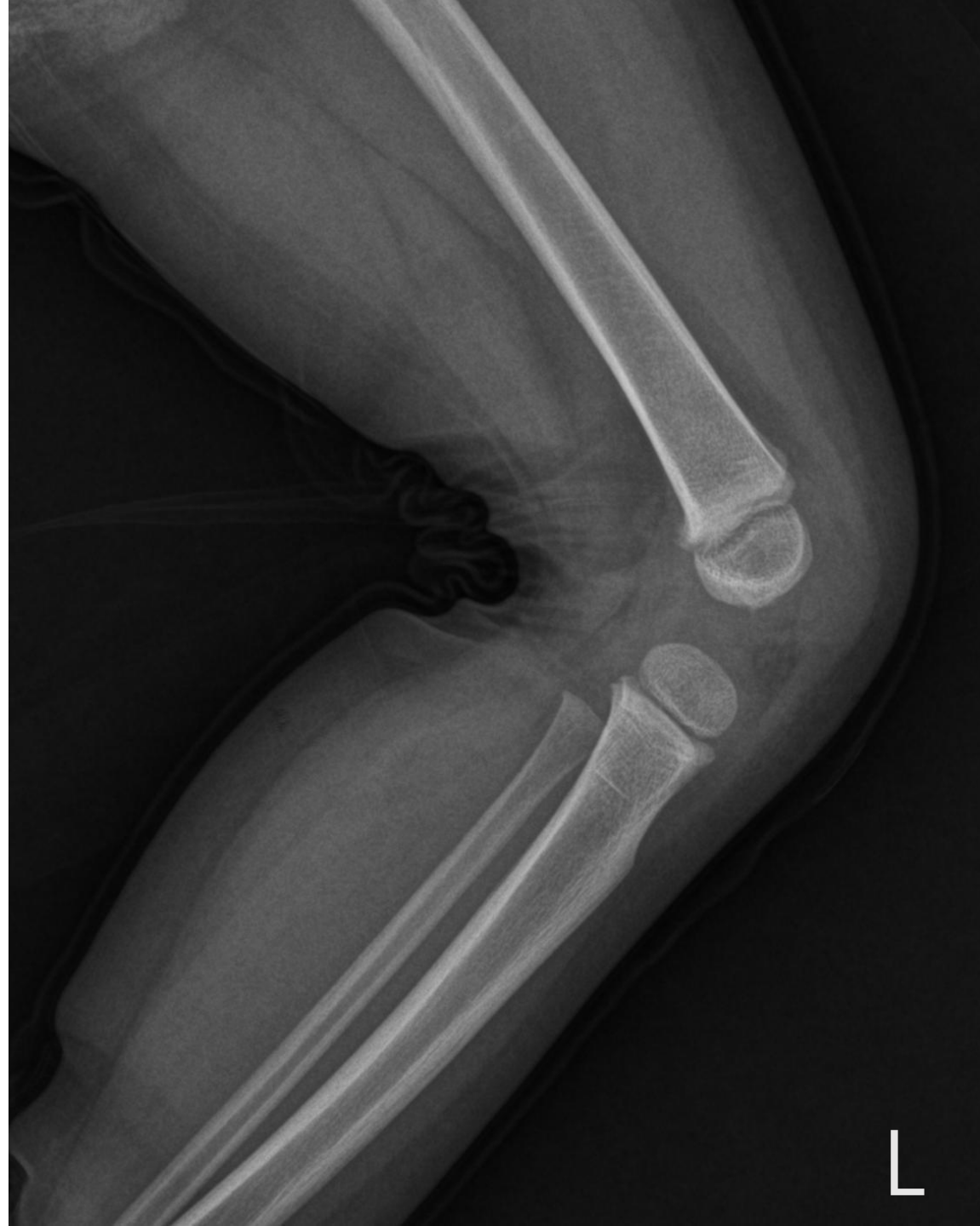
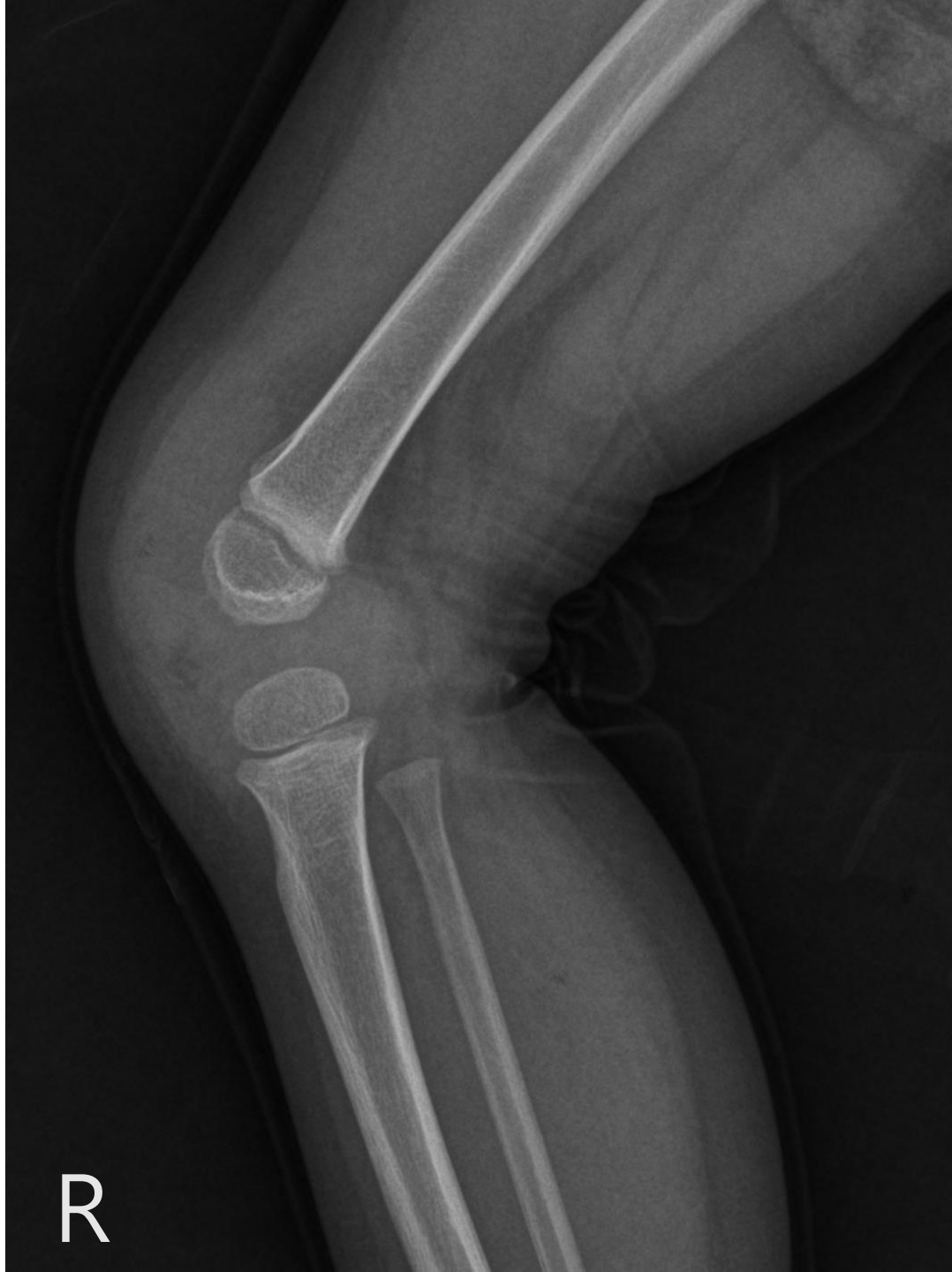
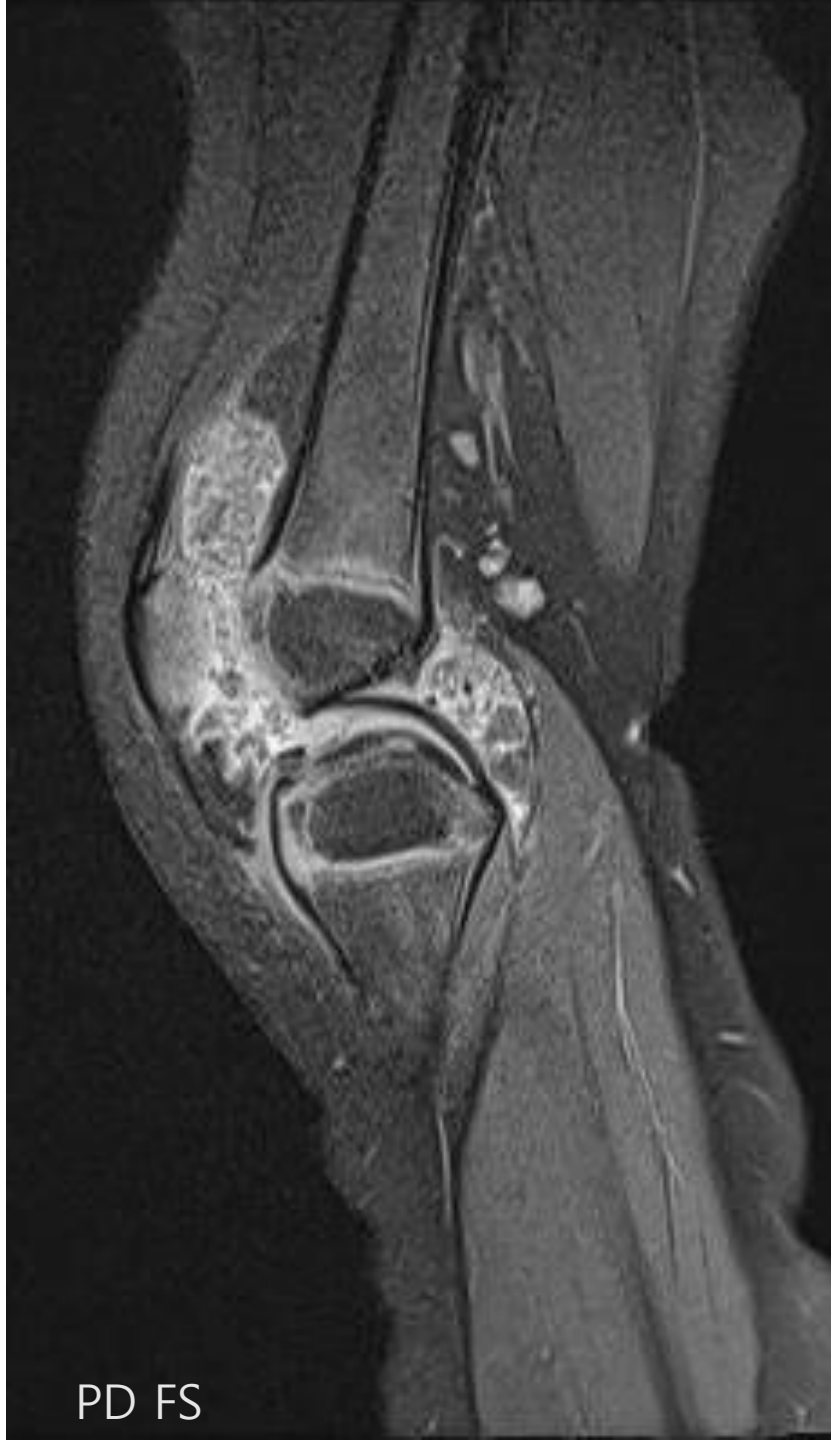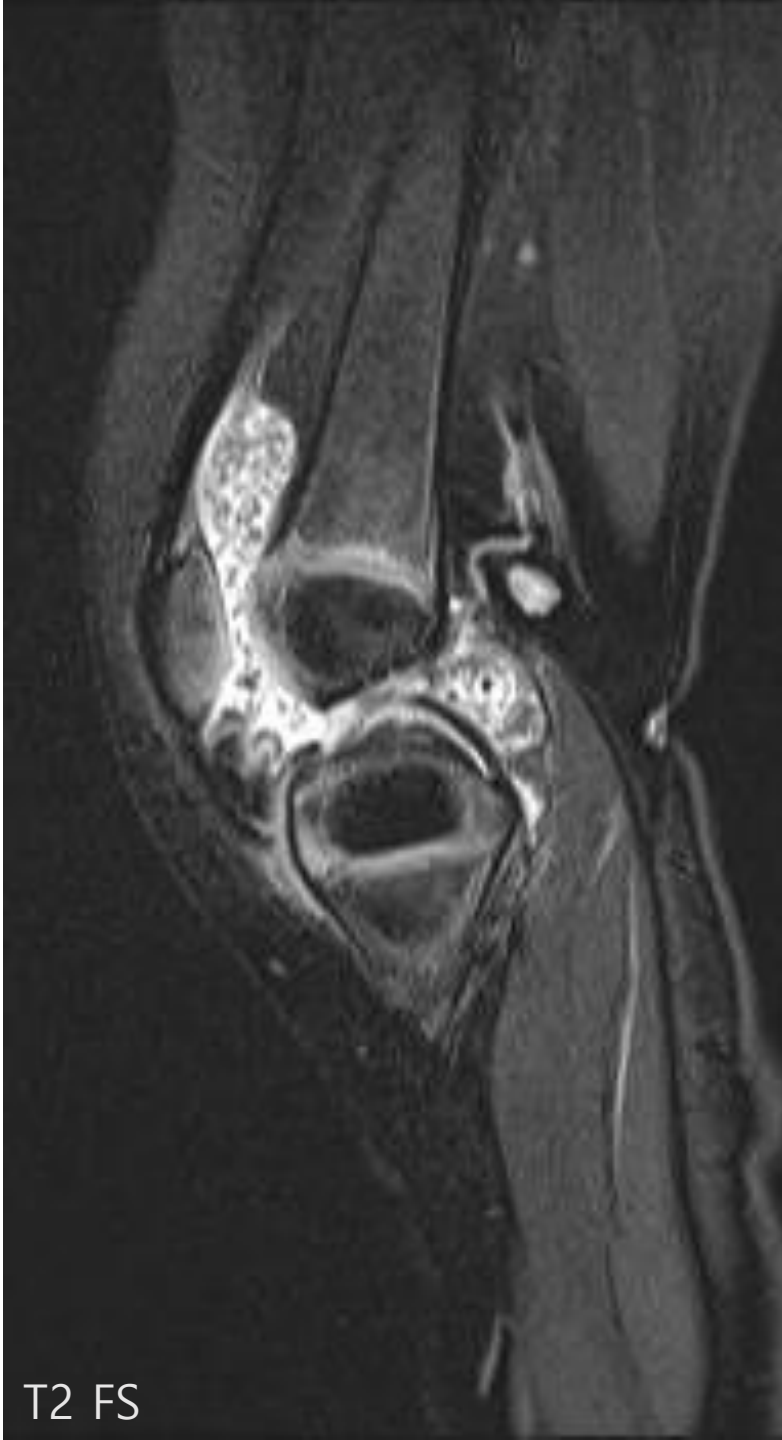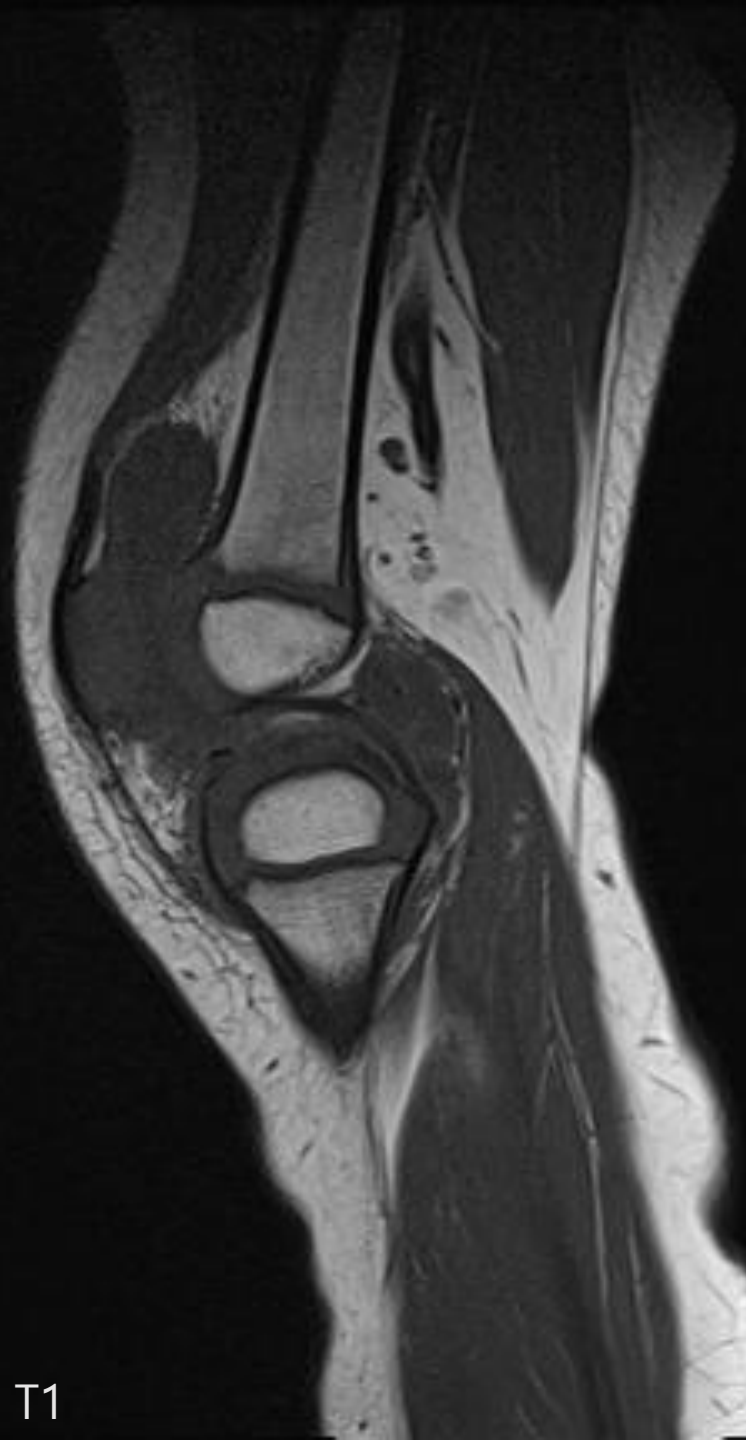2-year-old female

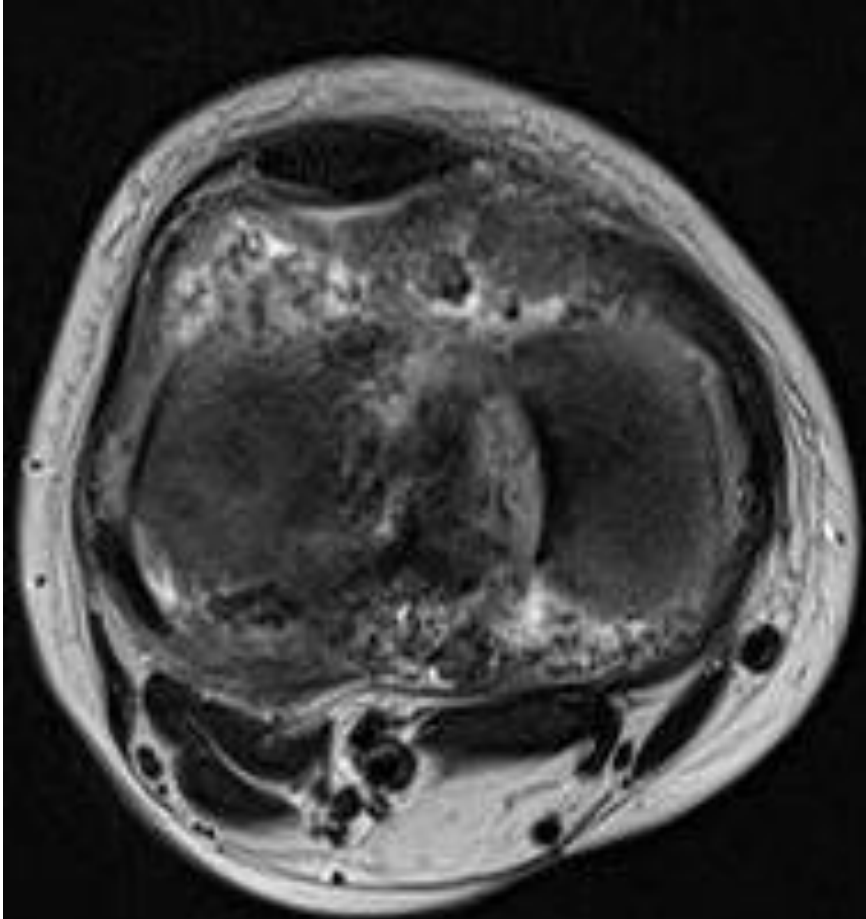
Right knee joint LOM for 1 month

URI (+) 6 months ago

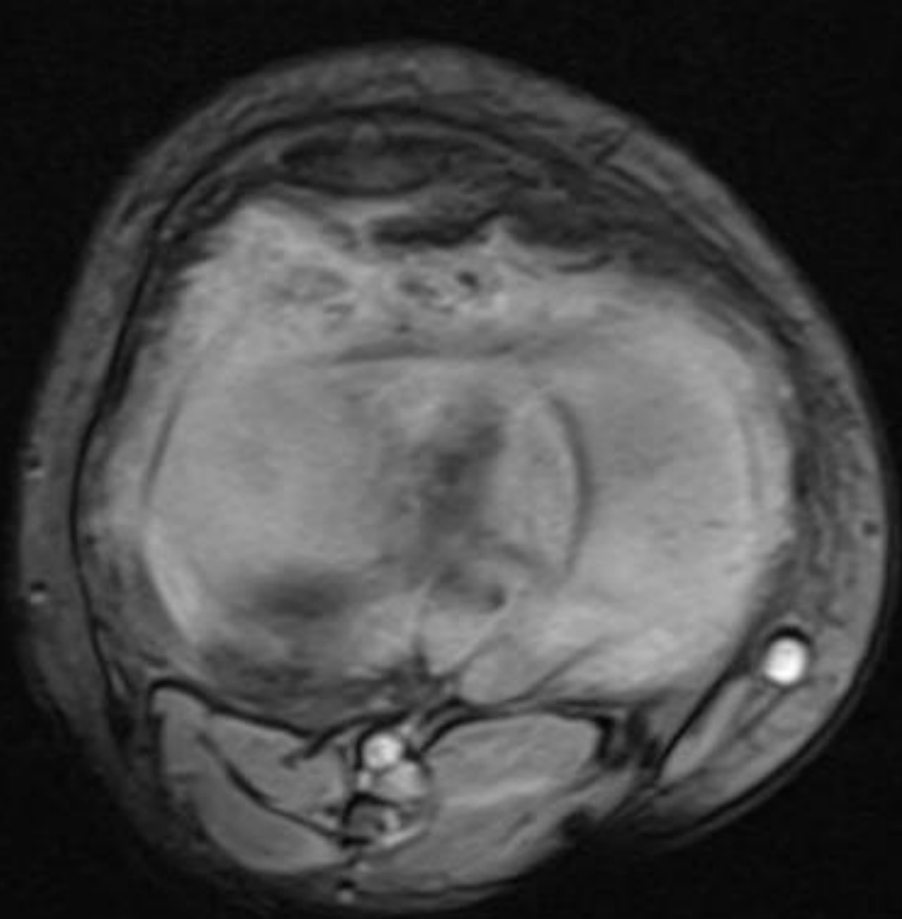
Tenderness (-)



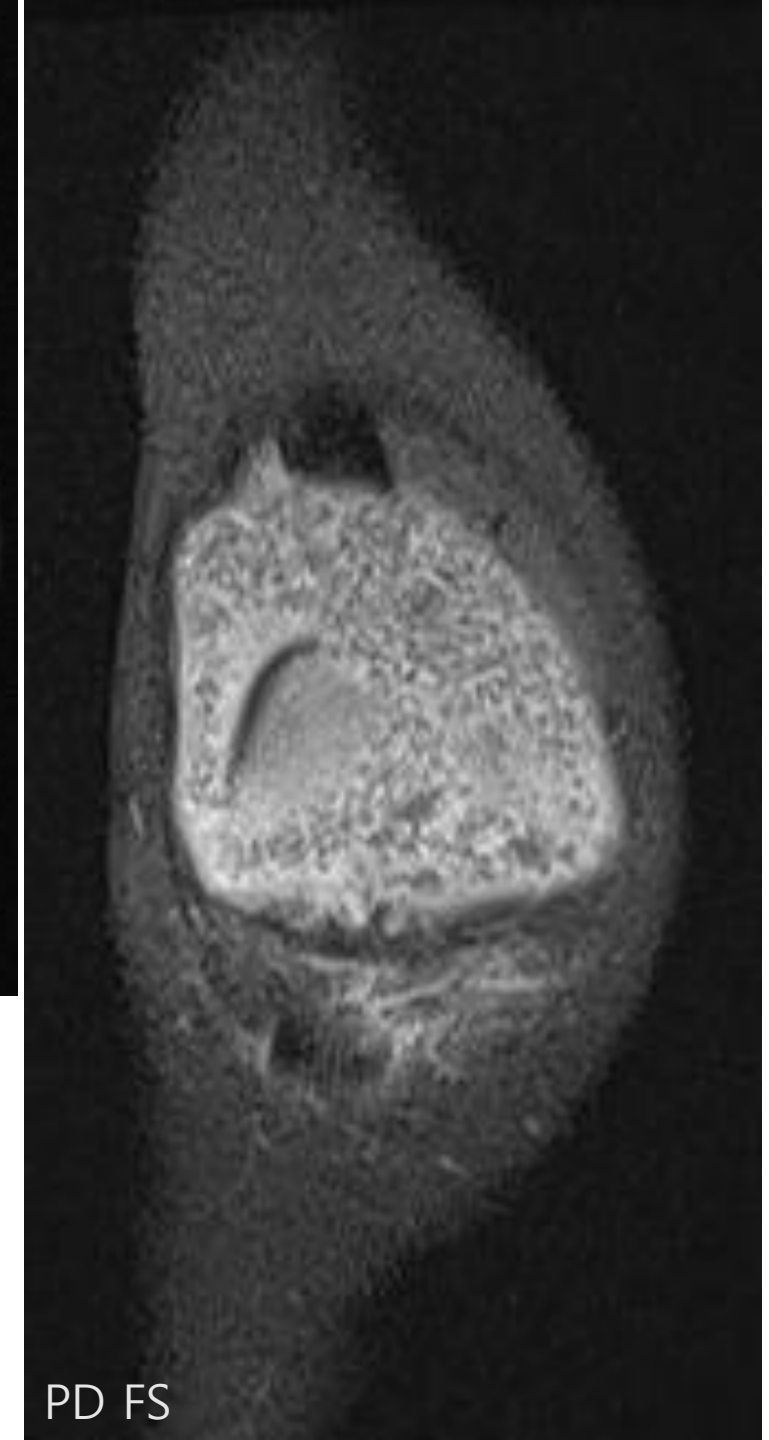




T2 TSE



GRE T2\*



PD FS



