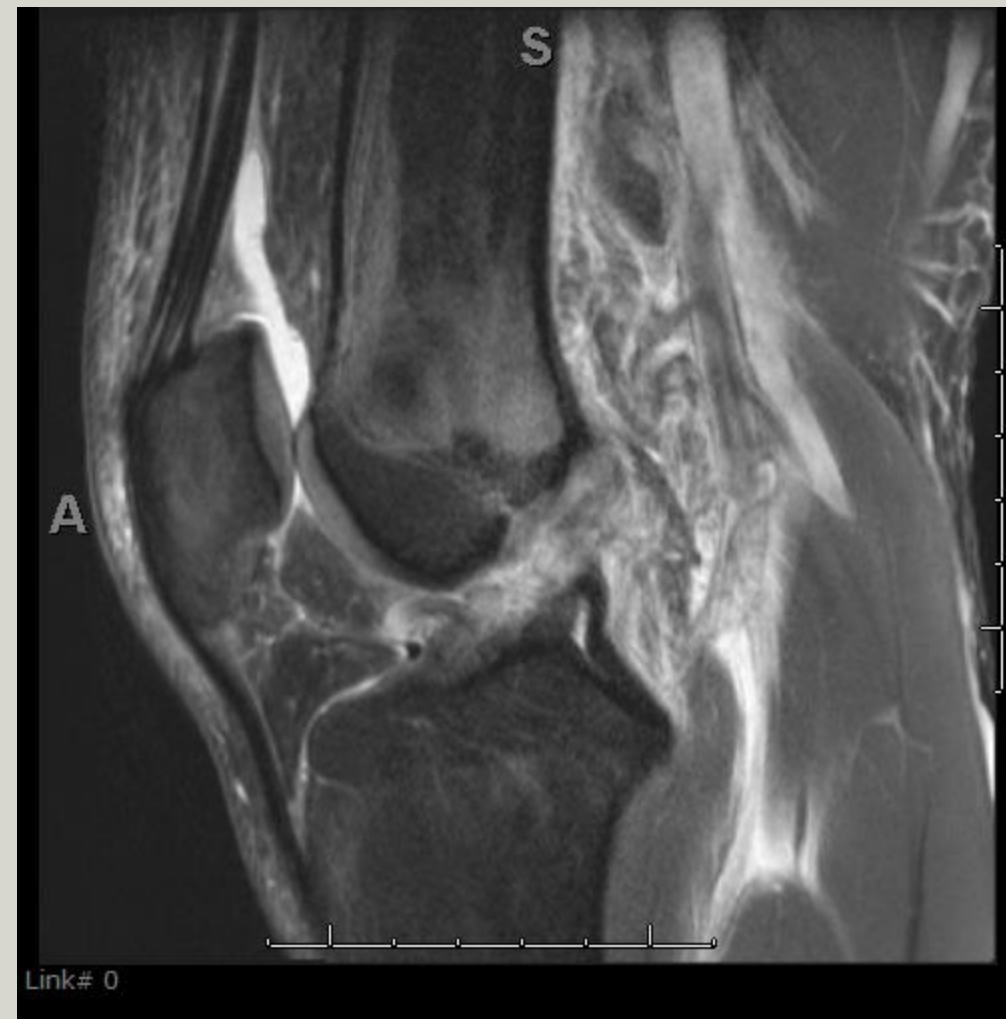
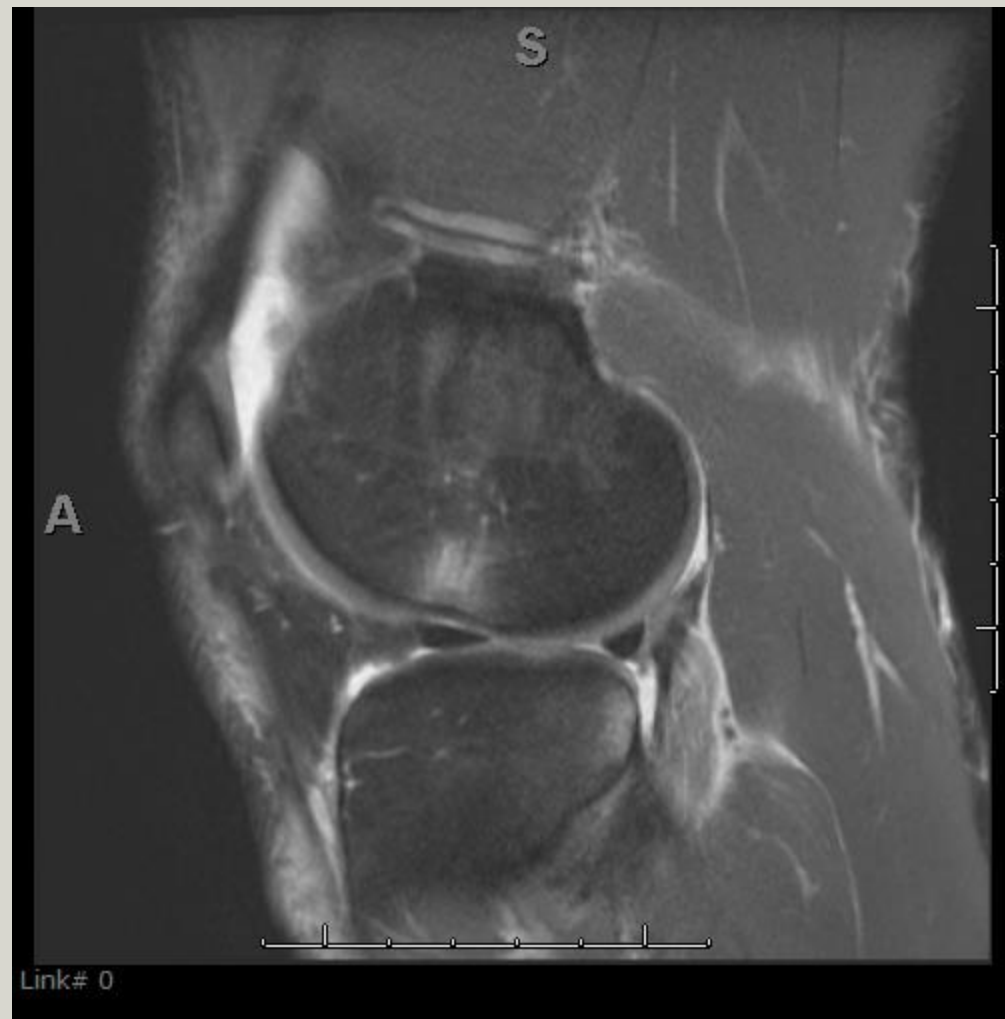
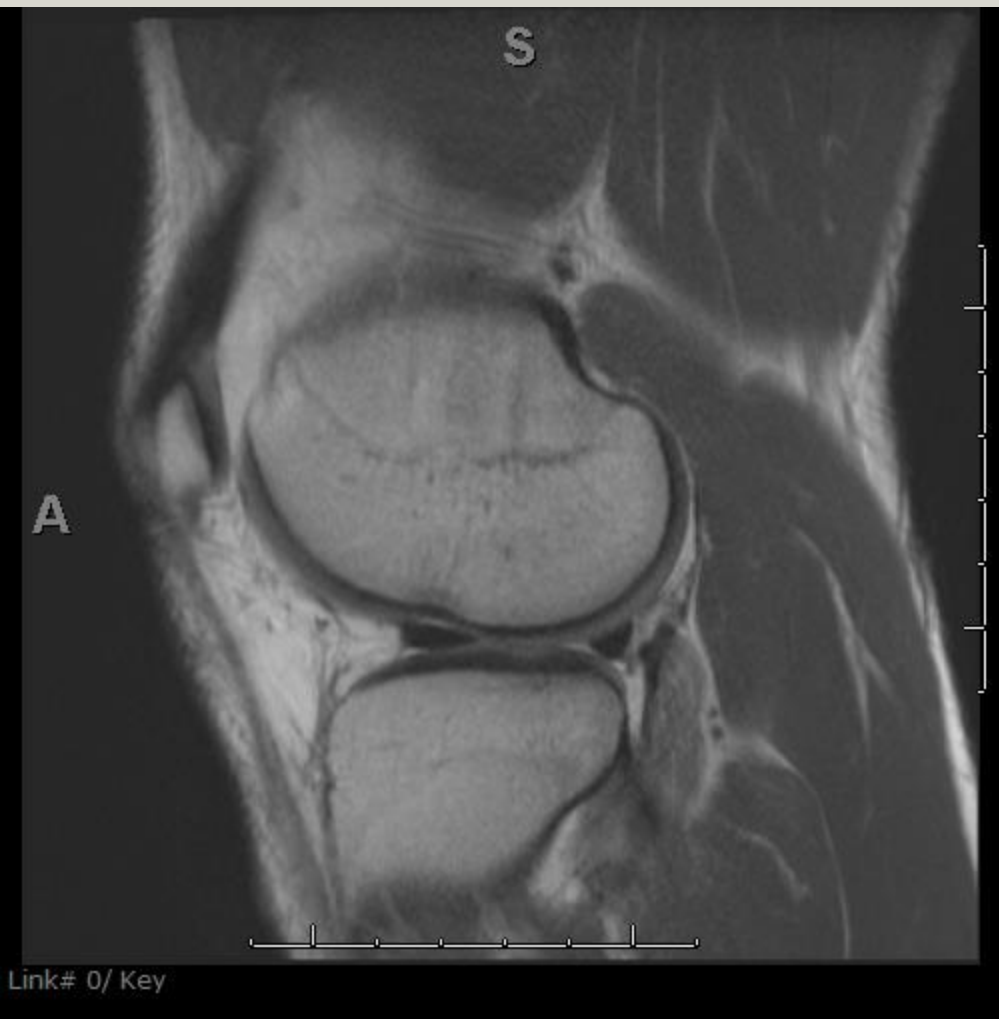

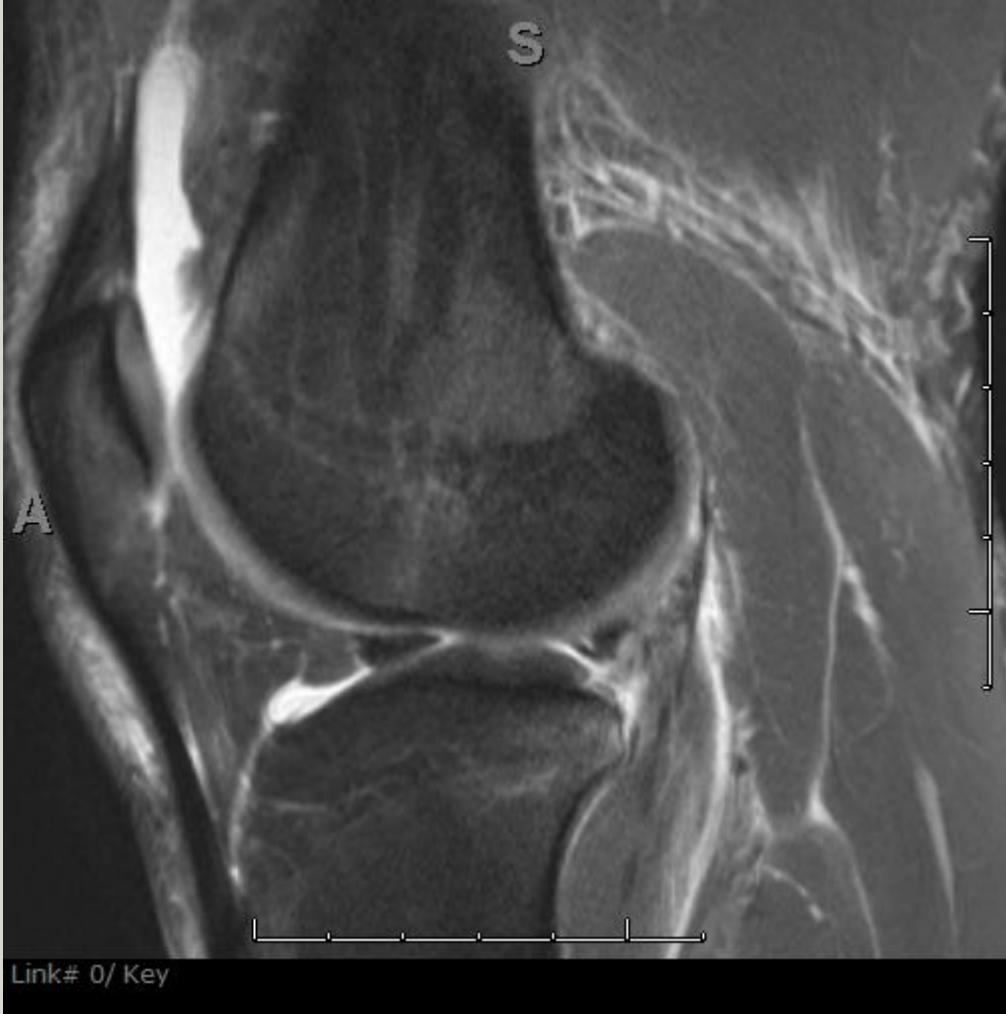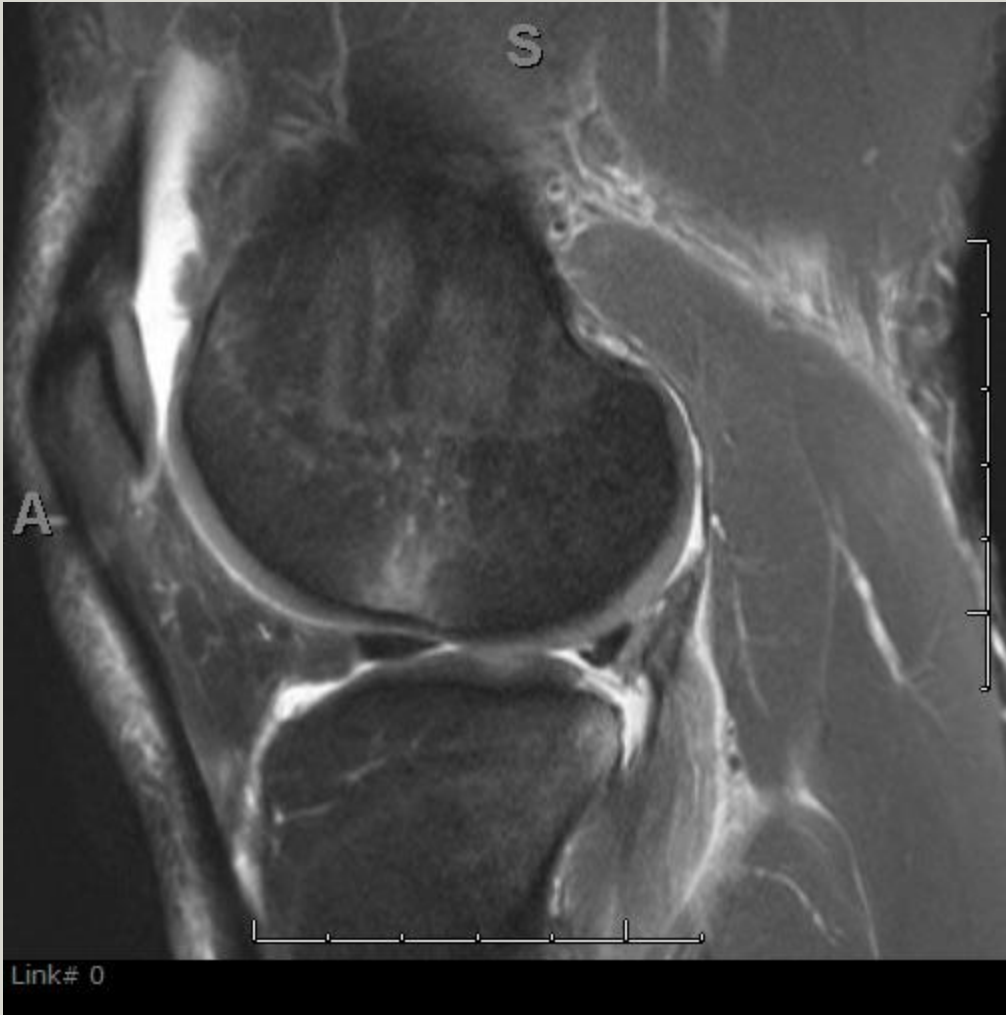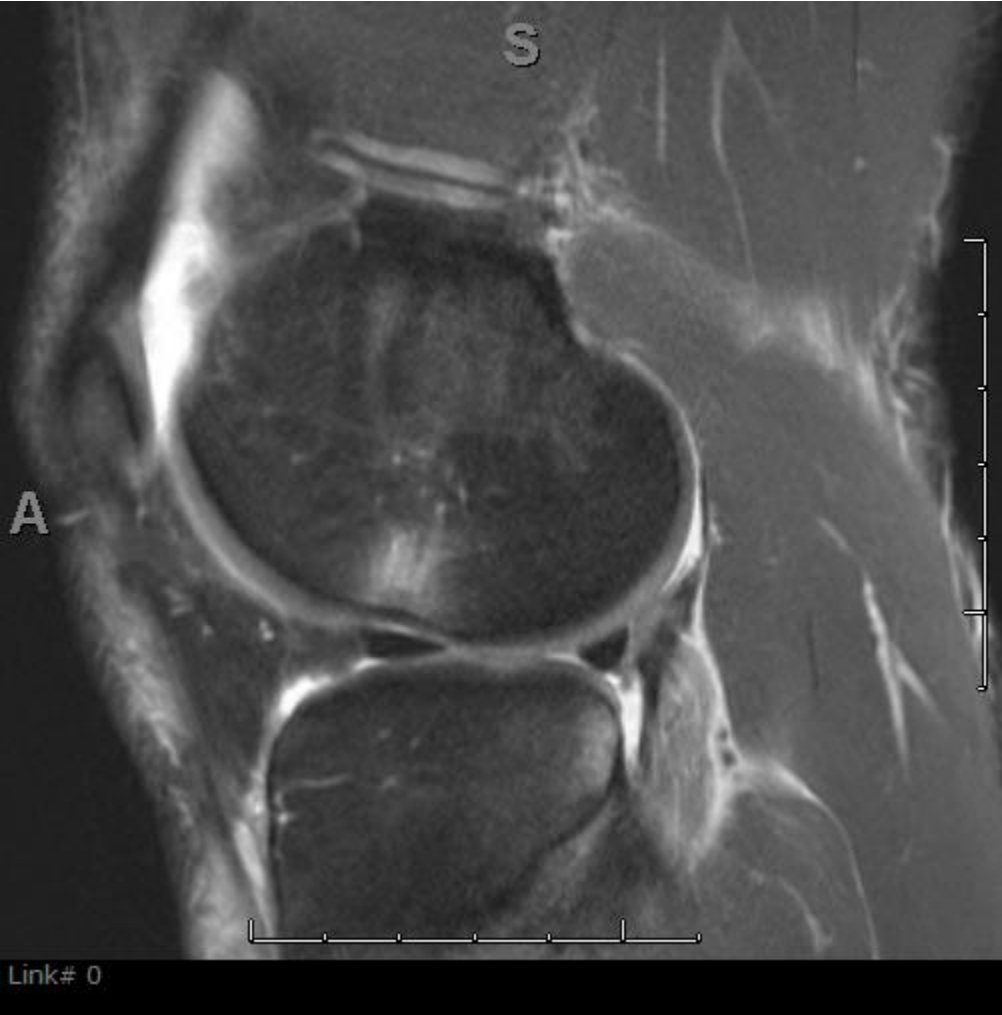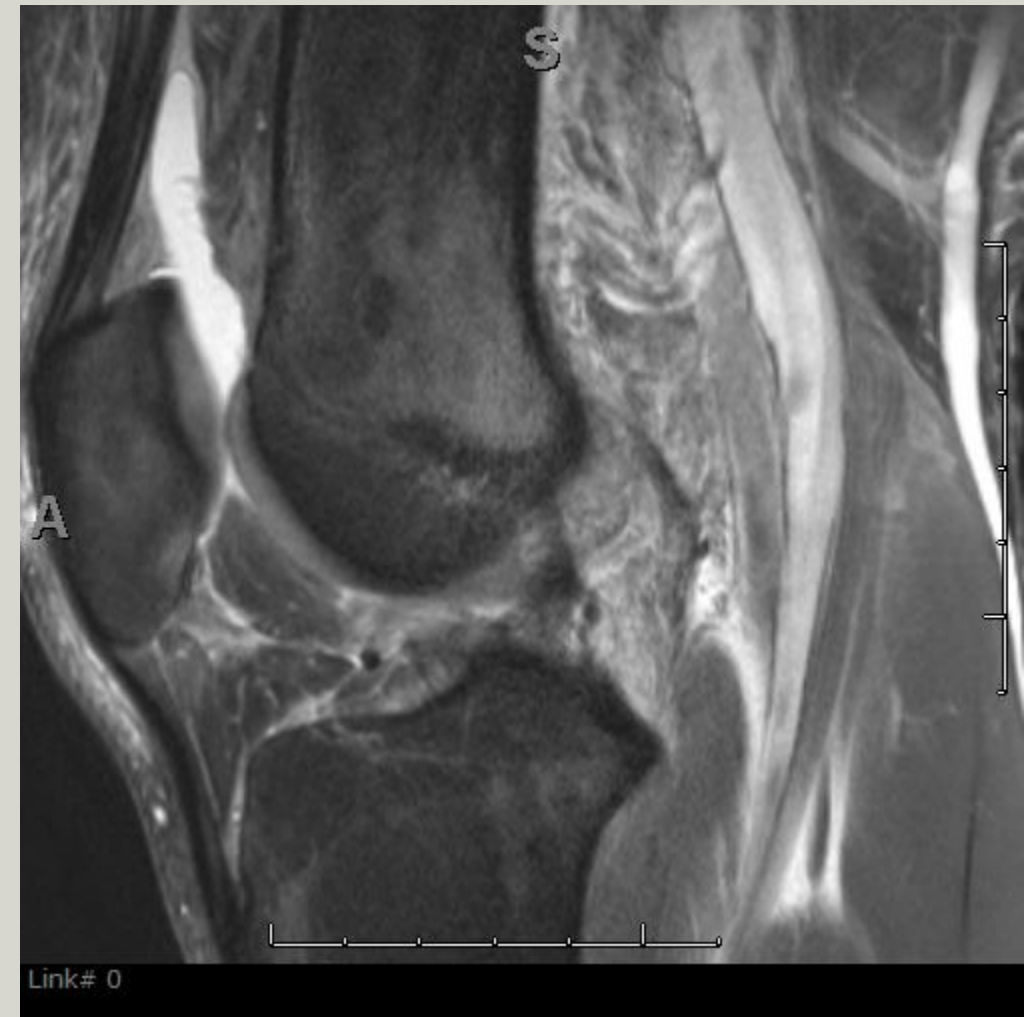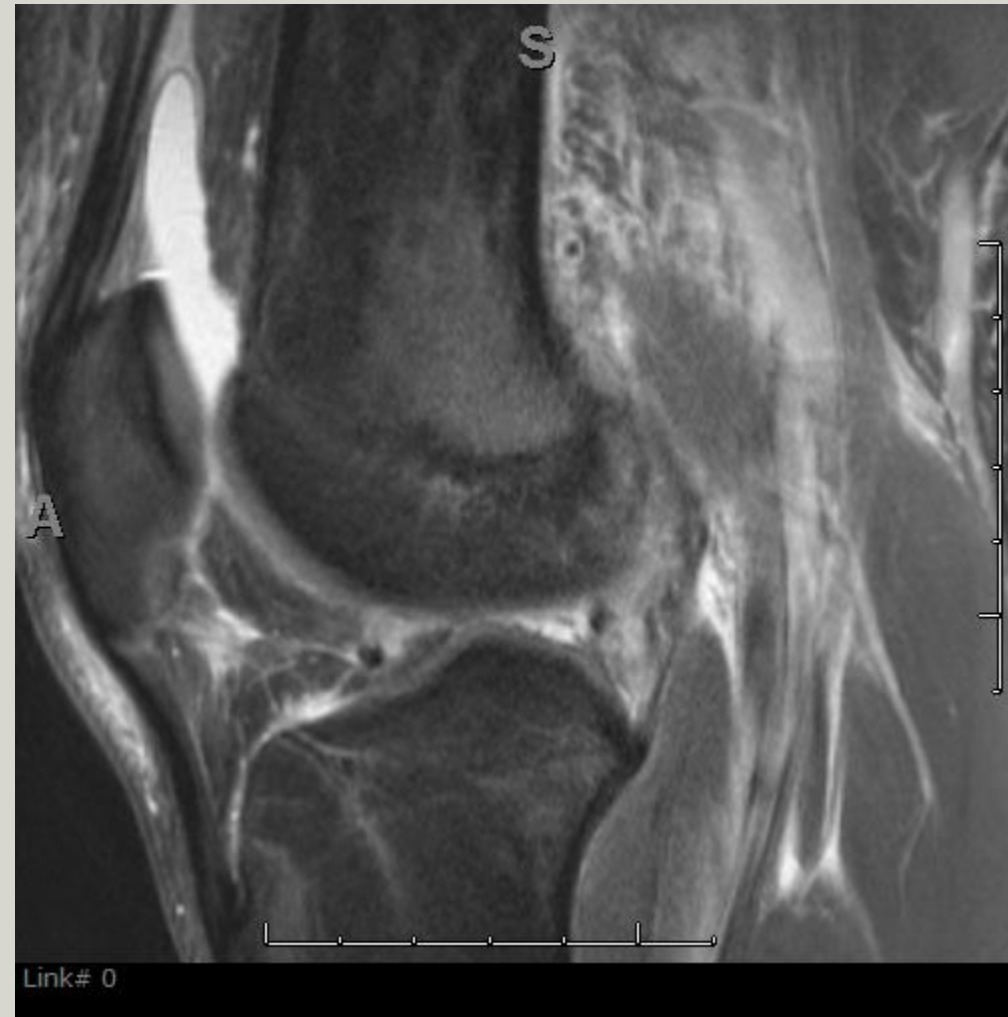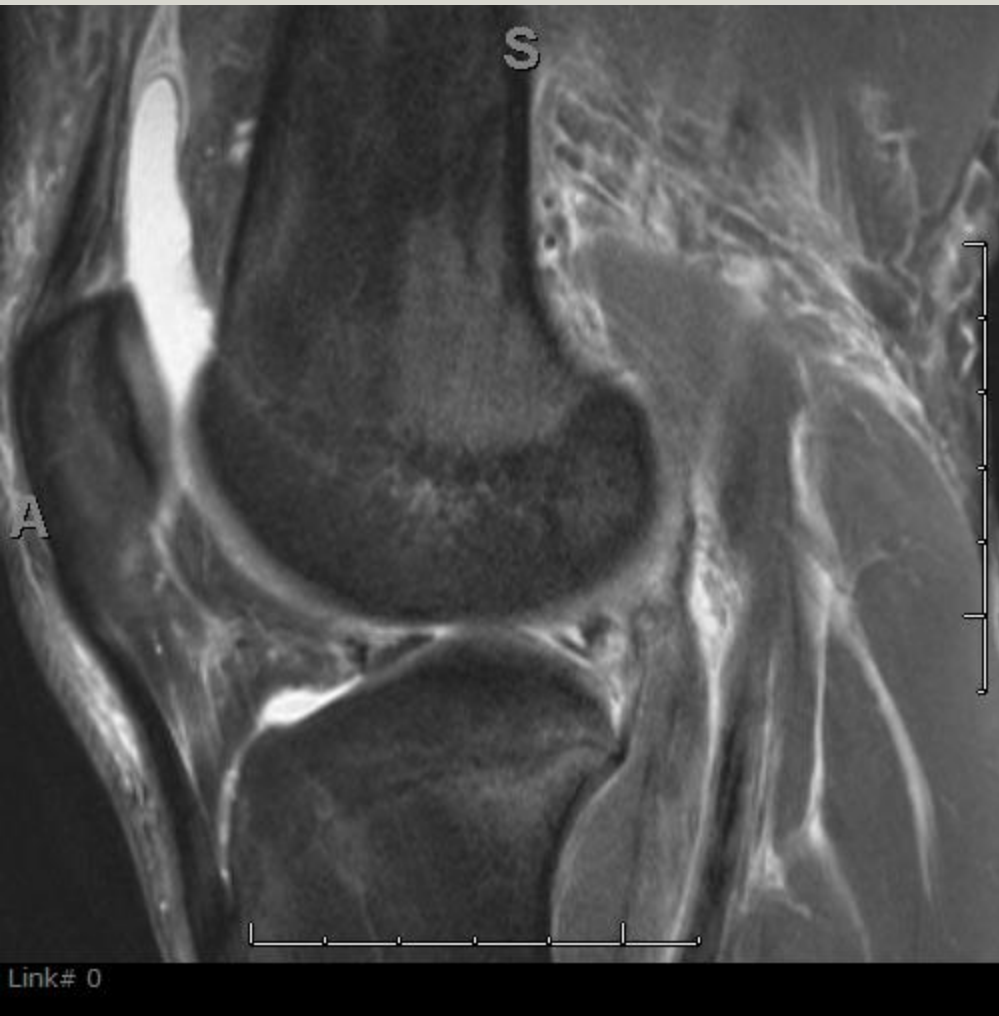Young man with ACL injury

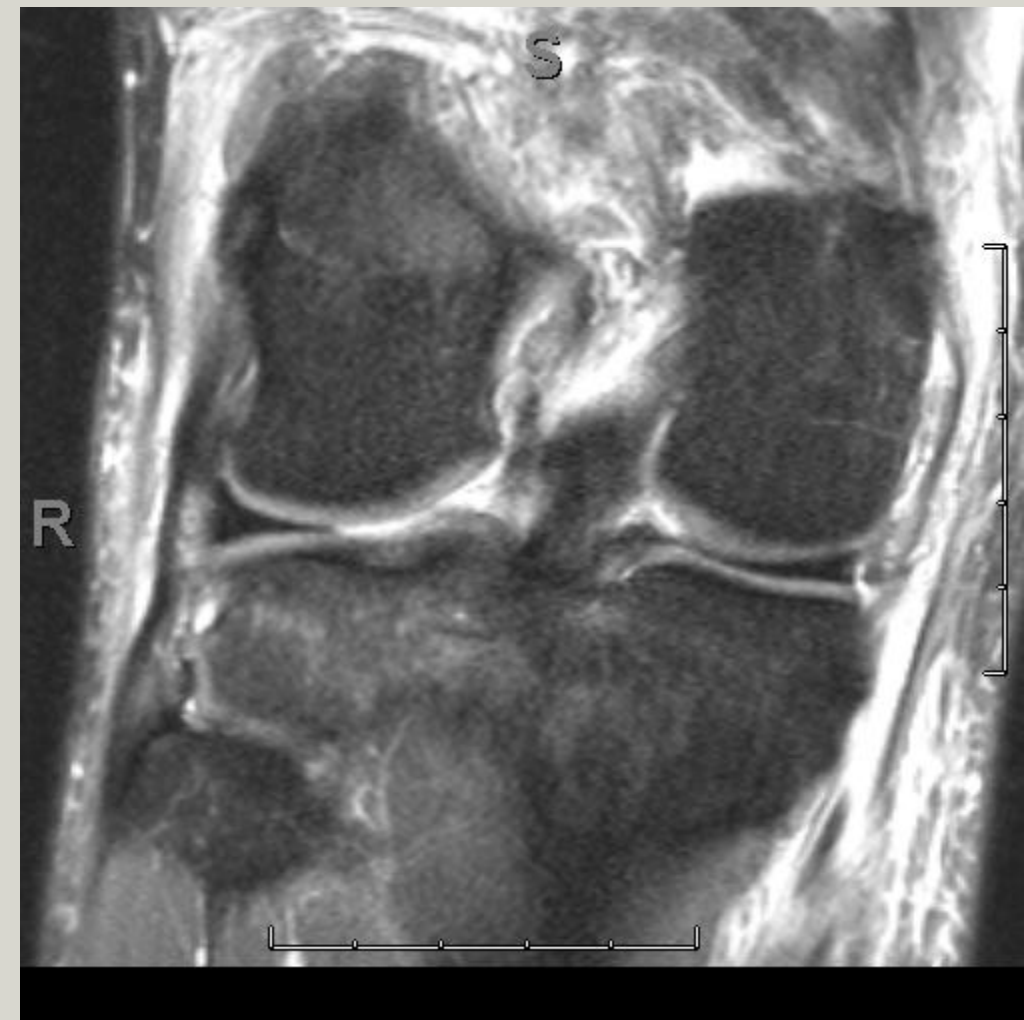
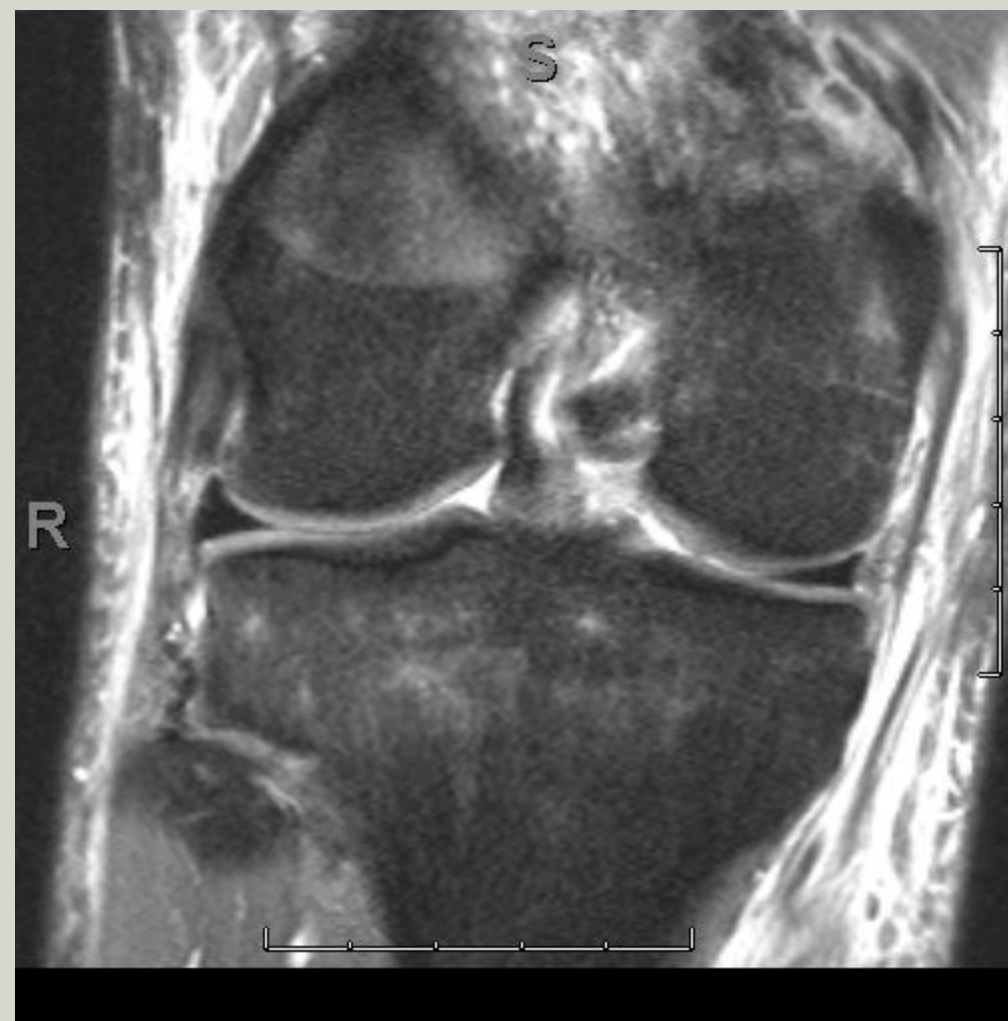
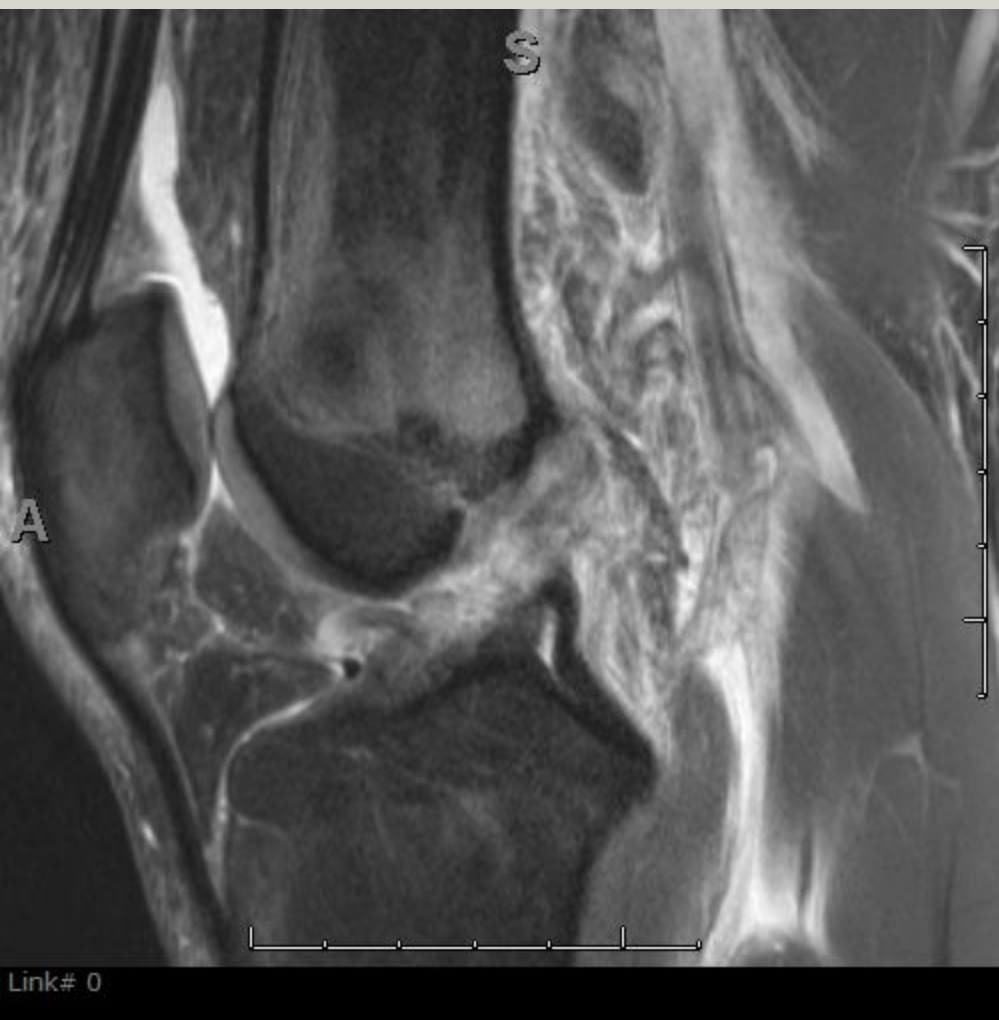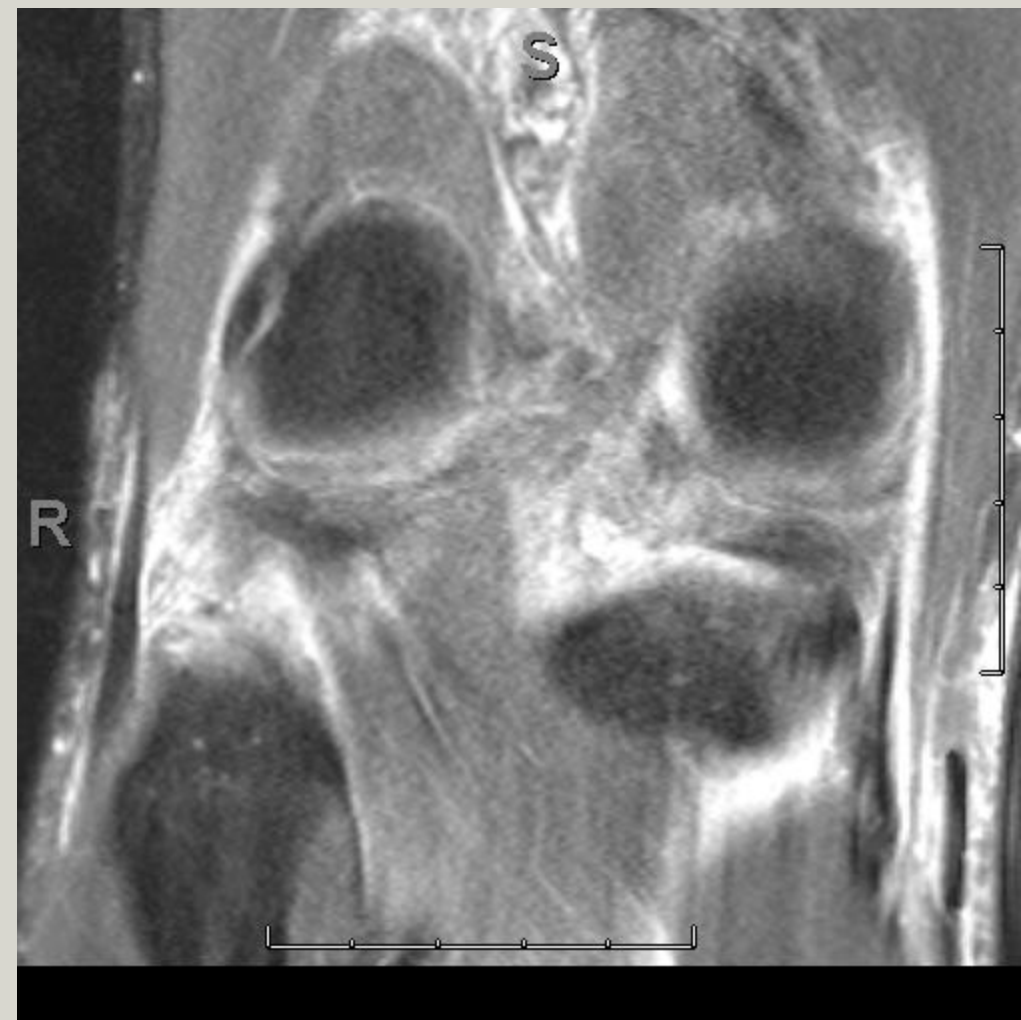


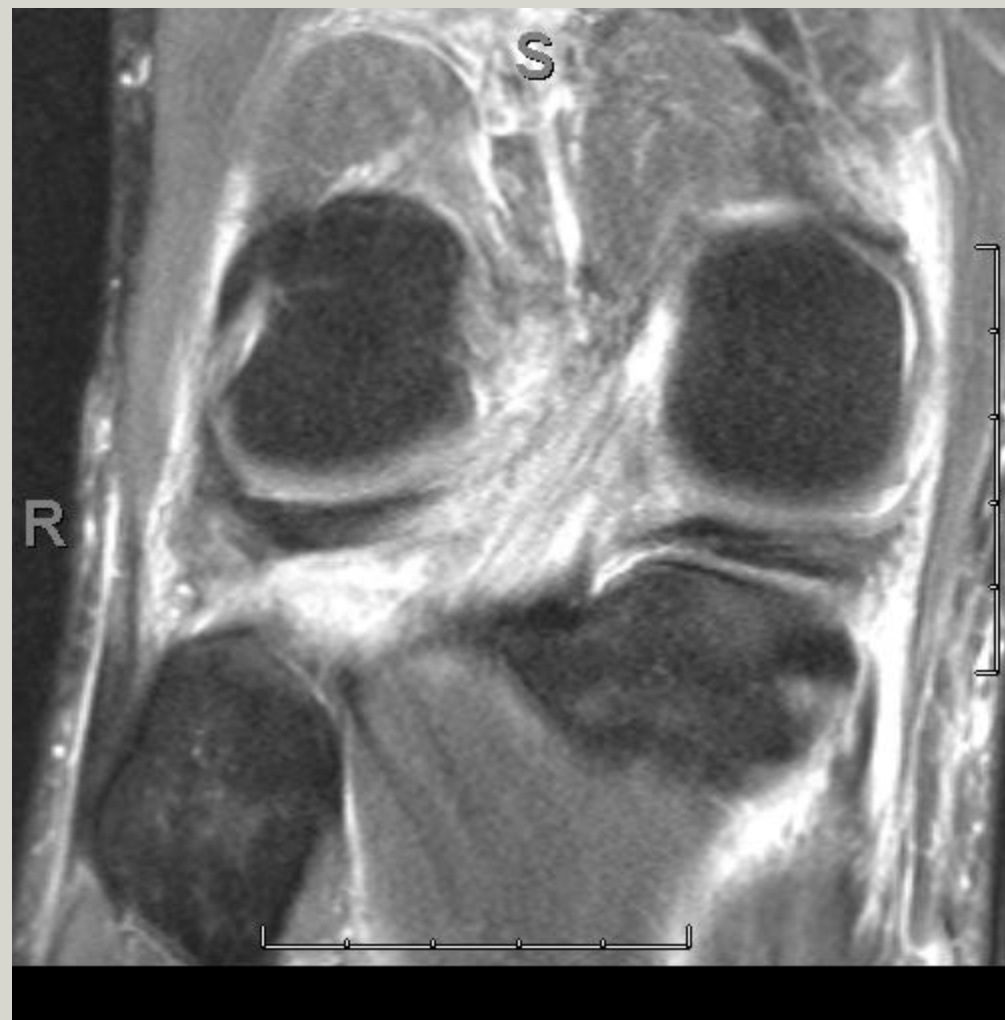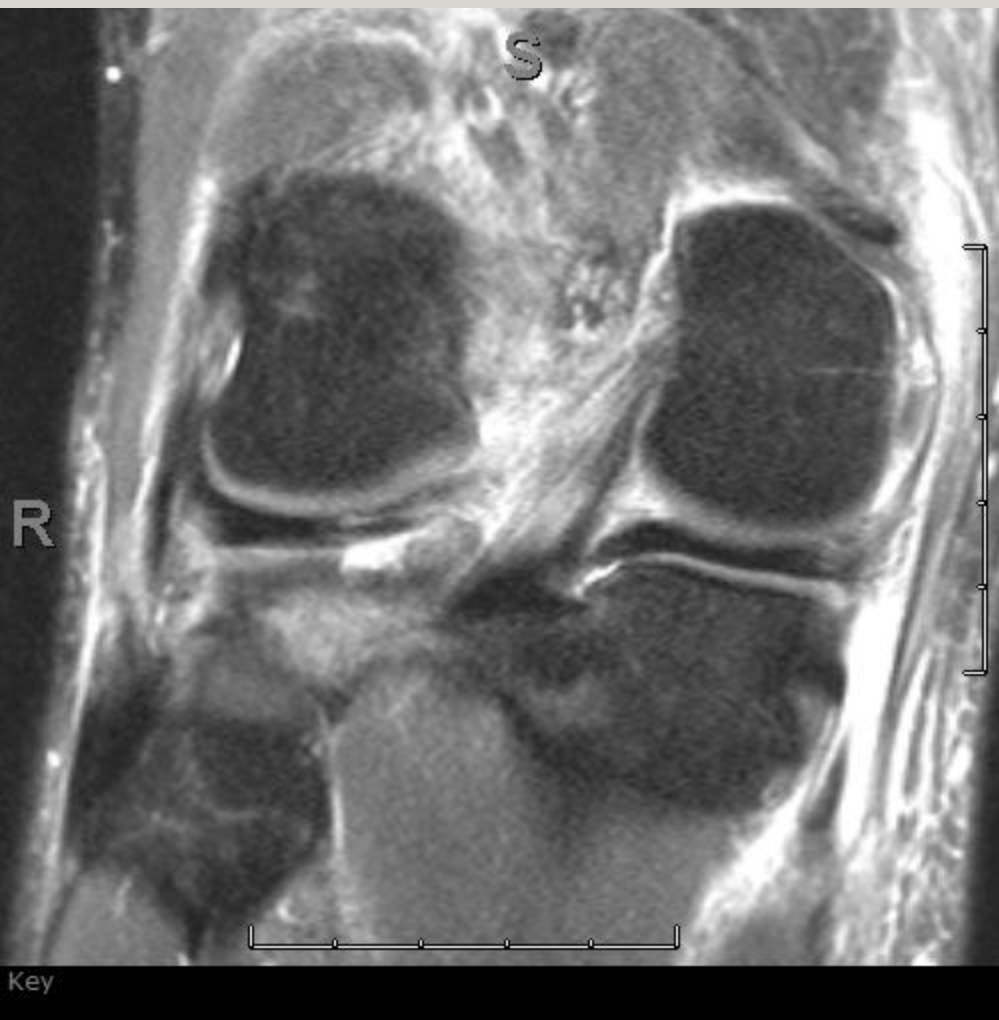Watch the lateral meniscus



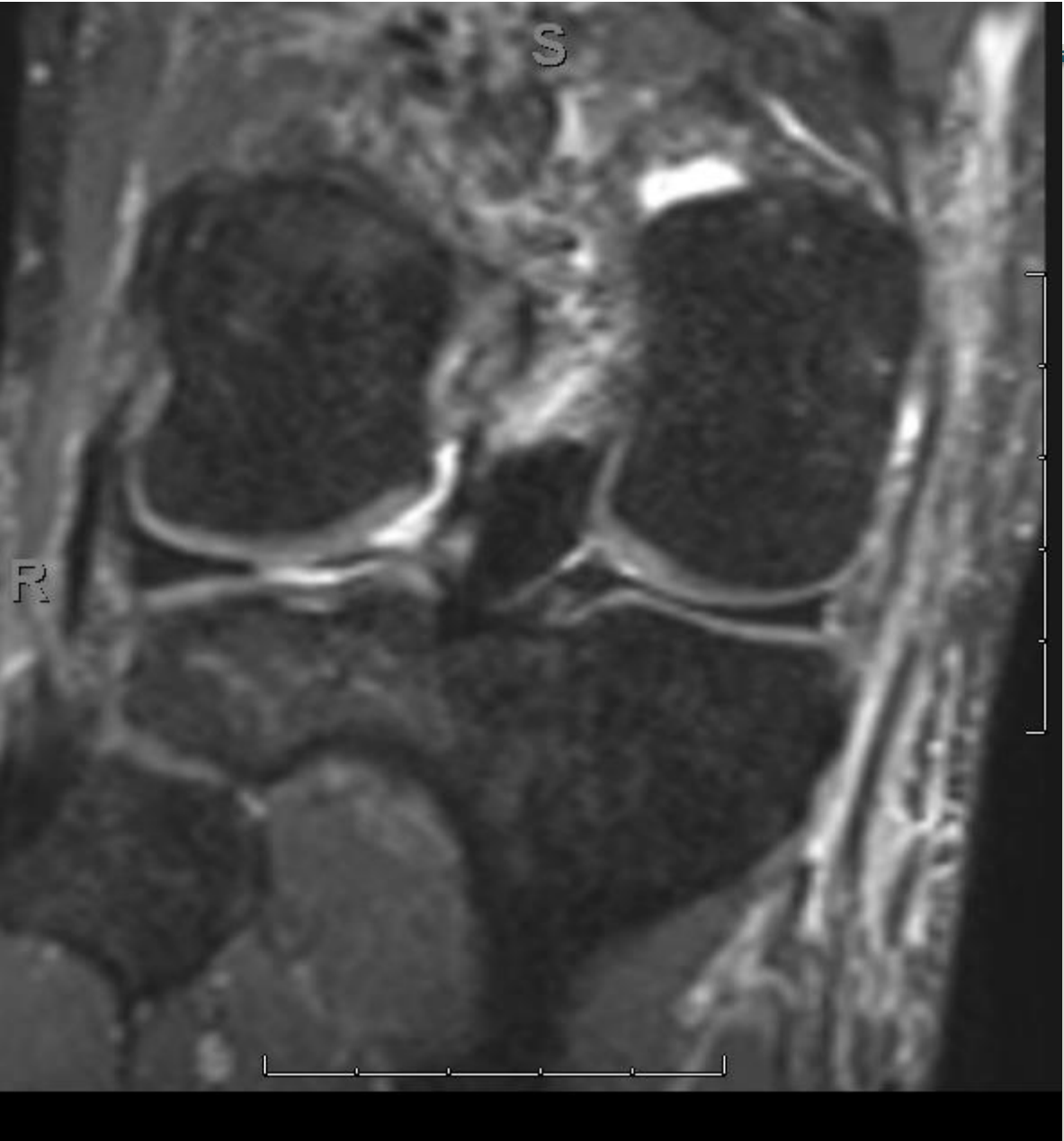
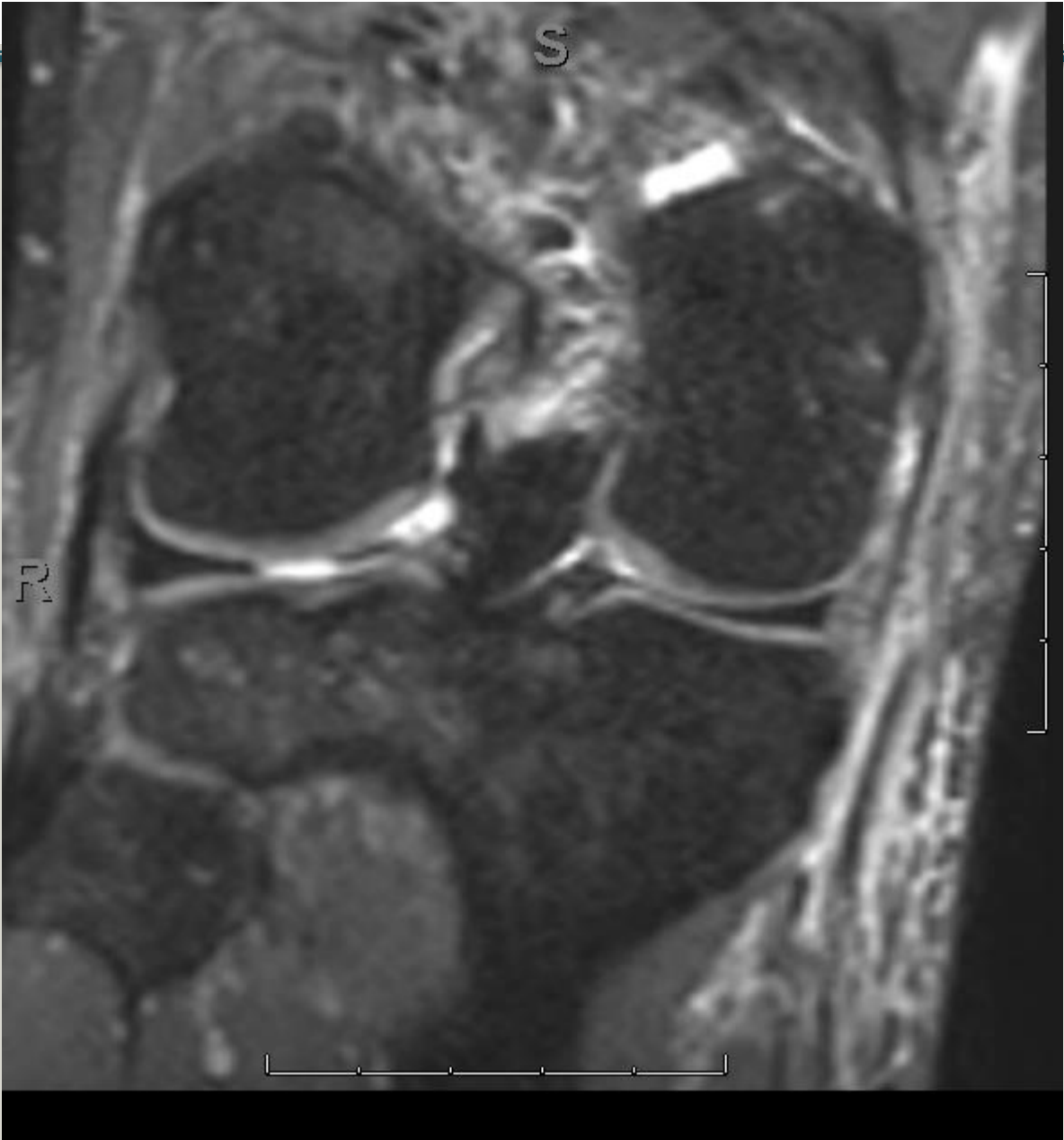


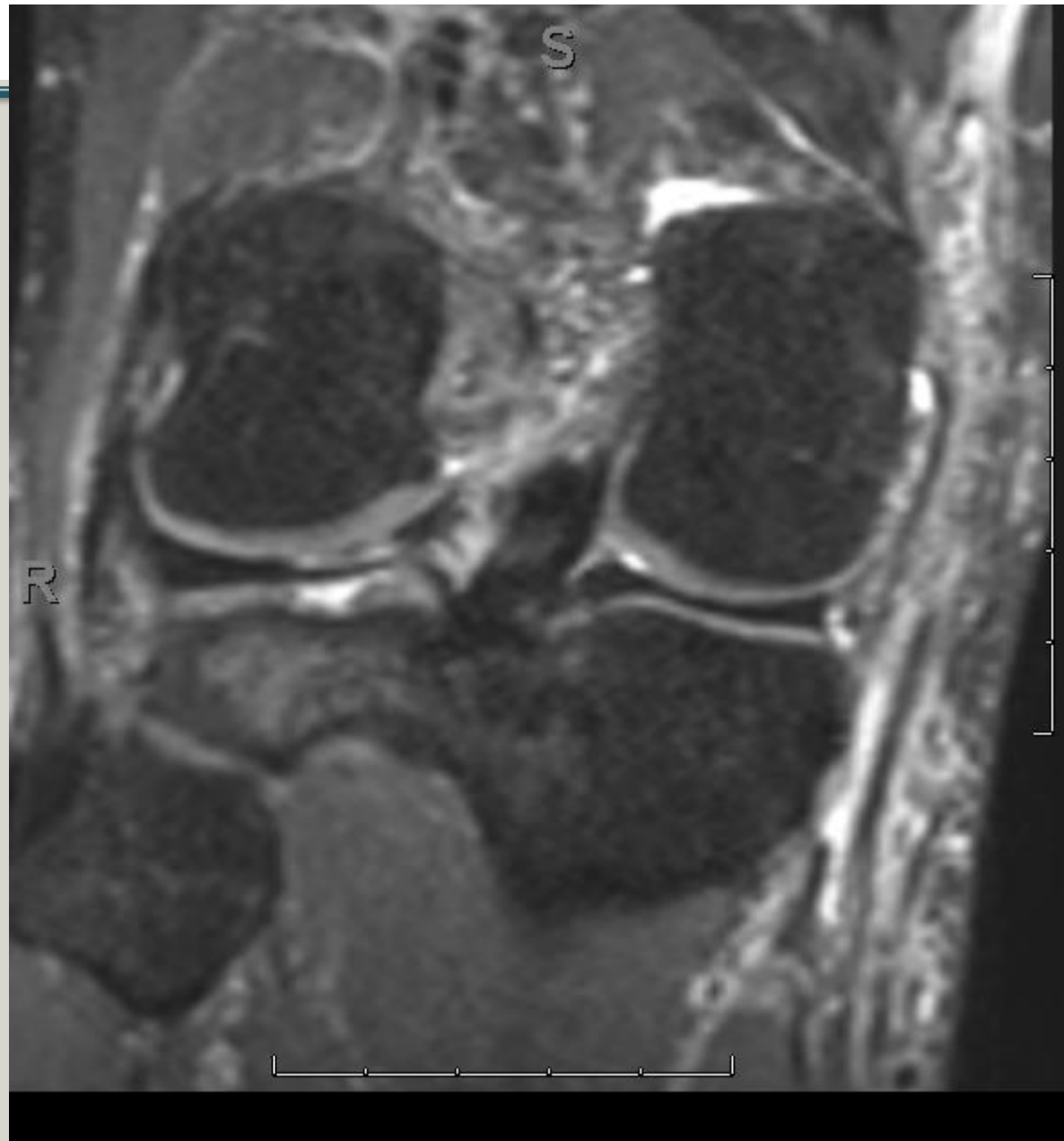
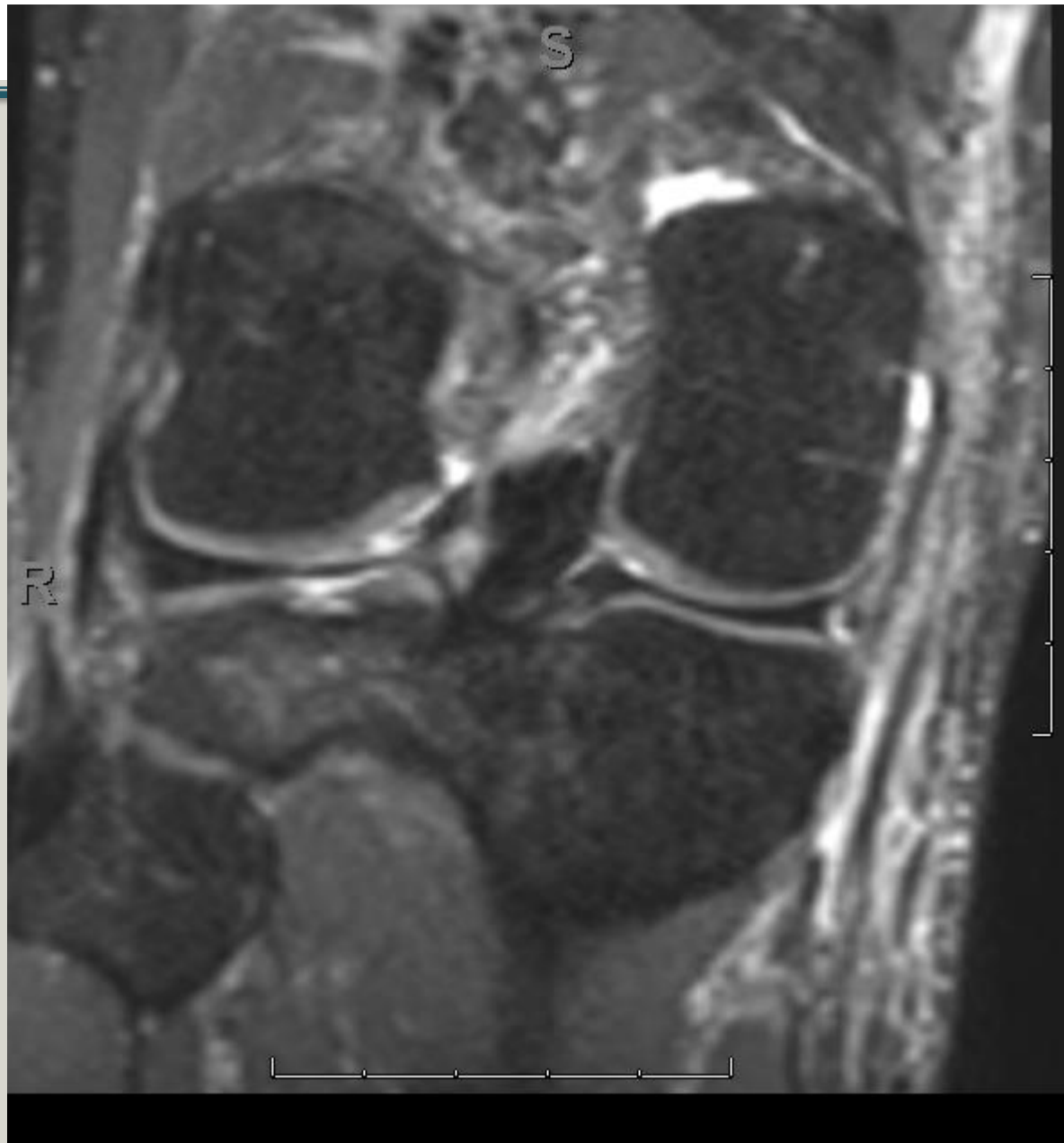

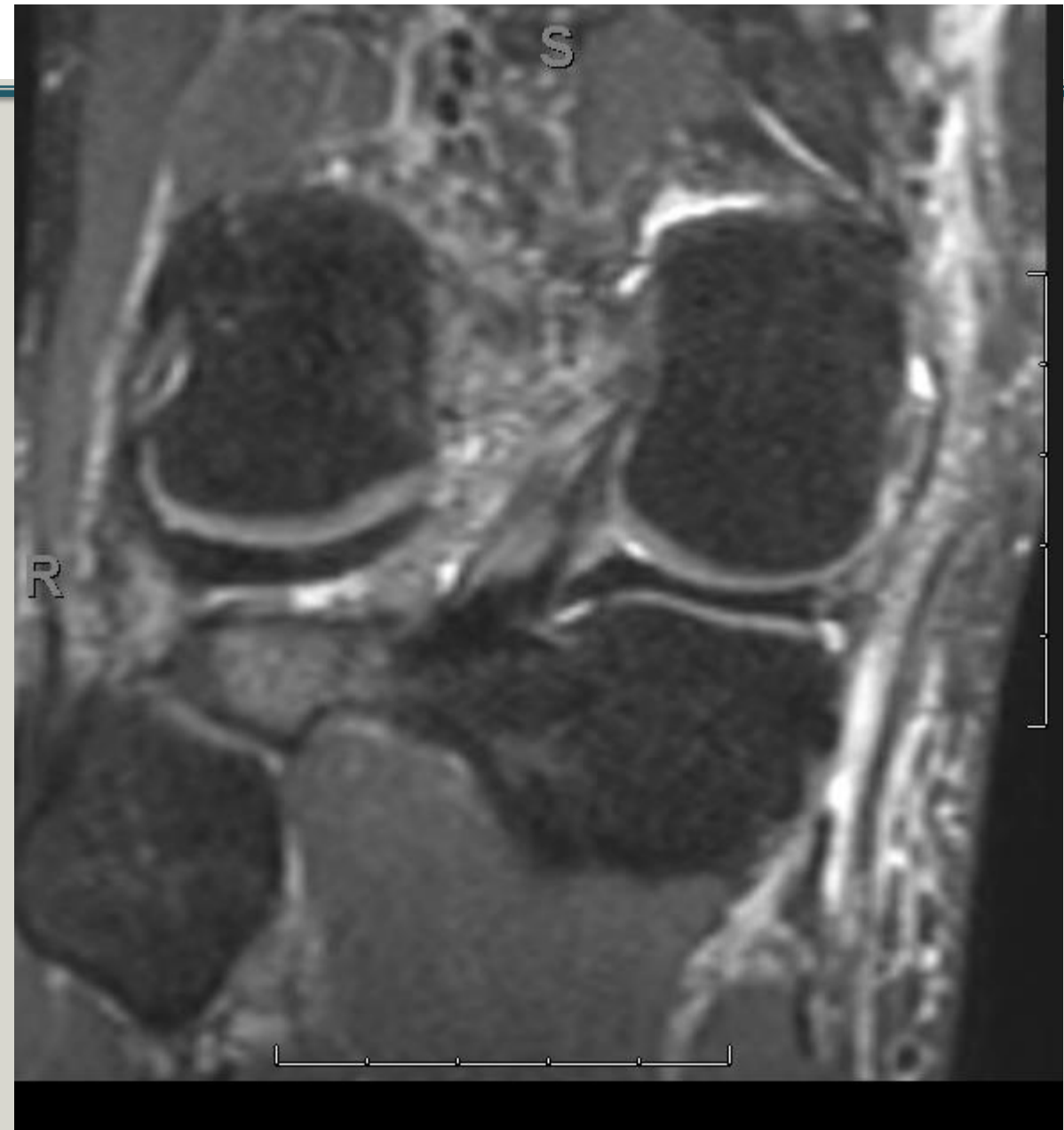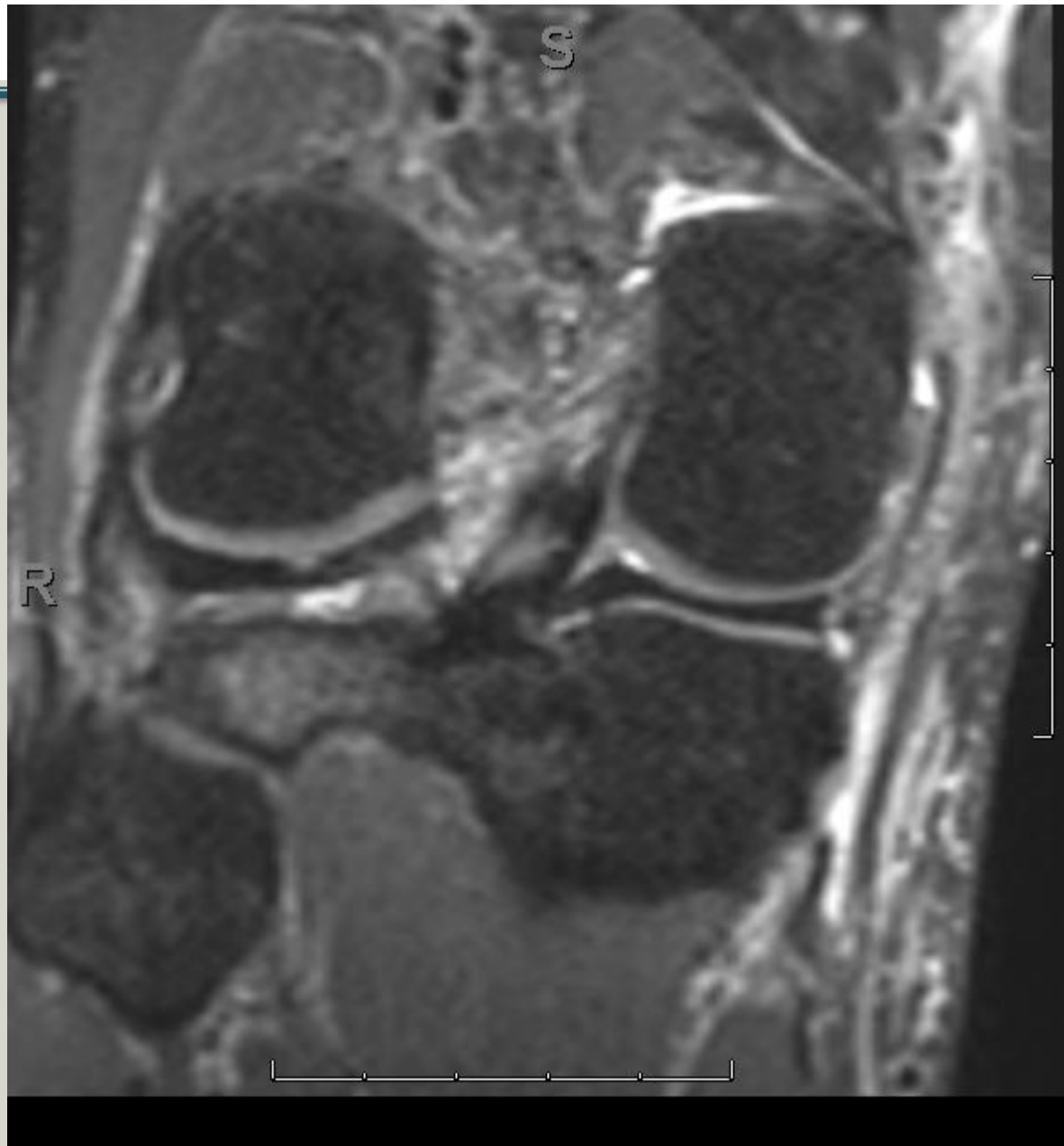


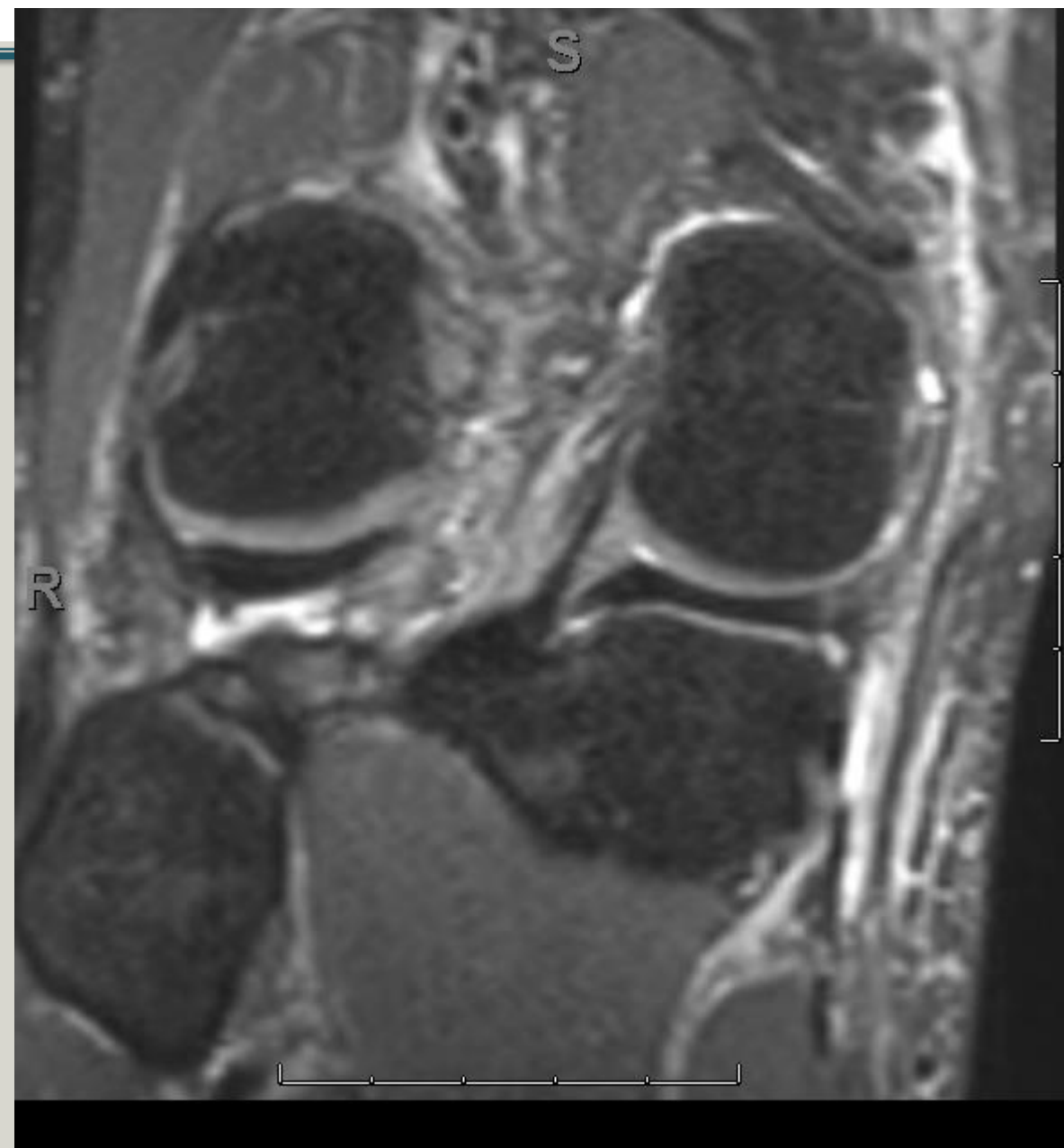
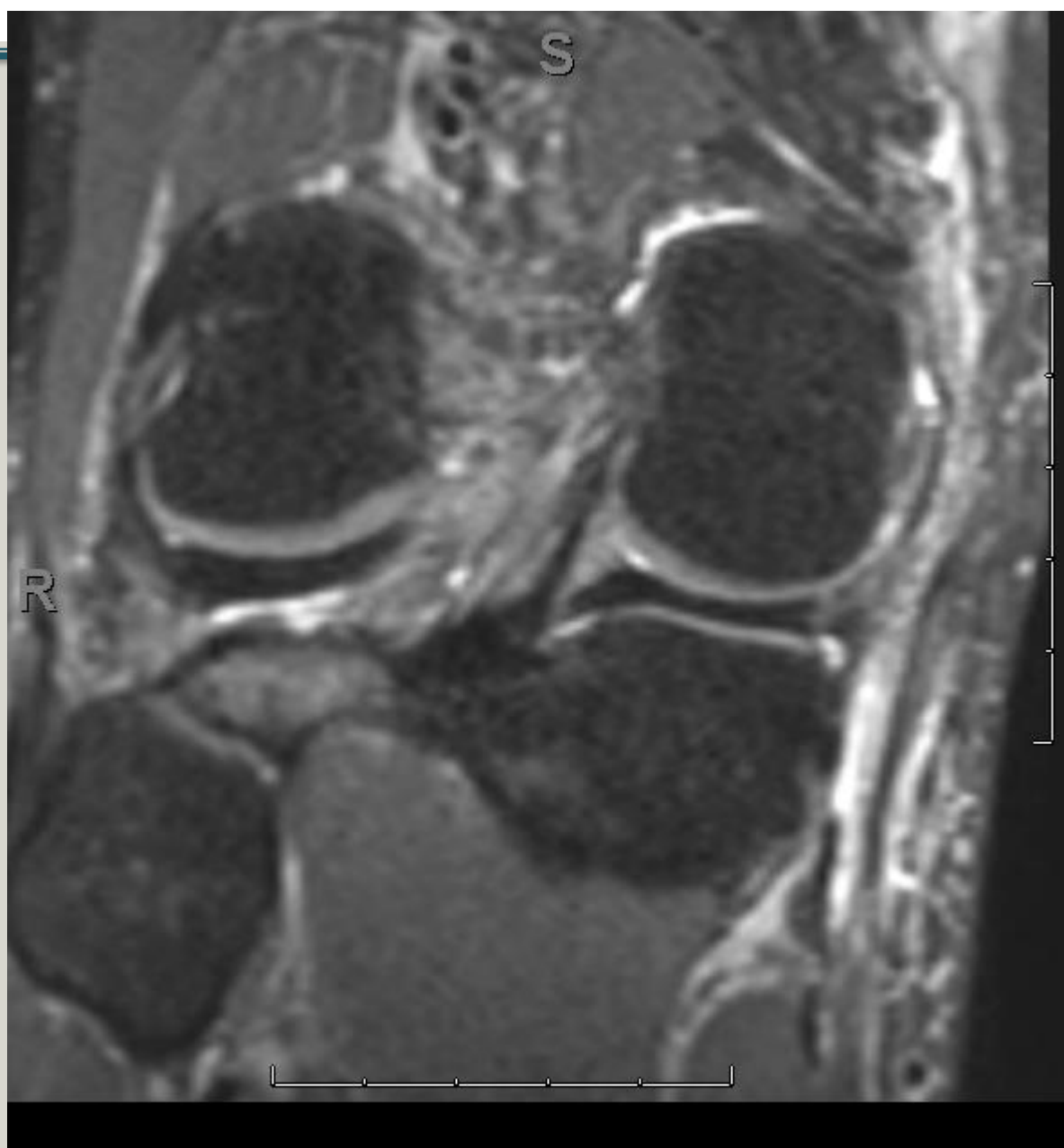
- Torn or not torn?
- Superior surface or under surface?
- How big?
- Which Laprade type?

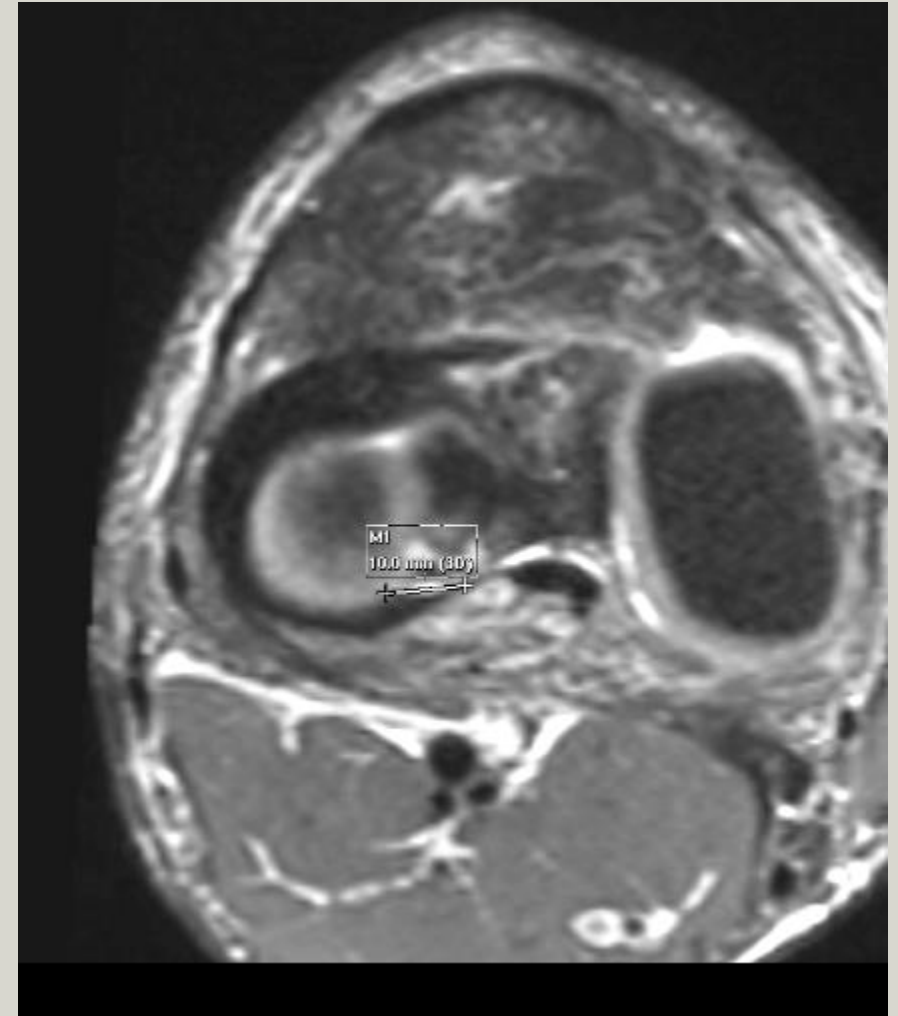
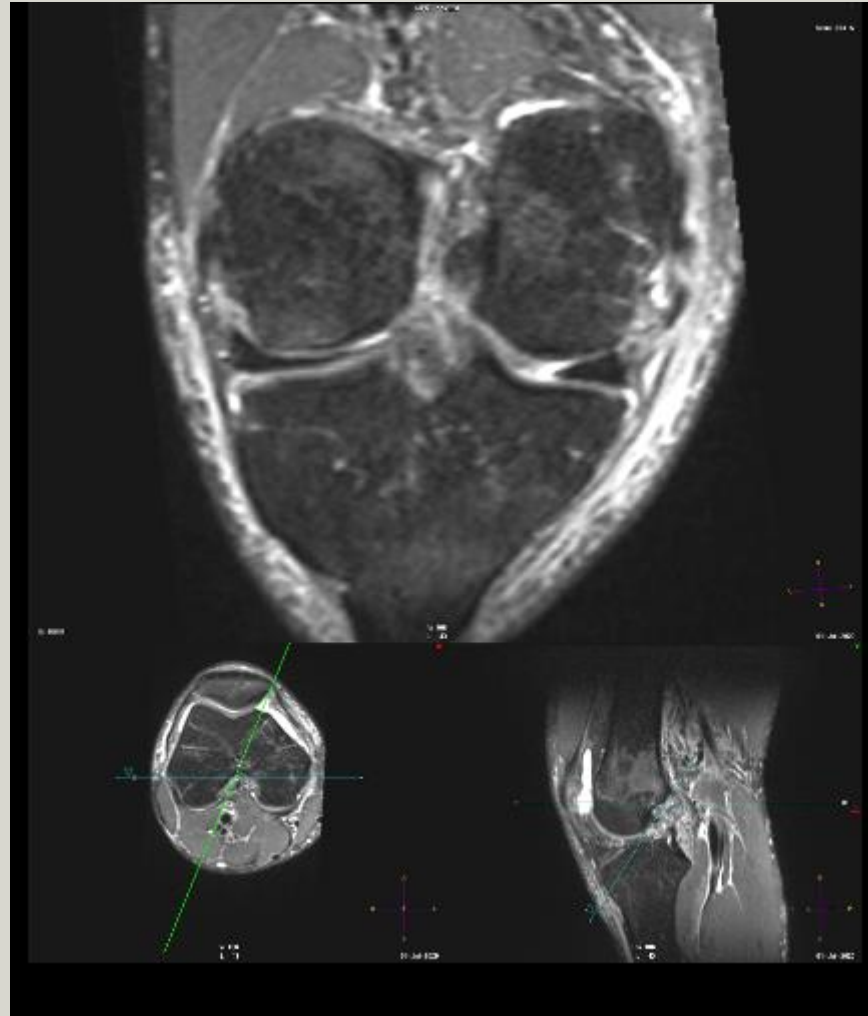
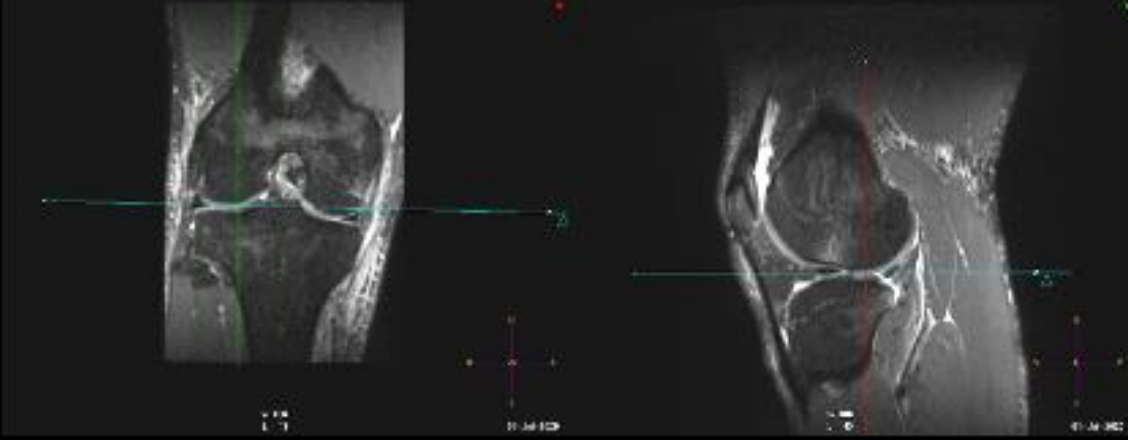
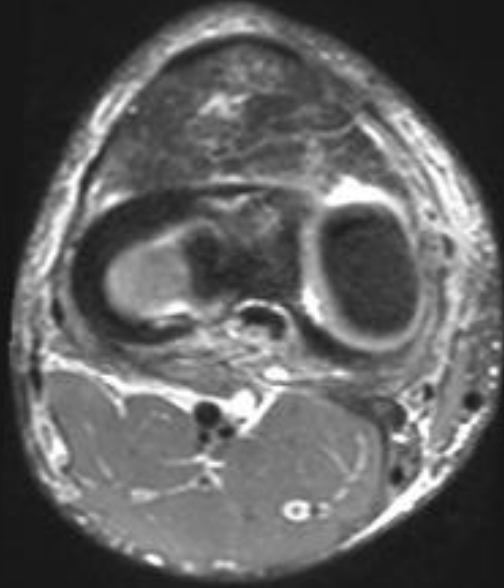
3D



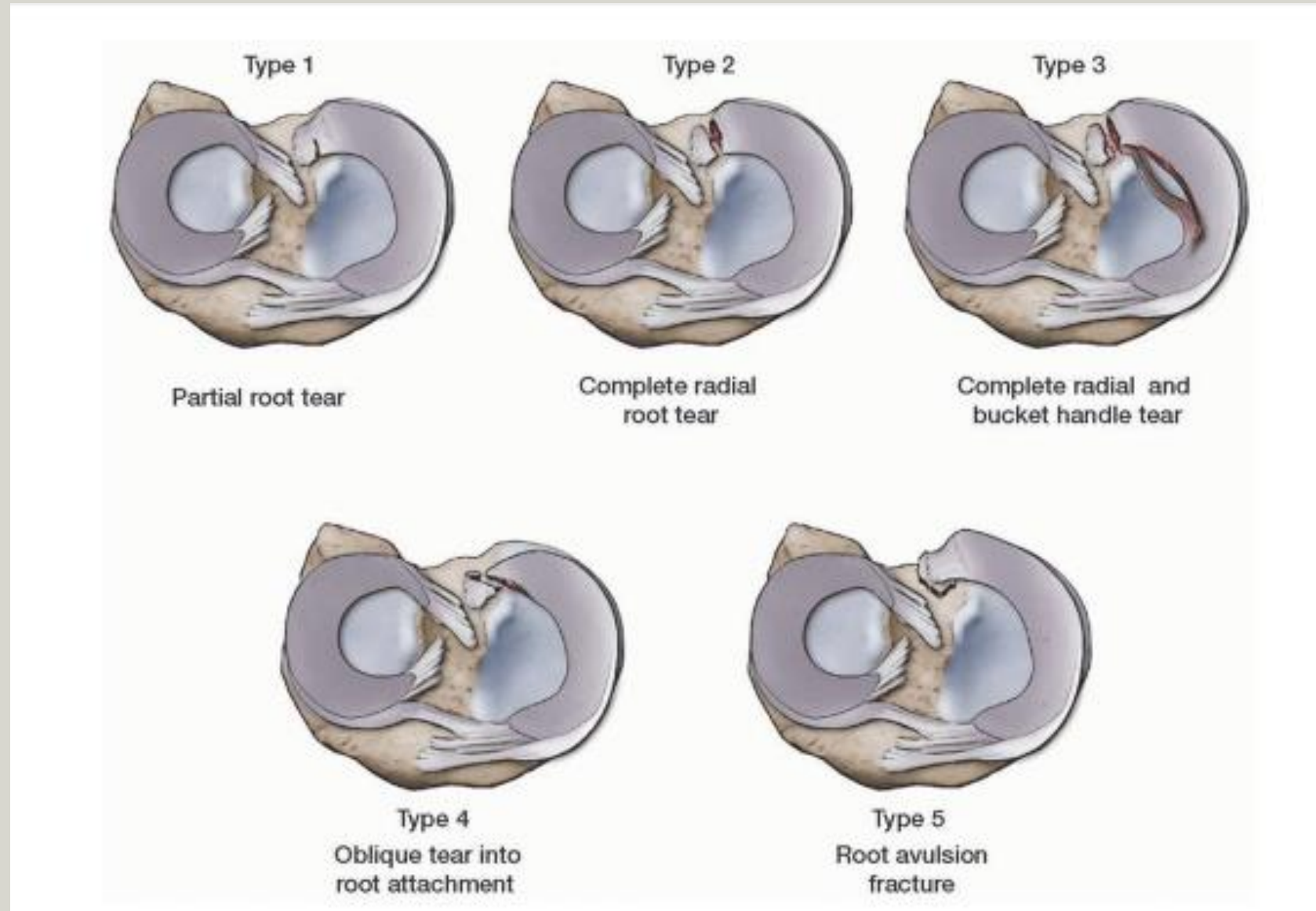








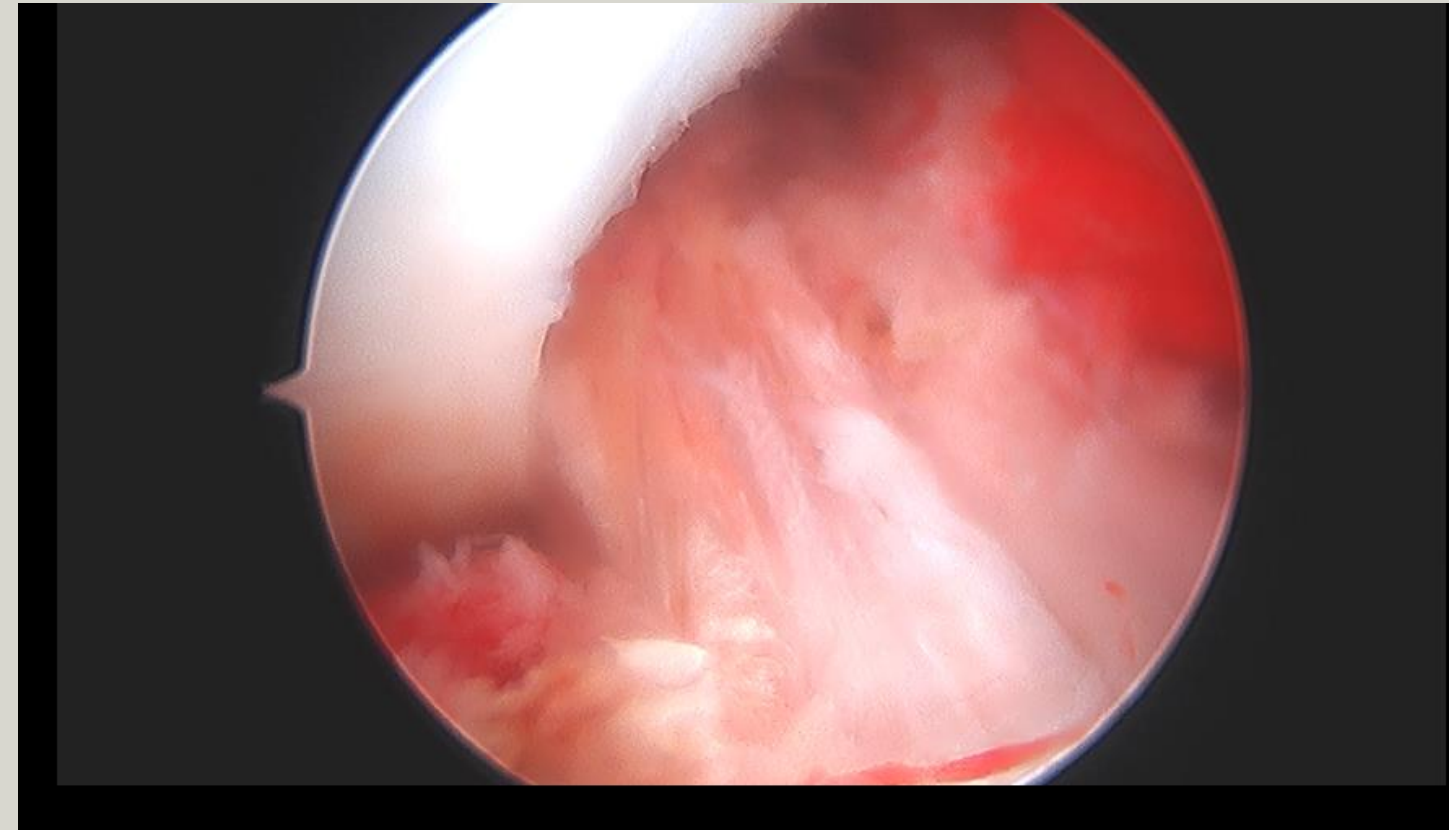
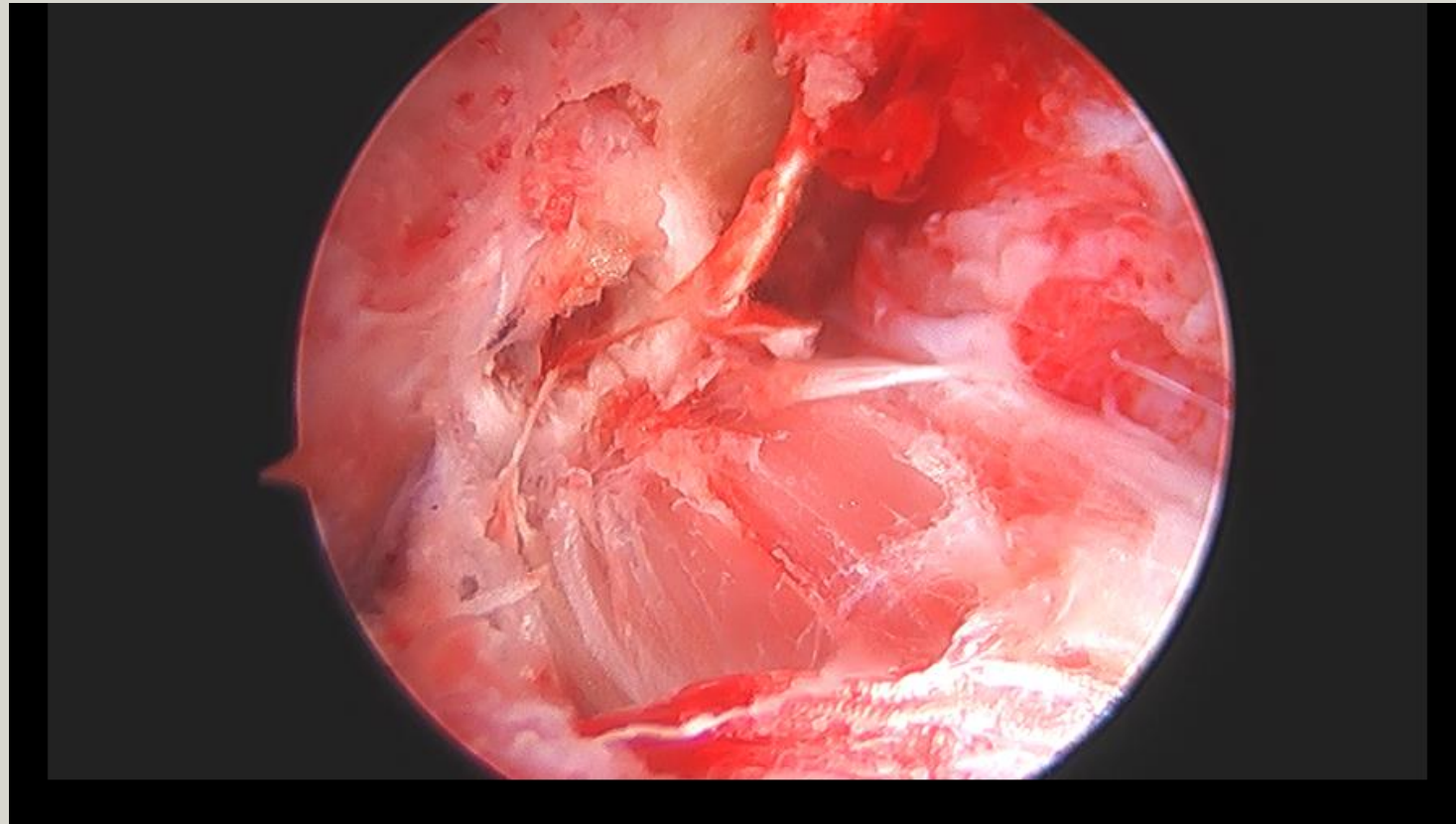
Laprade Classification



ISACOS and Laprade

- Tear: complete lateral slip; zone one, two, three,
- Radial location: Posterior horn and lateral slip root involvement
- Not central to popliteus hiatus.
- Pattern is radial
- Meniscal tissue is nondegenerative.
- Tear length: 10 mm.
- Laprade: Type IV

Arthroscopy- ACL before and after



Join us for 3D session on meniscal and labral injuries

Date Time: Aug 23, 2020 ; Sunday- 830am CT USA

Topic: REF - Cafe Roentgen - Sunday Webinar #108 - 3D Imaging of knee and hip- meniscal and labral tear characterization and measurements - Dr. Avneesh Chhabra

Join from a PC, Mac, iPad, iPhone or Android device:

[Click Here to Join](#)

Note: This link should not be shared with others; it is unique to you.

Passcode: 361418

[Add to Calendar](#) [Add to Google Calendar](#) [Add to Yahoo Calendar](#)

Or iPhone one-tap:

US: +12532158782,,81670920558# or +13017158592,,81670920558#

Or Telephone:

Dial(for higher quality, dial a number based on your current location):

US: +1 253 215 8782 or +1 301 715 8592 or +1 312 626 6799 or +1 346 248 7799 or +1 646 558 8656 or +1 669 900 9128

Webinar ID: 816 7092 0558

Participant ID: 337387

Passcode: 361418

International numbers available: <https://us02web.zoom.us/j/kdlxvWW8p>

Arthroscopy- LM confirmed- undersurface- Laprade IV, 9mm, lateral slip

