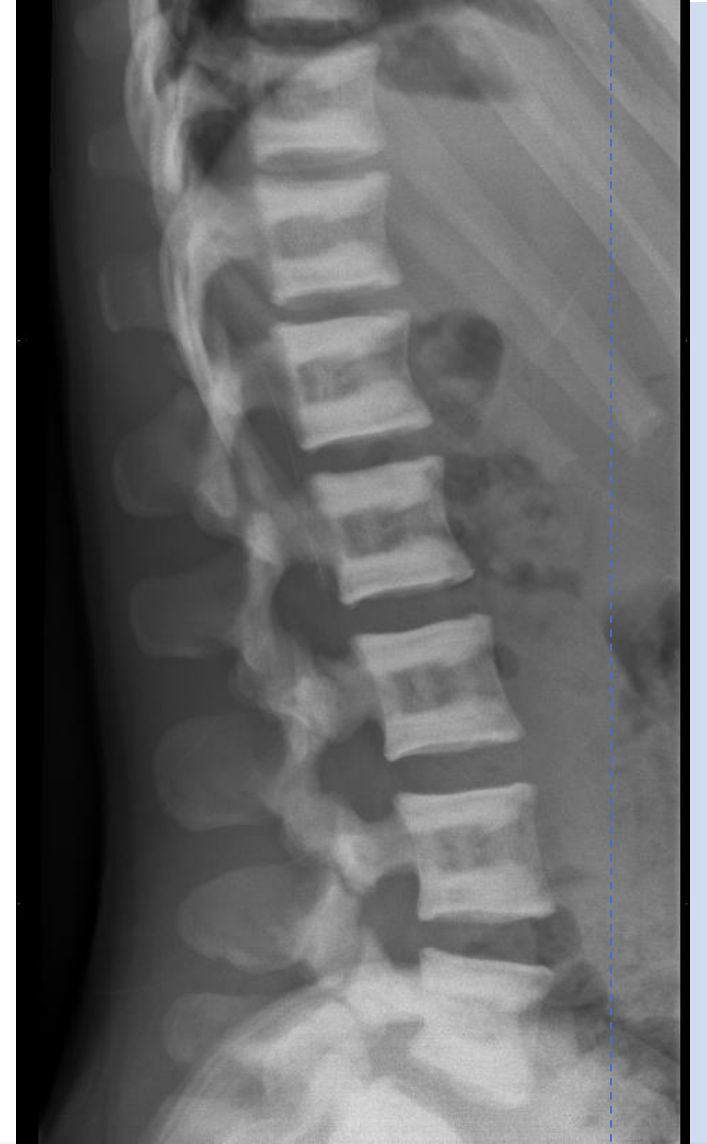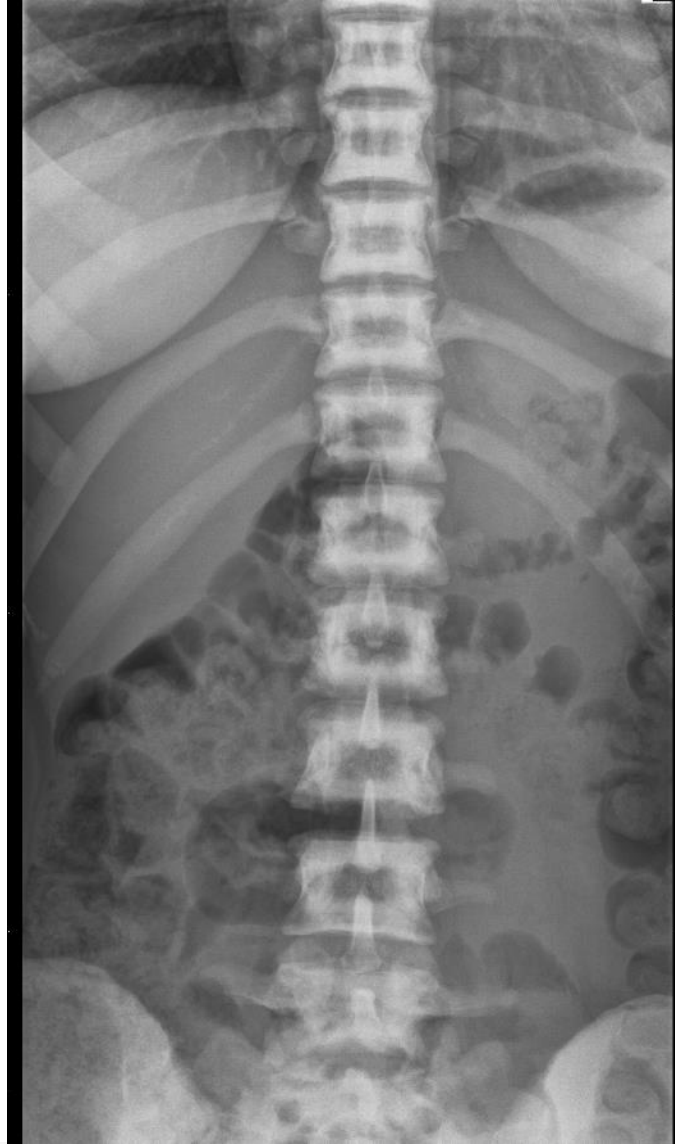
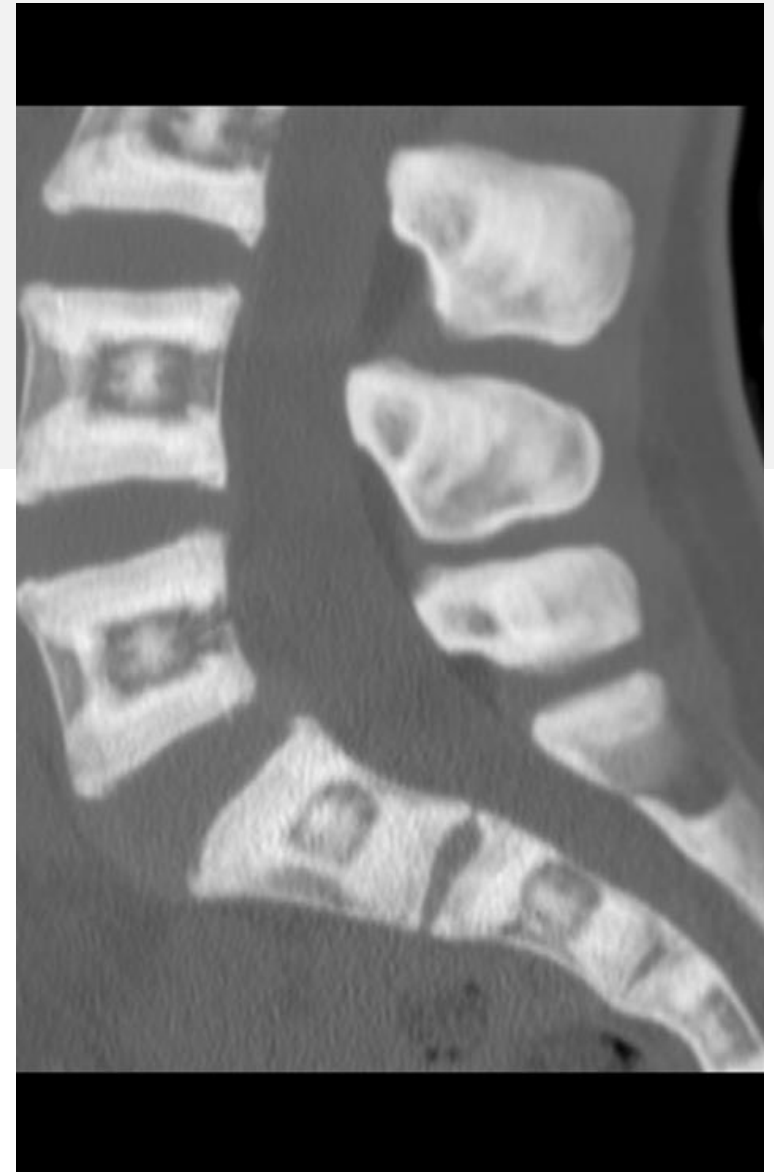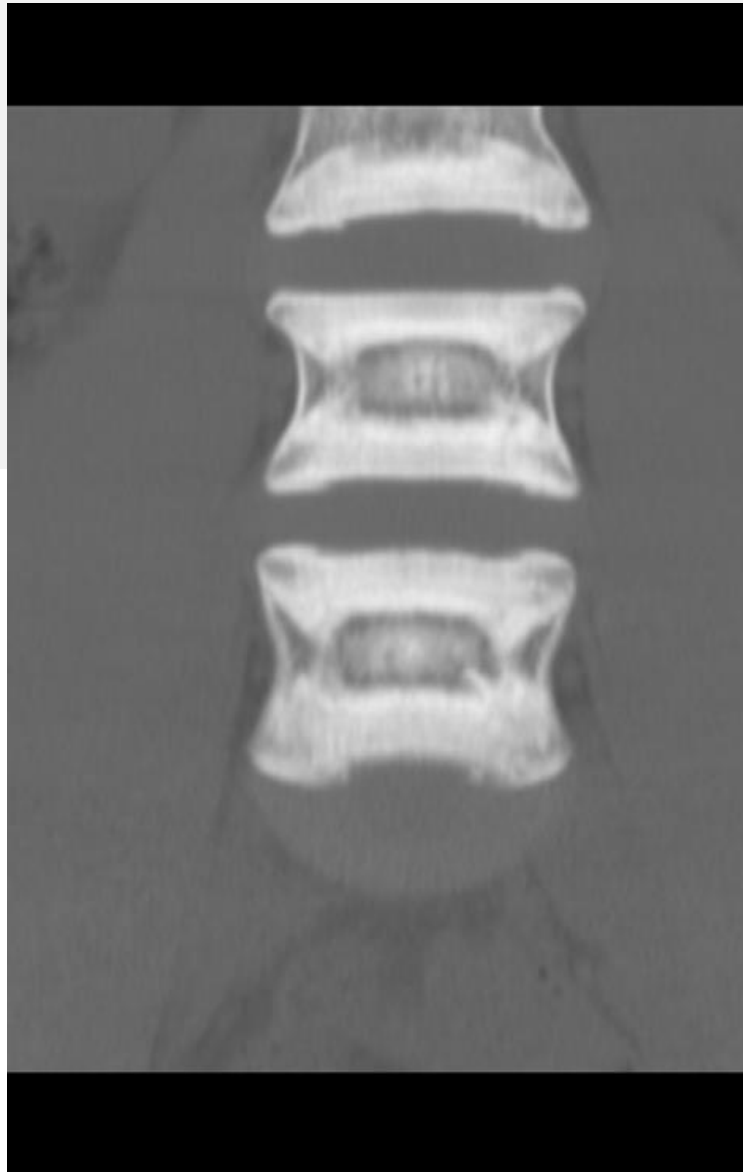
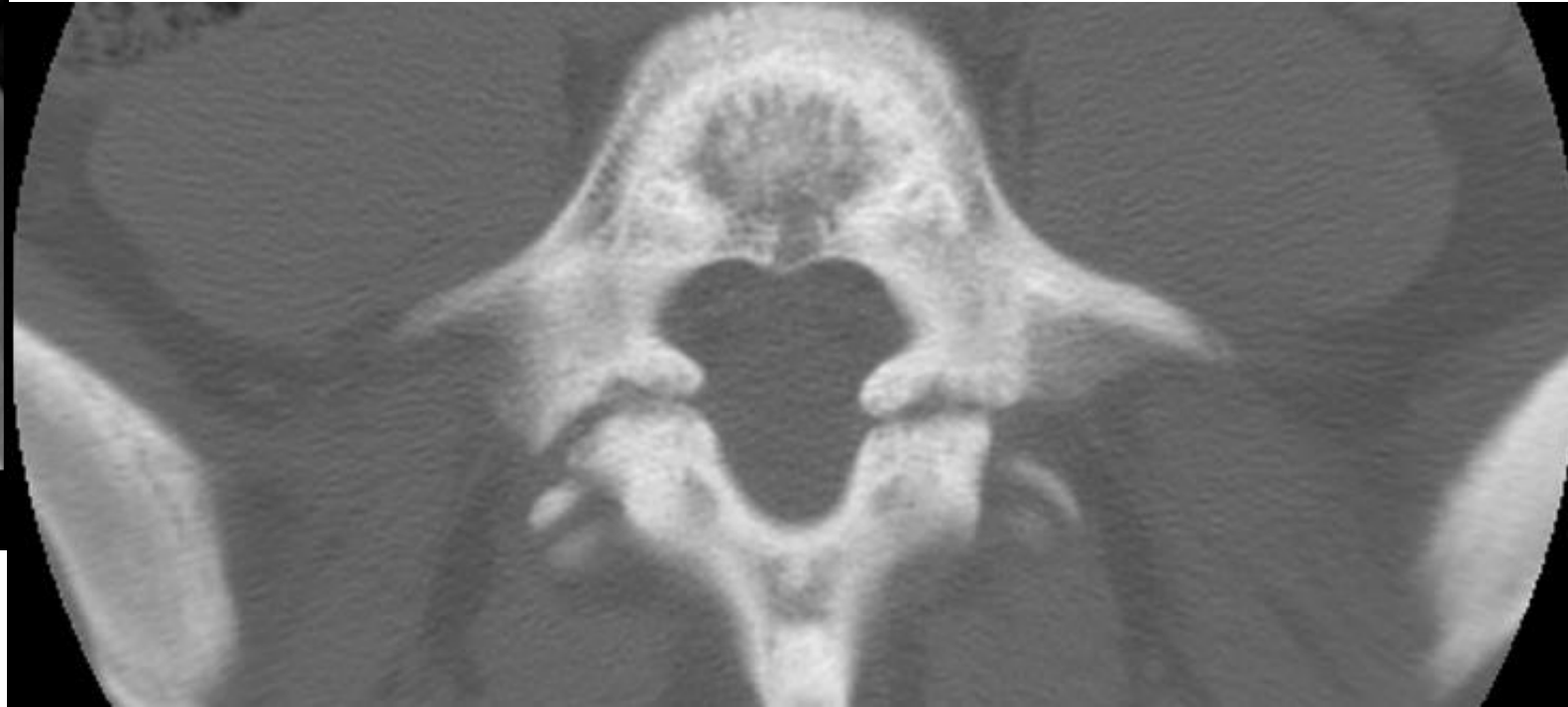
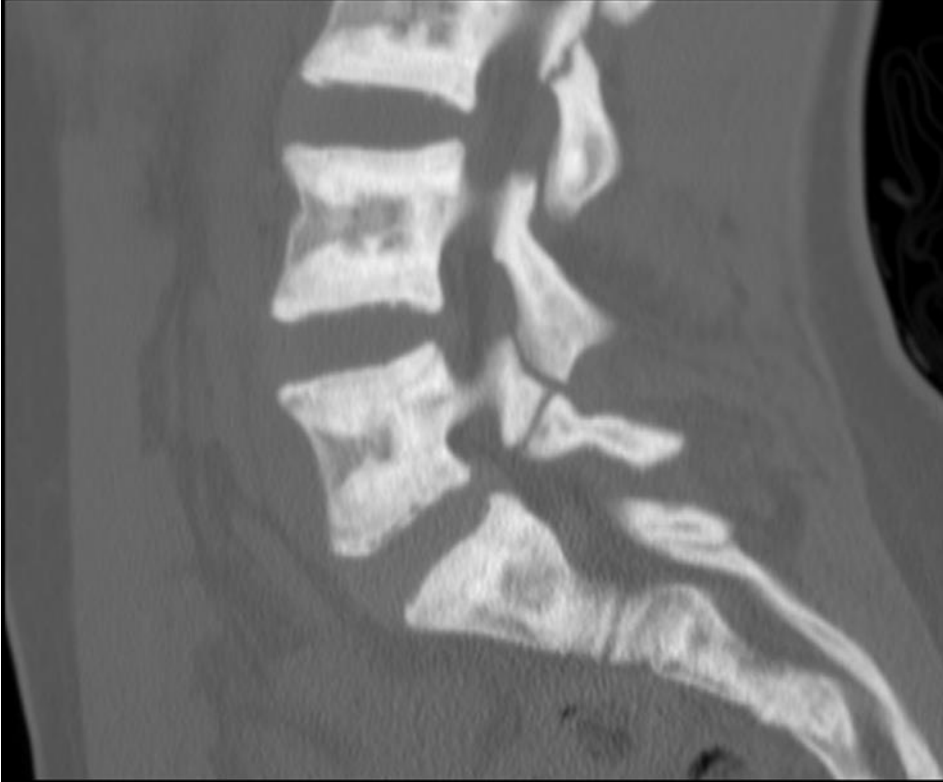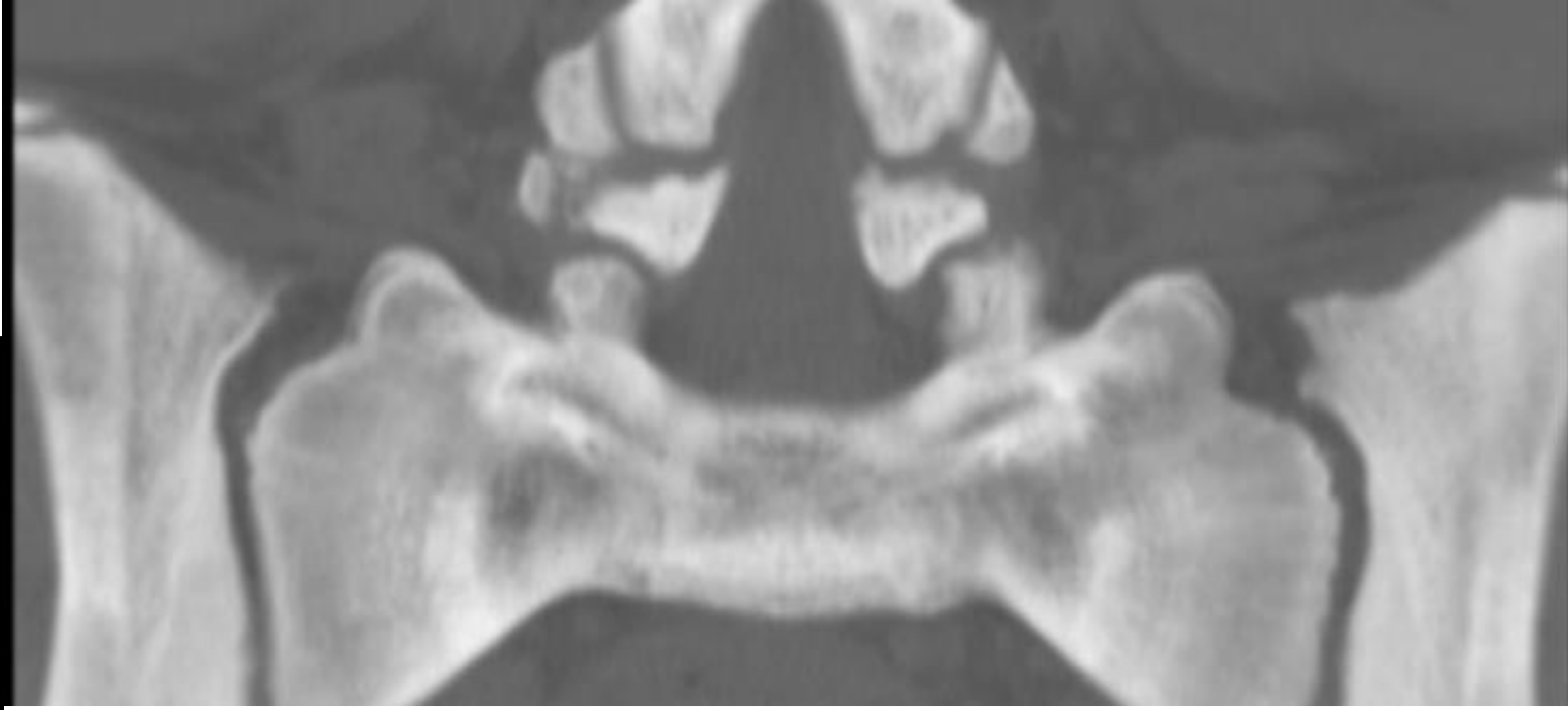
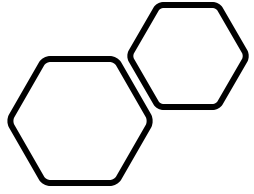


30F BACK PAIN







TYPE II AUTOSOMAL DOMINANT OSTEOPETROSIS

WITH MULTIPLE CHRONIC PARS FRACTURE NON-UNION

